

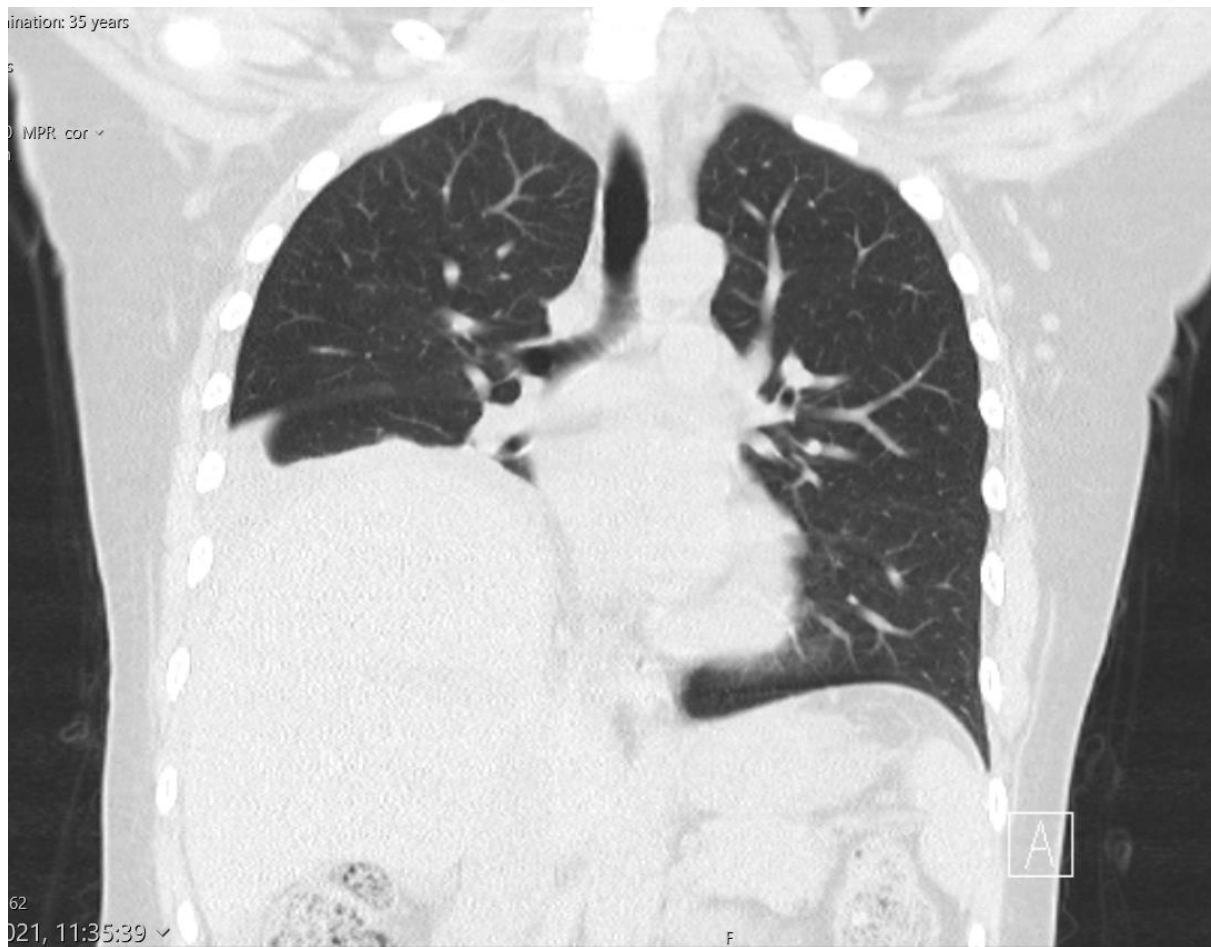Figure 1. HRCT thorax right pleural effusion and raised hemidiaphragm.

HRCT – High- Resolution Computed Tomography

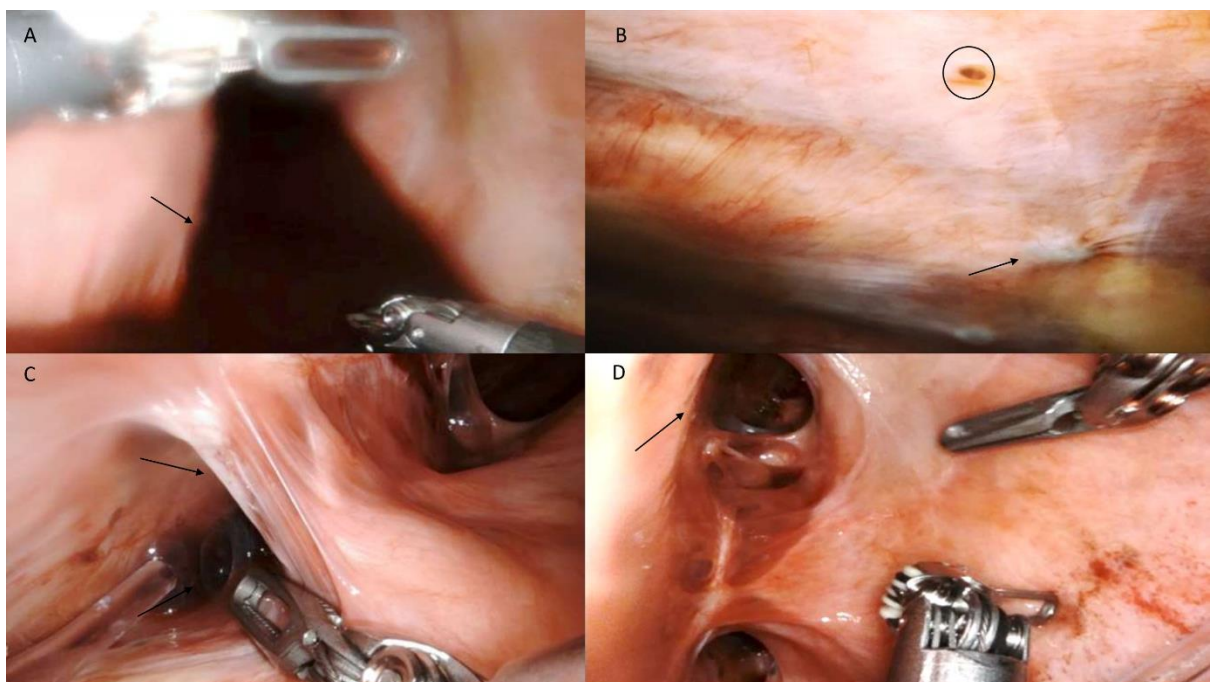


Figure 2. RATS showing haemorrhagic effusion [A], endometrial chocolate lesion over the pleural surface (circled), healed lesion (arrow) [B], adhesions (arrow) between the right lung and the diaphragm [C], diaphragmatic fenestrations (arrow) [D]

RATS – Robotic Assisted Thoracic Surgery.

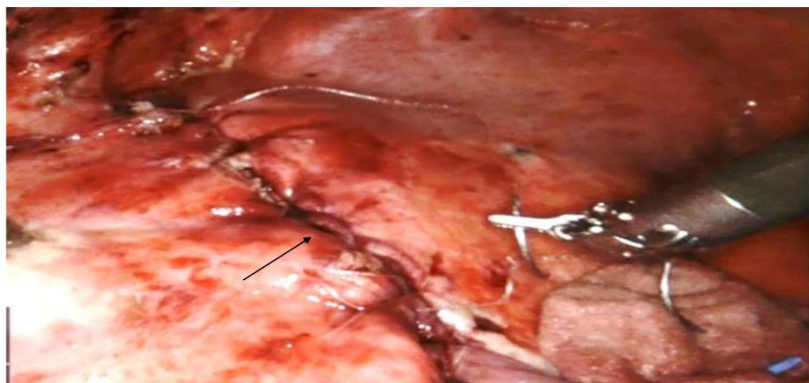


Figure 3. Diaphragm plication