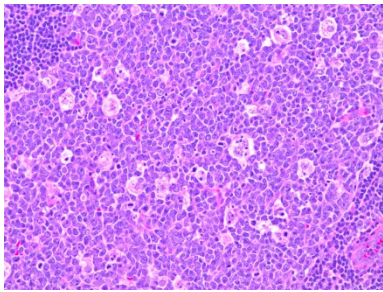
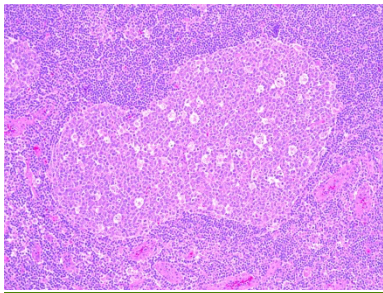
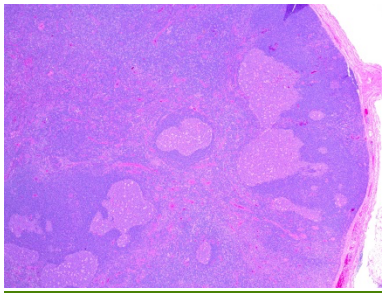
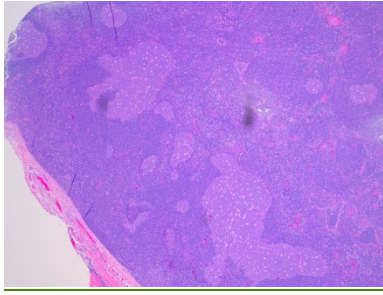


Image 1, 2, 3, 4,



Marked follicular hyperplasia with reactive background and foci of follicular lysis. A progressively transformed germinal center is present. Reactive germinal centers with numerous tingible-body macrophages.

