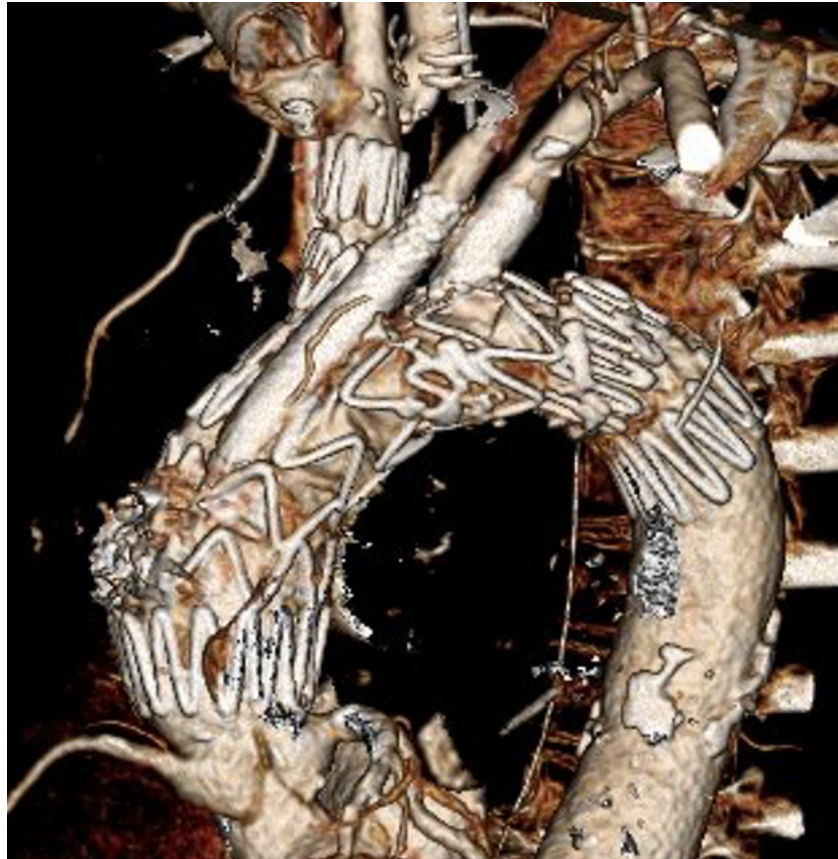


1

2 **Figure 4.** CTA after total endovascular aortic arch repair for acute type A aortic dissection

3



4