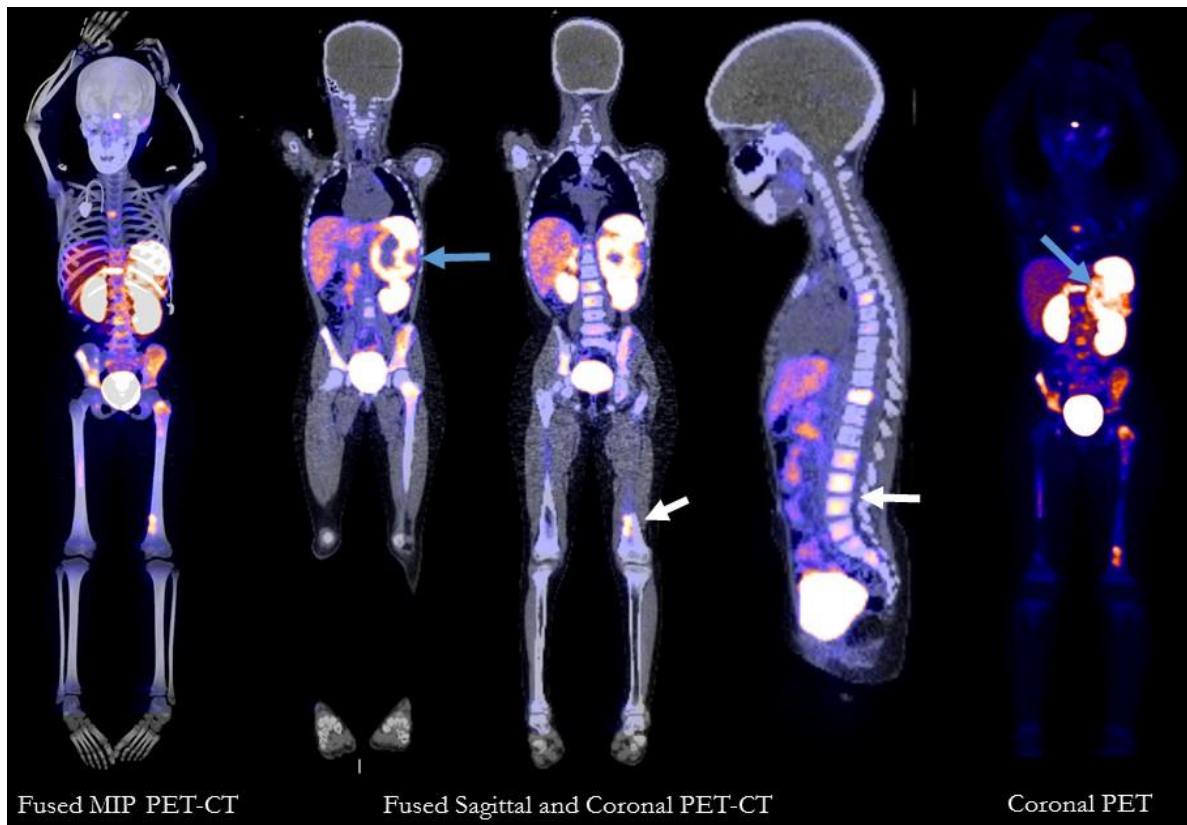


Figure 2. Selected representative images of  $^{68}\text{Ga}$ -DOTATATE PET/CT for Patient 2



Uptake in the left suprarenal mass with areas of necrosis (blue arrow) and evidence of skeletal metastasis (white arrows) and bone marrow infiltration.