

NSAIDs/Nitazoxanide/Azithromycin Immunomodulatory Protocol Used in Adults, Geriatric, Pediatric, Pregnant, and Immunocompromised COVID-19 Patients: A Prospective Observational Study and Case-Series.

Mina T. Kelleni, MD, PhD

Pharmacology Department, College of Medicine, Minia University, Egypt.

Mobile: +201200382422

drthabetpharm@yahoo.com, mina.kelleni@mu.edu.eg

<https://orcid.org/0000-0001-6290-6025>

Important note and I have all the supporting documents.

A preliminary version of this manuscript was once properly peer reviewed and accepted by InflammoPharmacology journal in November 2020. However, in the publication stage, some have intervened as I have chosen to print the photos in black (I had no funding), I have exaggerated in praising the editor in chief as I have thought and still think he is a very noble professor that was courageous to send a paper for peer review thought the author suggests in the title that this protocol is a potential COVID-19 magic bullet and finally I have changed many sentences in the proof stage as I believe I had so many ideas that were still being conceived and eventually I have received a decision to withdraw from publication and I accepted it without any anger due to my respect to its editor in chief, however I have no respect to those who I believe intimidated him and he would probably deny this intimidation and I won't judge him, I only pity the lives that are being lost as since then no other brave editor in chief has accepted to send it for a proper peer review, yet.

Highlights

Until now, no curative protocol to safely manage COVID-19 is available.

NSAIDs/Nitazoxanide/Azithromycin were repurposed to safely cure COVID-19.

NSAIDs/Nitazoxanide/Azithromycin might cure COVID-19 via immunomodulatory effects.

A Safe, inexpensive, and easy protocol has been developed to potentially cure COVID-19 patients.

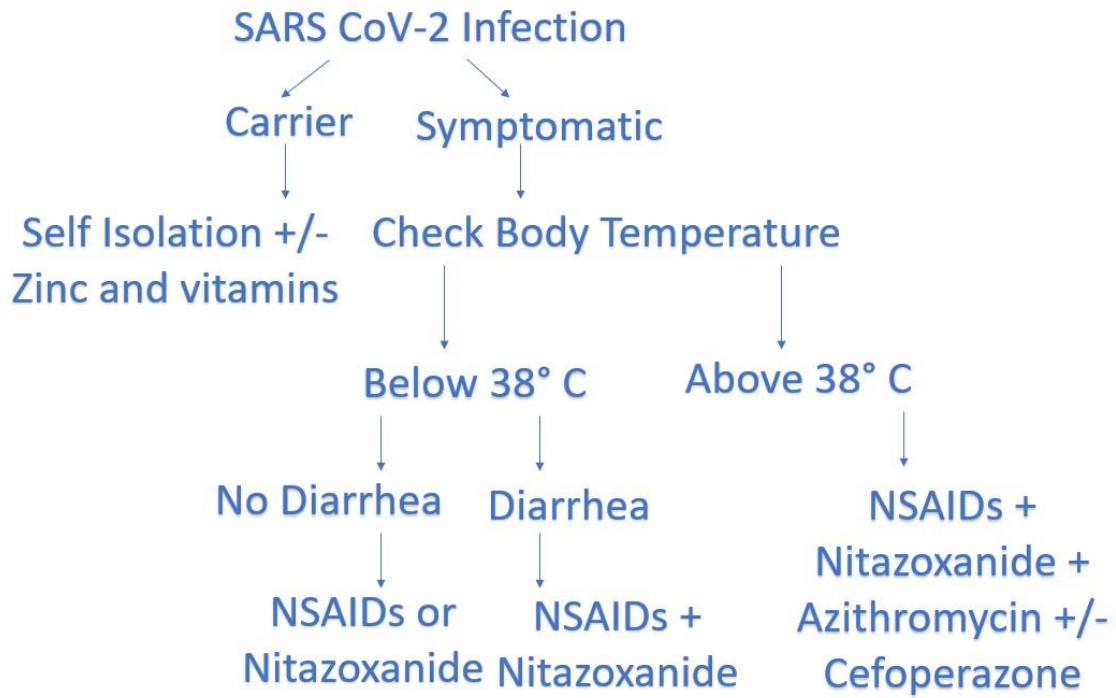
Sufficiently powered double randomized clinical trials should start soonest.

Abstract

To date no treatment protocol of proven efficacy was approved to manage COVID-19. We have developed a novel COVID-19 immunomodulatory protocol basing on our early pioneering article that justified repurposing of nitazoxanide/azithromycin combination for early cases of COVID-19 which was followed by two articles to justify addition of non-steroidal anti-inflammatory drugs to nitazoxanide/azithromycin. We are presenting a prospective telemedicine protocol that managed more than 50 documented COVID-19 patients while fully presenting a case series of 36 patients/legal guardians COVID-19 Arab patients including 12 confirmed by PCR and 23 diagnosed by other measures. The patients included 14 adult males including an immunocompromised patient, 15 adult females including one lactating, 3 pregnant patients including one confirmed by PCR as well as 4 children. All patients have received a short 5-day-regimen of NSAIDs (diclofenac potassium in most of cases, ibuprofen, lornoxicam, meloxicam, celecoxib, naproxen, ketoprofen or ketorolac)/nitazoxanide/azithromycin +/- cefoperazone either in full or in part as illustrated in the manuscript. The primary endpoint of this protocol was full relief of all serious COVID-19 clinical manifestations and it was fully achieved in all patients within two weeks. Most of the patients treated early have fully recovered during its described five days; the leucocytic/lymphocytic count was significantly improved for those with prior leucopenia/lymphopenia. No significant adverse effects were reported. A novel 5-day-protocol to safely and effectively cure COVID-19 using repurposed immunomodulatory safe and inexpensive FDA approved drugs is illustrated and we recommend performing sufficiently powered double blind randomized clinical trials against any current standard protocol.

Keywords: COVID-19; Diclofenac potassium; Ibuprofen; Nitazoxanide; Azithromycin; Telemedicine.

Abstract diagram



A novel protocol to manage SARS CoV-2 positive cases.

1. Introduction

Corona virus disease 2019 (COVID-19) is considered one of the worst pandemics in modern history with regard to its rapid rate of spread which has globally infected almost 153 million individuals and succumbed more than three million and three hundred thousand lives as of the 14th of May 2021 [<https://www.worldometers.info/coronavirus/>]. Keeping in mind that a vaccine might not be the ultimate safe, rapid, fair or durable solution to compete with the huge global morbidity and mortality caused by the highly evolving severe acute respiratory syndrome coronavirus 2 (SARS CoV-2) [1-3], we have searched for effective drugs that might provide a cure and on April 2020, a pioneering manuscript was published providing the scientific pathophysiological and pharmacological concept to repurpose the inexpensive, and relatively safe novel combination; nitazoxanide/azithromycin for early management of COVID-19 attributing their potential efficacy to restoration and/or augmentation of the body's interferon homeostasis, at a time when only eight clinical trials, with recruitment difficulties, for nitazoxanide potential in COVID-19 were registered in developing countries[4] and on May 2020, a preprint was released [5] to suggest adding non-steroidal anti-inflammatory drugs (NSAIDs) such as ibuprofen for early management of COVID-19. Importantly in this preprint, has been later been updated, reviewed and published at a reputable journal[6], that relied on our early academic and clinical experience and later on other potential molecular protective mechanisms and also discussed, while claiming NSAIDs superiority, the related advertised breakthroughs of low dose aspirin and colchicine [7]. We have suggested that NSAIDs will be of COVID-19 value not only as safe and more effective analgesic antipyretic but also, due to their potent anti-inflammatory and immunomodulatory effects, might reverse the pathogenesis of COVID-19, mitigate or prevent its complications including the cytokine storm and improve the clinical outcomes especially if used as early as possible during the course of COVID-19.

2. Patients and Methods

This manuscript represents a 36 telemedicine case series (35 Egyptian patients living in Egypt or KSA and one citizen of Jordan) as part of our prospective observational study that reflected our academic and real-life experience with our immunomodulatory COVID-19

management protocol. More than 50 telemedicine cases were documented yet we opted not to repeat many of the non-PCR documented cases as we have not presented cases that were managed through the traditional examination method. As early of late April/early May 2020, we have been receiving telemedicine requests and consents to manage COVID-19 patients who could not appear for the ordinary face to face, currently mask to mask, physical examination because of conditions which prevented both domestic and international travel and the reasons also included other economic and COVID-19 related restrictions. The represented case-series included 14 adult males including one on azathioprine, 15 adult females including one lactating, 3 pregnant patients as well as 4 children. We have adopted a recommendation for de-identification as regards to their age and occupation and hence we have deleted their specific age and their professions as many were health care professionals. Some patients had moderate to severe COVID-19 manifestations, and many had several co-morbidities including obesity and diabetes mellitus. Twelve patients were confirmed by PCR including a pregnant patient, four patients have performed CT and/or showed positive SARS CoV-2 IgM to augment the clinical and serological COVID-19 suggestive manifestations while the other cases, including two other pregnant patients as well as four children, have presented a combination of some or all of the following: history of close contact to first degree relatives/ close associates COVID-19 confirmed by PCR quarantined/isolated patients; clinical manifestations suggestive of COVID-19 e.g. fever, cough, dyspnea, anosmia and ageusia. CBC of several patients showed leucopenia or lymphocytopenia while CT, SARS CoV-2 Ig M test or PCR test were neither medically justified, readily available nor economically feasible for many of our patients and we never asked for CT or PCR to help our diagnosis, yet we have early advised to test for SARS CoV-2 Ig M in few cases and later we have avoided it as well.

Notably, we have responded immediately to the received requests from the mentioned patients and we used a personalized documented telemedicine approach, using audiovisual social media applications while consultations were being conducted, to be noted that proper adapted telemedicine is being rapidly evolving during this COVID-19 pandemic era [8]. Importantly, the clinical picture of COVID-19 was sometimes unusual and this was of clinical importance to suspect early, ask for investigations and manage on an individualized

basis and we agree to name the plethora of COVID-19 presentations of as COVID-19 spectrum to include the following: bizarre oral ulcers, oral lichen planus, concomitant herpetic labialis, unusual menstrual irregularities, unusual allergic dermatitis or skin rash and suspected COVID-19 associated vasculitis. Furthermore, most of our patients who have performed CBC showed lymphopenias while some have showed normal or marginally normal complete blood count but showed history and clinical manifestations highly suggestive of COVID-19. Importantly, no restrictions to manage COVID-19 patients were present but we, regrettably yet professionally, refused to manage some severe cases because those who contacted us had no direct contact with the patients and thus no close follow up was guaranteed. We have insisted to contact only the case/legal guardian and only in one case we accepted the consent coming from the husband and sons of a deteriorating patient who could not initially provide a consent.

We have used the described protocol using NSAIDs, nitazoxanide, azithromycin +/- cefoperazone either fully or partly and for adults.

We used NSAIDs, either postprandial diclofenac potassium 50 mg, ibuprofen (mostly 400 mg), lornoxicam 8 mg or celecoxib 100 or 200 mg b.i.d. alone for early cases complaining of sore throat, dry cough or mild dyspnea with no fever or fever less than 38°C and we suggest they have helped to prevent the progression of COVID-19 especially for those who received them earlier.

We used nitazoxanide with or without NSAIDs for those patients complaining of mild sore throat, diarrhea without fever or fever less than 38°C and as a rule it was always given whenever diarrhea was reported. Notably, we have used nitazoxanide alone, when available as it is not in some countries including KSA in which six of the described patients have received our protocol including five of the twelve who were confirmed by PCR, to manage selected mild cases of highly suspected COVID-19 patients who complained of GIT manifestations but did not complain of fever, with remarkable results and we preferred to use NSAIDs alone to manage selected of highly suspected COVID-19 patients who mainly suffered from respiratory tract manifestations without fever.

We prescribed the whole NSAIDs (as described)/nitazoxanide (500 mg bid)/azithromycin (500 mg once daily) five days protocol for COVID-19 adult patients complaining of fever more than 38°C.

The primary endpoint of our management was full relief of COVID-19 induced hazardous, i.e., other than anosmia and/or ageusia, symptoms and signs e.g., fever, progressive cough, moderate/severe dyspnea and/or disturbed level of consciousness.

Importantly, we preferred to administer diclofenac twice daily aiming at improving the natural immune response if the patients recorded temperature less than 38°C in between the two doses but they were allowed to take them t.d.s if the temperature exceeded 38°C before the next dose.

For the reported children we prescribed the pediatric weight/age adjusted doses of nitazoxanide suspension, azithromycin suspension and ibuprofen syrup according to the same conditions described for adults and we have fully described our approach to manage pregnant COVID-19 patients while discussing three cases. However, we in mild suspected COVID-19 in pediatric patients we have prescribed a 3-day-course of azithromycin and/or nitazoxanide.

3. Results

3.1. Managing PCR confirmed adult COVID-19 patients and their close contacts.

Case 1

Male patient in his early 20s, has suffered from fever up to 38.8°C on paracetamol, rhinorrhea, cough, headache, diarrhea bone ache, anosmia and ageusia. His complete blood count (CBC) revealed a total white blood cell count of $7.8 \times 10^3/\mu\text{l}$, absolute lymphopenia with a relative lymphocyte count 5.5%, mixed population of monocytes, basophils and eosinophils count 16.5% and neutrophils count 78% (Figure 1). The swab revealed SARS CoV-2 positive by PCR and upon consultation he started to take the ibuprofen/nitazoxanide/azithromycin protocol on the following day and after the 5 day treatment regimen, the total white blood cell count was $6.3 \times 10^3/\mu\text{l}$, lymphocyte count

43%, mixed population of monocytes, basophiles and eosinophils count 8% and neutrophils 49% (Figure 2).

Case 2

Male patient in mid 50s has suffered from mild cough, fatigue and some colleagues have prescribed him azithromycin course, one injection of betamethasone and an antitussive/expectorant containing oxomemazine, guaifenesin, sodium benzoate and paracetamol. His condition has deteriorated showing fever up to 39°C, marked cough and severe malaise and another colleague has prescribed parenteral ceftriaxone 1 gm once daily and paracetamol 1000 mg every 6 hours and antitussives for five days with partial improvement, thus he was advised to be tested for COVID-19 and the his PCR test showed positive then a colleague advised to increase the dose of ceftriaxone to be administered every 12 hours and to add levofloxacin 500 mg once daily to be added to the previously described antitussive but he decided to consult us. We started our 5-day-regimen with parenteral cefoperazone 1 gm once daily, azithromycin 500 mg once daily for five days and we replaced paracetamol with lornoxicam 8 mg once daily with follow up of the temperature. Furthermore, we stopped the administered antitussive/expectorant and replaced it with an antitussive supplement that contains aqueous guava leaves extract and powdered tilia flowers extract to be taken only if severe episodes are encountered until his cough improved and he reported marked improvement in his condition to be noted that a CBC performed 4 days before he started our regimen has showed a normal leucocytic count with reduced relative lymphocytic count of 16.5% (Figure 3) and another one preformed 4 days after finishing our regimen revealed a normal relative lymphocytic count of 36.2% (Figure 4).

Case 3 and 4

Male patient in his early 30s who has been diagnosed by PCR after suffering from mild fever 37.8°C, moderate malaise and anosmia has contacted us after finishing a 5-day azithromycin course complaining from newly encountered ageusia, cough, diarrhea and malaise without fever; we have successfully prescribed nitazoxanide and diclofenac potassium to manage his condition. Interestingly, this patient has also consulted us as his grandmother who is in her early 70s and known to be also as a controlled hypertensive

patient, on lisinopril, suffered from cough, abdominal colic, and malaise. A tropical medicine consultant has asked for CT chest that revealed ground glass opacities suggestive of COVID-19; CBC that showed a total white blood cell count $3.3 \times 10^3/\mu\text{l}$, relative lymphocyte count 13%. The consulted colleague prescribed parenteral ceftriaxone, enoxaparin, paracetamol, zinc, and vitamin C with little improvement in the clinical picture. We, consulted on the fifth day after she finished the antibiotic course, immediately stopped enoxaparin, paracetamol and allowed the continuation zinc and vitamin C. Most importantly, we prescribed a 5-day diclofenac potassium and nitazoxanide course that was reported to dramatically improve her condition and a subsequent CBC showed a total white blood cell count; $5.5 \times 10^3/\mu\text{l}$, relative lymphocyte count; 40%.

Case 5

A female, citizen of Jordan, in early 30s has suffered from fever up to 38°C on paracetamol, headache, severe bone ache and dizziness. A PCR test revealed positive, and she was advised for self-isolation and she was self-administered zinc and vitamin C. Upon consultation, we replaced paracetamol with naproxen 500 mg which was readily available with her once daily for five days and recommended azithromycin 500 mg once daily. Dramatic improvement was noticed since the first day and complete recovery was reported within five days.

Case 6

A hypertensive and type 2 diabetic male patient with SARS CoV-2 PCR positive test results of a combined nasopharyngeal and oropharyngeal swab who complained of troublesome fortnight dyspnea and dry cough that has not been resolved by the described amoxicillin/clavulanate potassium/paracetamol regimen has used, upon advice, diclofenac potassium 50 mg, postprandial b.i.d to replace paracetamol and we decided not to administer any further antibiotics as no fever was reported at the time of consultation. Interestingly, he reported a significant improvement of his clinical manifestations from the first day diclofenac potassium was administered, and he became mostly symptom-free in three days. The patient continued the 5-day-regimen and later he was discharged of a quarantine facility. Notably, he was advised, similar to our other COVID-19 patients, not to take antitussives for his mild to moderate cough episodes, and to use warm beverages

e.g. boiled mint to soothe their sore throat and this approach has proved beneficial in all presented cases. This recommendation was basing on a clinical sense that trusted the body natural reflexes and was not basing on a piece of evidence-based study which is, to the best of our knowledge, currently lacking and might not be promptly available.

Case 7

We also prescribed diclofenac potassium/azithromycin to safely manage a male patient, in his late 50s, who complained of 39°C fever associated with his SARS CoV-2 infection. He received the treatment early and his condition was fully controlled within the five-day-regimen and only zinc and vitamins were permitted to be concomitantly administered as he has already purchased them. Similarly, another COVID-19 patient consulted us complaining of a persistent 20 days mild to moderate cough, fluctuating fever, and positive PCR tests while in isolation, we advised him to stop the previously prescribed antitussive dextromethorphan and we prescribed diclofenac potassium/azithromycin. He reported that his persistent diarrhea started to improve immediately after ceasing to use dextromethorphan, even before managing to obtain the other newly prescribed drugs. Furthermore, he has also used ibuprofen 600 mg tablets that were available with him and reported a better clinical experience than diclofenac potassium regarding headache, fatigue, and pain control and later he was discharged.

Case 8

A COVID-19 male patient, also confirmed by PCR, suffered from fluctuating fever up to 39°C with marked dry cough to which he was prescribed azithromycin 500 mg daily for three days and paracetamol. We, contacted on the third day, instructed him to continue azithromycin for two more days and to replace paracetamol with diclofenac potassium t.d.s. for two days and b.i.d. for three days and he felt marked improvement in his clinical condition with normal temperature and gradual significant improvement of cough during the five days course.

Case 9 and 10

Moreover, a young couple consulted us; the husband complained of fever, which was not relieved by paracetamol, dry cough, fatigue, sweating, malaise and dysgeusia. He was

confirmed by PCR as a COVID-19 patient and was isolated at home. We have been contacted early and he received diclofenac potassium/azithromycin to manage his condition and he also received zinc supplements. He reported marked improvement on the fifth day, yet profuse sweating and mild fatigue persisted for five other days. Interestingly, his spouse developed COVID-19 suggestive manifestations e.g., fever, cough, malaise, severe sore throat, anosmia and ageusia only after an early PCR test revealed negative results and she couldn't repeat it. She received the same treatment as her husband with similar marked improvement within five days.

Case 11 and 12

Male patient in his early 50s has suffered from mild-moderate cough, temperature of 37.5°C, mild diarrhea, diaphoresis, and he was administered azithromycin, oral acetyl cysteine, cloperastine, zinc, and vitamin C. He experienced partial improvement and his PCR test showed positive on the third day when he decided to consult us. We advised to continue azithromycin to complete five days, administered nitazoxanide bid for five days and stopped acetyl cysteine and cloperastine and asked for laboratory investigations which showed leucopenia; $3.5 \times 10^3/\mu\text{l}$ and reduced absolute lymphocytic count; $0.97 \times 10^3/\mu\text{l}$ while his relative lymphocytic count was 27.5% (Figure 5) and C reactive protein (CRP) titer was normal. However, his D-dimer was mildly elevated; 0.67 mg/l and we advised meloxicam 7.5 mg once daily for five day which started on the third day of nitazoxanide course. Marked improvement was reported during the first five-day regimen and a CBC performed in the fifth day showed a normal leucocytic count; $6 \times 10^3/\mu\text{l}$, normal absolute lymphocytic count; $2.1 \times 10^3/\mu\text{l}$ while his relative lymphocytic count was 35.8% (Figure 6) and a normal D-dimer level; 0.12 mg/l. Interestingly, the same patient has consulted us after his mother who is in early 80s and was a close contact to him suffered from dry cough, sore throat, headache and fatigue and he reported that she used azithromycin and paracetamol for two days with no improvement. We have instructed to continue a 5-day-course of azithromycin and replaced paracetamol with meloxicam 7.5 mg once daily for five days and marked improvement was reported within the five-day regimen except for mild fatigue and anorexia that were fully resolved within one week after treatment.

Case 13 and 14

An obese controlled hypertensive, olmesartan/amlodipine/hydrochlorothiazide for five years, couple in their late 50s, have contacted us. The husband complained of fever up to 38.8°C, headache, sore throat, dry cough, and severe malaise. Similar manifestations were encountered by his wife without fever, CT was suggestive of COVID-19 and they were confirmed by PCR. As we have been contacted on the same day of PCR confirmation, thus an early management was granted. Both received diclofenac potassium b.i.d., azithromycin and nitazoxanide as described for five days. The fever has subsided to normal temperature from the first day and on the fifth day; they have reported almost complete resolution of symptoms except for mild cough and two days later they have reported almost full relief of symptoms. Notably, they have also reported that they initially preferred to inhale, once or twice daily for two days, boiled cloves' water vapor to relieve their cough, and when it was not bothersome, they stopped the steam inhalation sessions. Interestingly, a preliminary observation that arose from a small study suggested that cycles of steam inhalation at temperature 55–65 °C might be beneficial in halting SARS-CoV-2 virus infection during its initial stage and possibly preventing further spread[9] and we also suggest that their recommendation is totally harmless and might be at least as beneficial as that of zinc and vitamins supplements.

Case 15

A pregnant patient confirmed by PCR and discussed later.

3.2. Managing non-PCR confirmed COVID-19 adult patients including one immunocompromised and one lactating patients

Case 16

A male patient in his late 30s who is on prolonged maintenance dose of azathioprine to control his autoimmune CNS vasculitis vs multiple sclerosis unsettled diagnosis, has been a close contact to a SARS CoV-2 positive patient who has been diagnosed by PCR after complaining of mild cough, moderate fatigue and dizziness with a CBC showing mild leucopenia; $3.8 \times 10^3/\mu\text{l}$ and though her relative lymphocytic count was apparently normal; 30% her absolute count was mildly reduced; $1.14 \times 10^3/\mu\text{l}$ (normal range $1.5 - 4 \times 10^3/\mu\text{l}$),

her D-dimer level was normal and CRP titer was mildly positive; 12 mg/l before the PCR shown a positive result and our patient complained of moderate fatigue, fever of 37.8°C, mild cough and rhinorrhea. His CBC showed apparently normal leucocytic count of $5.32 \times 10^3/\mu\text{l}$ (normal range $5-11 \times 10^3/\mu\text{l}$), yet reduced relative and absolute lymphocytic count; 18.2% and $0.97 \times 10^3/\mu\text{l}$ respectively and he was self-prescribed with azithromycin, zinc, vitamin C and paracetamol; two days later he repeated the CBC to reveal leucopenia; $3.8 \times 10^3/\mu\text{l}$ with an increase in both the relative and absolute lymphocytic count; 40% and $1.5 \times 10^3/\mu\text{l}$ respectively and normal CRP and D-dimer levels yet after 7 days he still complained of dizziness, low grade fever, headache, fatigue and rhinorrhea and he consulted us. Since he has already finished a 5-day-regimen of azithromycin we only replaced paracetamol with lornoxicam for five days and the patient has reported marked and significant improvement in his clinical condition with relief of all symptoms and on the sixth day his CBC showed an improved normal leucocytic count; $4.1 \times 10^3/\mu\text{l}$ and his relative and absolute lymphocytic count; 40% and $1.6 \times 10^3/\mu\text{l}$.

Case 17

A female in mid 30s has suffered from productive cough and mild rhinorrhea and a colleague has asked for a CT that was suggestive of COVID-19 (Figure 7) and he prescribed IV ceftriaxone 1 gm, IV dexamethasone 8 mg to be followed by oral prednisone 5 mg bid, IV ketorolac once daily for five days. He also prescribed clarithromycin 500 mg once daily for one week, ivermectin, levocetirizine, vitamin C, zinc, acetylcysteine, erdosteine and rivaroxaban. She has received his treatment protocol for one week with deteriorating clinical condition as revealed by increased in severity of cough as well as progressive fatigue. Upon consultation on the eighth day and as she has not reported any fever before or during the treatment, we advised stoppage of all drugs and the severe cough episodes as well as her clinical condition have gradually improved over one week, and she only was advised to rest, healthy nutrition, warm beverages and inhalation of boiled cloves' water vapor twice daily and later a full smooth recovery was reported in another week.

Case 18

A female patient in mid 40s consulted us after her husband was isolated due to a highly suspected COVID-19. She reported fever up to 39.2°C, sore throat, severe headache, and

bone ache to which she was self-administered azithromycin, paracetamol, zinc, and vitamin C for one day with no improvement. When consulted, we asked for laboratory investigations that revealed leucopenia; $3.64 \times 10^3/\mu\text{l}$ and reduced relative and absolute lymphocytic counts; 15 % and $0.55 \times 10^3/\mu\text{l}$ respectively (Figure 8). We advised continued use of azithromycin for five days and replaced paracetamol with a parenteral ketorolac in the first day of a 5-day-course of meloxicam 7.5 mg once daily. Marked improvement was reported from the first day of our regimen and a follow up CBC performed on her convenience at the 12th day of our consultation showed a normal leucocytic count; $7.4 \times 10^3/\mu\text{l}$ and normal relative and absolute lymphocytic counts; 30%, $2.22 \times 10^3/\mu\text{l}$ respectively (Figure 9).

Case 19

A female patient in her late 40s complained of severe sore throat, malaise, fever and mild cough to which a family physician who is a tropical medicine consultant has asked for a CT chest that revealed patchy scattered ground glass opacities suggestive of COVID-19, as described in the given report, and he has prescribed paracetamol, betamethasone injection IM, doxycycline 100 mg for 15 days, azithromycin 500 mg orally, some vitamins and minerals as well as a syrup that contains antihistaminic and expectorant for three days. Her condition rapidly deteriorated with persistent fever, yellow vision, tachycardia and marked confusion. When we received a compassionate request from her husband and sons to help, we asked for an urgent CBC that revealed a total leucocytic count of $5.1 \times 10^3/\mu\text{l}$ with a low lymphocytic count of 12% (Figure 10). She was also diagnosed positive for SARS CoV-2 IgM test upon our request and we immediately stopped the bacteriostatic doxycycline, and ordered an immediate ketoprofen IM injection to be followed by diclofenac potassium b.i.d. and azithromycin 500 mg once daily for five days in combination with empiric parenteral cefoperazone; 1 gm once daily for the first three days chosen for its readily availability and its broad spectrum antibacterial efficacy against atypical respiratory micro-organisms that were suspected to share in causing the reported high fever and deteriorating condition as a super infection. Furthermore, we have added nitazoxanide 500 mg b.i.d. that also managed to control an episode of diarrhea that has been encountered after the start of treatment. We also stopped the previously prescribed

antitussive syrup as explained earlier. Her condition improved gradually yet dramatically within five days and the CBC on the fifth day revealed an improved total leucocytic count of $6 \times 10^3/\mu\text{l}$ with a significantly elevated lymphocytic count of 23% (Figure 11). She returned almost normal within two weeks complaining only of mild cough and insignificant chest tightness that have disappeared later spontaneously.

Case 20 and 21

A male patient in mid 50s suffering from type 2 diabetes, hypertension, and obesity (BMI 33.2), for which he was receiving glyburide/metformin, bisoprolol, olmesartan/hydrochlorothiazide, has suffered from cough, fever up to 39°C , dyspnea, and fatigue. His CT showed a highly suggestive features of COVID-19 (Figure 12) and his CRP was 76 mg/l with marginally normal relative lymphocytic count 24.6%. A colleague has prescribed him the mucolytics erdosteine and acetylcysteine, zinc, vitamin C, rivaroxaban 10 mg, prednisolone 20 mg, IV ceftriaxone 1 gm, IV dexamethasone 8 mg, IV diclofenac sodium, and IV famotidine for eight days on which the colleague has advised to give the IV medications twice. This colleague has also prescribed ipratropium bromide inhalation sessions, yet they have been soon stopped when his oxygen saturation was reported to deteriorate. His clinical condition was deteriorating as well as his oxygen saturation measured by pulse oximeter that reached 80% without oxygen inhalation that is elevated to 92% with oxygen, severe cough episodes, dyspnea, increased fatigue, insomnia, fluctuating fever up to 38°C , elevated blood glucose profile and hypertensive episodes. Upon consultation on the ninth day, we continued the antihypertensive and anti-diabetic drugs but have immediately stopped prednisolone and stopped all the parenteral medications including dexamethasone. We have also stopped the mucolytics in a trial to ameliorate the severe cough episodes and replaced zinc, vitamin C, lactoferrin with ergocalciferol once daily and we first tried an antitussive supplement that contains aqueous guava leaves extract and powdered tilia flowers extract yet soon we shifted to the more potent cloperastine. Though the patient was not suffering from fever, yet due to the reports of fluctuating fever, we have prescribed a daily dose of azithromycin for five days and more importantly we have added nitazoxanide 500 mg bid and an intentionally low dosed celecoxib 100 mg once daily and advised a low potassium diet for five days and continued

oxygen inhalation as needed. We advised to use add insulin glargine to control the persistently elevated blood glucose level, yet it was not readily available and by the time it was delivered, the patient improved. The patient has been gradually improving in five days in which the cough has decreased, and he has become finally able to sleep supine and oxygen saturation without oxygen supplementation 95% and his blood pressure and blood glucose profile have returned to normal pre-infection levels. Notably, a cutaneous rash has appeared on the neck (Figure 13) and back (Figure 14) on the fourth day and we considered it a good sign. However, he reported dysphagia and we doubted fungal infection and he was totally improved on nystatin oral gel t.d.s. for three days. Moreover, a dysphonia was reported, and we doubted fungal laryngitis and prescribed fluconazole 150 mg once daily for ten days during which the patient reported gradual significant improvement. Interestingly, CRP on the sixth day has decreased to 12 mg/l and his lymphocytic count was elevated to 41%. However, his D-dimer level has revealed an elevated level of 1 µg/ml and we prescribed low dose 100 mg aspirin once daily for one week and it did not change thus, we advised another week of apixaban 2.5 mg b.i.d. without adverse effects but we reevaluated the risk benefit ratio especially when we read that D-dimer levels might only have a low association with venous thromboembolism in other inflammatory diseases[10] and we later we avoided prescription of apixaban to ambulatory patients with mild elevation of D-dimers. Notably, we allowed a recovery without any drugs starting from the sixth day for the remaining mild cough episodes and advised inhalation of boiled cloves' water vapor and the patient has reported a very smooth recovery. Notably, his daughter, in mid 20s, who oversaw all his medical and non-medical care has concomitantly suffered from fever up to 38°C, colic, anorexia and fatigue. Her CRP was 12 mg/l, D-dimer was mildly elevated 0.52 mg/l and she reported ingestion of one tablet of ampicillin 500mg/flucloxacillin 250 mg and thus we have advised to complete this course t.d.s for three days in addition to once daily azithromycin for five days and we added diclofenac potassium 50 mg bid and metronidazole 500 mg bid for three days to decrease incidence of antibiotic associated colitis. She reported significant recovery starting from the second day with no recurrence in fever and significant improvement of the other manifestations. Only a mild and self-limited diarrhea was reported in the second day of the five-day-regimen and she reported full recovery of all the original manifestations.

Case 22

Interestingly, a female patient in early 30s who is lactating a 6-month-old infant has suffered from fever, headache, bone ache and mild cough. Her CBC showed normal CRP titer, leucopenia; $2.42 \times 10^3/\mu\text{l}$ with an elevated relative lymphocytic count; 51.1% and reduced absolute one; $1.2 \times 10^3/\mu\text{l}$ (Figure 15). She reported paracetamol, zinc and vitamin C intake and her temperature was reduced to 36.5°C and we were consulted. We advised to replace paracetamol with meloxicam 7.5 mg once daily with monitoring of body temperature which remained 35.6 . Marked improvement was reported within the five-day-course and only mild self-limited diarrhea was reported for two days early in the regimen. Notably, a CBC performed on the sixth day showed an elevated normal leucocytic count; $5.3 \times 10^3/\mu\text{l}$ (Figure 16).

Case 23

A female patient in early 20s has suffered from sore throat, severe headache, dyspnea, dizziness, bone ache that was followed by anosmia and ageusia and her CBC showed leucopenia; $3.36 \times 10^3/\mu\text{l}$ and her absolute neutrophil count was reduced; $1.81 \times 10^3/\mu\text{l}$ while her absolute lymphocytic count was marginally normal; $1.14 \times 10^3/\mu\text{l}$. A colleague has prescribed her azithromycin, levofloxacin, vitamin C and an antitussive/expectorant containing oxomemazine, guaifenesin, sodium benzoate and paracetamol as well as separate paracetamol with partial improvement and she consulted us on the third day. We have stopped the antitussive/expectorant, allowed continuation of azithromycin for two more days, replaced paracetamol with meloxicam 7.5 mg once daily for five days and prohibited the use of a nasal spray containing fluticasone that she wanted to use to manage a concomitant sinusitis and marked improvement was reported within two days and she decided to repeat the CBC that revealed a normal leucocytic count; $4.56 \times 10^3/\mu\text{l}$ as well as elevated absolute lymphocytic count; $2.23 \times 10^3/\mu\text{l}$ and almost normal absolute neutrophil count; $1.97 \times 10^3/\mu\text{l}$.

Case 24

A female in early 30s has complained of fever up to 38.5°C , sore throat, rhinorrhea, mild cough, severe headache, malaise, bone ache and dizziness for which she was self-

prescribed azithromycin for 4 days and one dose of diclofenac potassium with only improvement in fever. She consulted us after noticing anosmia and ageusia together with her husband who has only complained of mild cough and we advised to complete the 5-day-course of azithromycin. Her CBC performed on the fifth day revealed marked leucopenia; $2.4 \times 10^3/\mu\text{l}$ with relative lymphocytosis; 45%. We have prescribed her diclofenac potassium 50 mg bid for five days together with vitamin C, ergocalciferol and zinc that were prescribed without diclofenac to her husband. Marked improvement in all the described clinical manifestations were reported at the end of the 5-day-regimen.

We used lornoxicam 8 mg twice daily and a ketorolac injection once in the first day of a five-day-regimen to manage a highly suspected young adult patient who was a close contact of a confirmed quarantined patient and suffered from deterioration of severe cough episodes, dyspnea and herpetic labialis that followed his self-prescribed two injections of cefotaxime, zinc and vitamins to manage his COVID-19 suggestive manifestations that included fever, upon contact no fever was encountered and only lornoxicam and ketorolac were prescribed as described to successfully manage his condition. However, though his condition was clinically considered moderate-severe, he described a significant improvement in five days, yet residual mild-moderate cough, moderate-severer headache, malaise needed another week to almost full recovery.

Case 25

A couple, both in late 60s, have complained of COVID-19 suggestive manifestations including high fever for which a colleague has prescribed azithromycin and paracetamol, low dose aspirin, zinc, vitamin C and paracetamol, the wife has reported partially improved with mild-moderate fatigue and low grade fever but her husband, who has also been using bisoprolol, amlodipine, fenofibrate and trimetazidine to control his chronic hyperlipidemia, hypertension and ischemic heart disease as well as allopurinol and colchicine to manage gout, has not improved for eleven days and he has reported a deteriorated physical condition including fever; 38°C , severe fatigue and occasional episodes of nocturnal severe hypertension. Upon consultation, we have asked for CBC, CRP and D-dimer for the husband only which showed anemia; 10.3 g/dl and leucopenia; $3.27 \times 10^3/\mu\text{l}$, positive CRP; 96 mg/l and an elevated D-dimer; 1.95 $\mu\text{g/ml}$. After checking the potential drug

interactions and evaluation a personalized risk benefit ratio, we permanently removed colchicine that should have not been administered with fenofibrate; replaced paracetamol and low dose aspirin with lornoxicam 8 mg once daily together a low potassium diet for five days and as the patient reported that he complained of nausea after zinc and vitamin c administration, we replaced them with ergocalciferol 0.25 mg daily for five days and recommended to replace allopurinol with febuxostat after improvement as well as recommendation for both physical and mental rest. Marked clinical improvement was reported during the five days course with no adverse effects and he decided not to repeat any investigations; for the wife she has only been administered likewise lornoxicam and she also has reported full recovery.

Case 26

A female in her early 20s has reported sore throat, fever, dyspnea, severe headache, marked malaise and recurrent troublesome cough episodes to which she has been prescribed azithromycin, paracetamol, zinc and vitamin C with no improvement for two days. Her CBC showed leucopenia and positive low titre of C reactive protein. Upon consultation no fever was detected, yet since azithromycin was already administered, we continued its administration, replaced paracetamol with celecoxib 200 mg once daily for five days and modified the dose of the prescribed zinc to a lower one [11] and marked clinical improvement as regards to headache, cough and malaise was reported from the first day of the five days course. Notably, celecoxib has been advised by other researchers to be clinically tested for COVID-19[12] and when celecoxib was used as adjuvant therapy, it was suggested to promote the recovery of all types of COVID-19 and to reduce the mortality rate of elderly and those with comorbidities [13]. Importantly, this patient complained of acute episodes of tachycardia and generalized abdominal colic that started before our therapy and persisted for four days; we suspected COVID-19 associated vasculitis to be the cause and effectively managed this manifestation by administering pentoxifylline 400 mg bid for five days. Pentoxifylline was reported to be effective in management of another type of immunoinflammatory induced vasculitis[14] and it was also suggested by other researchers to be beneficial as an adjuvant therapy for COVID-19[15].

Case 27

A male patient in his mid-40s with a clinical picture suggestive of mild-moderate COVID-19 including fever up to 39°C has received a protocol of azithromycin, paracetamol, zinc and vitamin C for only three days to which his body temperature fluctuated between 37°C and 38°C. However, a more severe clinical picture of high fever, severe fatigue, profuse sweating, severe episodes of cough with newly developed dyspnea has developed after two days of stopping treatment and we have received a request to treat on that fifth day. Computed tomography has confirmed a viral pneumonia with a bilateral scattered subpleural and parenchymal patches of ground glass opacities suggestive of COVID-19 (Figure 17) and we prescribed parenteral cefoperazone once daily for three days with another course of azithromycin 500 mg once daily for five days as well as oral diclofenac potassium t.d.s for the first two days followed by b.i.d. for three other days when his condition started to improve and we have not prescribed nitazoxanide for this patient waiting for the initial clinical response. The patient has experienced a significant clinical improvement as regards to most of his symptoms with return of body temperature to normal with no additional antipyretic or antibiotics after the new 5-day-course. He has also experienced gradual improvement of his severe cough and got free of its severe episodes after seven days with no antitussive prescribed as discussed before and returned almost normal as regards to cough, after 2 weeks. Interestingly, a follow up CT, performed in another center, one week after the first one has revealed regressive course of viral pneumonia with residual bilateral scattered patches of ground glass opacities. Moreover, though the lymphocytic count of this patient before treatment was 30% and not considered lymphopenic (Figure 18), it has increased to 47.9% after the 5-day-course of treatment (Figure 19) raising another possibility that it might have been deteriorating and the NSAIDs therapeutic intervention has efficiently stopped and reversed this deterioration as also reported with other patients and was previously partly hypothesized as an interpretation for this frequently observed finding[6]. Notably, the CRP level of this patient was 54 mg/l at the start of treatment and has been elevated to 90 mg/l at the end of the 5-day-course and one week after its end, the level has decreased to 9 mg/l. The initial increase in CRP might be explained by an undergoing concomitant bacterial infection that has been treated efficiently by the administered antibiotics. Furthermore, this patient was suffering from

type 1 diabetes mellitus for 8 years and he has experienced a significant deterioration of his blood glucose profile to which we increased the total daily biphasic isophane insulin dosage with new addition of an adjusted dose of insulin glargine for two weeks to be noted that a deterioration of blood glucose profile was also encountered with another highly suspected COVID-19 and was likewise safely managed.

Importantly, considering that we have not been in direct contact with those two patients; we have chosen a pharmacovigilant low dosed regimen of cefoperazone to avoid the very rare potential of vitamin K-dependent coagulopathy which might develop with serious diseases[16], and we administered cefoperazone with full 5-day-course of azithromycin. Interestingly, as the patients' clinical condition improved, no increase of cefoperazone dose or duration of therapy was required. We recommended all the encountered patients to remain isolated for 21 days from the beginning of the symptoms including at least one week, better ten days which we later stuck to it, of a totally symptom free period even if the PCR test revealed negative earlier and this recommendation was to avoid the possibility of any false negative PCR results. This advice was also based on a positive PCR test from an early managed patient, although he was symptom free for more than 10 days. We know that this advice for the isolation period is not consistent with the mainstream current guidelines [17], to be noted that a study has recommended a 22-day quarantine period to avoid the 6.7% failure who showed symptoms after the 14-day quarantine period; the 22-day quarantine showed a failure rate below 1% with 95% confidence[18] and another one that studied the RT-PCR findings of 301 confirmed hospitalized COVID-19 patients throughout disease course, showed the average contagious period of infected patients was 20 days [19].

3.3. Managing COVID-19 pregnant patients

Furthermore, the patients included 3 pregnant patients; one in her 9th week of gestation (confirmed by SARS CoV-2 rapid IgM test and later by PCR); another is a highly suspected case in her 18th week and a third suspected pregnant patient was in her 34th week of gestation and they also have included four children (1.5 – 9 years).

Case 28

The first pregnant patient who was diagnosed while in her 9th week of gestation, has also been treated for rheumatoid arthritis and her COVID-19 clinical picture included fever, sore throat, fatigue, and dry cough. We stopped both hydroxychloroquine and sulfasalazine already used for rheumatoid arthritis during the five-day treatment course to prevent potential adverse drug interactions with our protocol and we successfully used azithromycin/nitazoxanide for her treatment. Similarly, NSAIDs were not prescribed for her as she was already, when diagnosed, on a chronic low dose prednisone for her rheumatoid arthritis. Prenatal four-dimensional ultrasonography that followed the treatment course showed a healthy female fetus with no suspected congenital abnormalities and later she delivered a full term healthy female offspring.

Case 29

The second pregnant patient was in her 18th week of gestation and was highly suspected, by history of close contact to a positive COVID-19 case, clinical manifestations of sore throat, cough, and declining lymphocytic titer (24%) as compared to a previous pre-COVID-19 CBC (39%) and she completed one-week diclofenac potassium 50 mg b.i.d. course, though she was strongly recommended to use it for only five days. However, she has been totally relieved of COVID-19 symptoms with no significant adverse effects reported and she later delivered a full term healthy female offspring. We suggest that the potential benefits might exceed the risks for this short-term NSAIDs regimen for pregnant patients before the third trimester, and we again declare that we followed each case eagerly providing a personalized prescription while simultaneously assessing any possible contraindication or potential drug-drug interactions.

Notably, for pregnant COVID-19 patients in their third trimester we recommend administering only nitazoxanide +/- azithromycin to avoid fetal premature closure of the cardiac ductus arteriosus[20]. However, we suggest that our adopted dose and duration is matching the requirements that the FDA has recently updated as regards to NSAIDs administration to pregnant patients at 20 weeks till the beginning of the third trimester to avoid oligohydramnios [<https://www.fda.gov/drugs/drug-safety-and-availability/fda->

[recommends-avoiding-use-nsaids-pregnancy-20-weeks-or-later-because-they-can-result-low-amniotic](#)].

Case 30

A third pregnant patient, in mid 20s of age and 34th week of gestation, has complained of self-limited diarrhea, mild rhinorrhea, sore throat, headache and moderate dry cough, dyspnea and a low-grade fever for one week, her CBC was normal but the erythrocyte sedimentation rate (1st hour) was positive of 42 mm/hr and a colleague has prescribed her levofloxacin and she has ingested a first dose. Her husband complained of headache and mild cough and upon consultation, we have stopped levofloxacin and replaced it with azithromycin which we considered safer in pregnancy and we prescribed nitazoxanide 500 mg bid and a once daily vitamin C and zinc for five days. For her husband we have only prescribed vitamin C and zinc and marked improvement with relief of all symptoms was reported by both within the 5-day-course.

3.4. Managing Pediatric COVID-19 patients

We also report to use this protocol to manage four children who were highly suspected by history of a close contact to a positive COVID-19 patient, clinical picture including fever, sore throat, diarrhea and/or cough. They recovered smoothly while receiving the described five-day regimen with no reports of adverse effects.

Case 31

One child, daughter of a health care professional, has complained of fever, severe sore throat, headache, malaise, and her relative lymphocytic count was 19.2% (normal range 20-40%). A colleague has already prescribed ceftriaxone, ampicillin/sulbactam, dexamethasone and parenteral paracetamol infusion without significant improvement in her symptoms/signs except for fever. We have immediately stopped dexamethasone, changed paracetamol to ibuprofen and a marked improvement in her symptoms has been reported from the first day.

Case 32 and 33

Another daughter of a health care professional who complained of severe sore throat that led her to severe anorexia, diarrhea and vomiting with a risk for dehydration while on paracetamol and she as well as her sister, complaining of milder manifestations, had completely recovered from their symptoms in three days but continued the five day full regimen and we suggest that the relief of the severe sore throat that restored the appetite might be due to the action of both ibuprofen and azithromycin.

Case 34, 35, 36

Another child was treated after managing her mother; a female patient in her early 30s who has suffered from fever up to 38.5°C, mild rhinorrhea, sore throat, dyspnea, severe bone ache which were followed by anosmia and ageusia. Her CBC showed leucopenia of $2.4 \times 10^3/\mu\text{l}$ with reduced absolute lymphocytic count; $1.08 \times 10^3/\mu\text{l}$ and a marginally high relative lymphocytic count of 45% and a colleague has prescribed azithromycin, paracetamol, zinc and vitamin C and she has self-administered diclofenac potassium when her bone ache was severe with only partial improvement for three days when she consulted us. We asked to continue azithromycin to finish 5 days, replaced paracetamol with diclofenac potassium b.i.d. for three days and once daily for the other two days and marked improvement was reported. Notably, her husband who is in mid 30s has only suffered from mild cough, sore throat, headache and ageusia and though his CBC and CRP revealed normal, yet his serum ferritin was elevated ; 536.3 ng/ml and we advised him to be self-isolated with his family and allowed only zinc and vitamins C and D to be administered and shortly he reported no symptoms except for ageusia. Few days later, their 4-year-old daughter experienced fever up to 38.5°C, rhinorrhea, headache, and malaise. Her CBC showed leucocytosis; $20.5 \times 10^3/\mu\text{l}$ with elevated relative neutrophil count; 78% and reduced relative lymphocytic count 16% with normal absolute lymphocytic count; $3.28 \times 10^3/\mu\text{l}$ and positive CRP titer; 12 mg/dl. We prescribed weight adjusted doses of azithromycin for three days; nitazoxanide for three days and ibuprofen for five days though marked improvement with reported normal temperature was reported starting from the first day.

Importantly, in other less suspected COVID-19 children, not mentioned in this manuscript, complaining of moderate troublesome cough episodes, we added the locally available antitussive suppositories or syrup containing oxomemazine, guaiphenesin, sodium benzoate and paracetamol once at night to allow a better sleep with no reported adverse effects. Interestingly, expert scientists and pediatricians have also recommended the use of NSAIDs where clinically indicated to manage COVID-19 confirmed and suspected children[21].

4. Discussion

We have early suggested, basing on a pharmacological and pathophysiological approach, that restoration of the immunological interferon homeostasis might be our tool to win the COVID-19 battle and we thus we suggested nitazoxanide/azithromycin combination. Later, other studies have subsequently confirmed the genetic and clinical basis that interferons play in COVID-19[22-24]. Notably, the number of nitazoxanide COVID-19 registered clinical trials has currently reached 26 in various countries with only one terminated due to concerns about safety of hydroxychloroquine (NCT04341493) and at least four trials are being conducted in the USA and it was reported that three have been labelled complete studies in Brazil and one was labelled complete in USA, one in Mexico and one in Egypt [<https://clinicaltrials.gov/ct2/results?recrs=&cond=Covid19&term=Nitazoxanide&cntry=&state=&city=&dist=>]. Moreover, an open-label observational study has recently recommended that some drug combinations including azithromycin and nitazoxanide should be considered for those diagnosed early with COVID-19. Furthermore, among the drugs used which included ivermectin, they have opted for nitazoxanide, due to more extensive demonstration of in vitro and in vivo antiviral activity, proven efficacy against other viruses in humans, and steadier safety profile[25]. Similarly, a small randomized, placebo-controlled trial involving mild COVID-19 patients showed that early nitazoxanide significantly eliminated; 29.9% of patients in the nitazoxanide arm versus 18.2% in the placebo arm ($p=0.009$) and reduced viral load ($p=0.006$) as compared to placebo with no serious adverse events and at the 1-week follow-up, 78% in the nitazoxanide arm versus 57% in the placebo arm reported complete resolution of symptoms ($p=0.048$)[26] and later

it was published[27]. Recently, a prospective study has also suggested that early use of nitazoxanide might decrease COVID-19 complications among healthcare personnel[28].

Importantly, other than their suggested potential curative COVID-19, we also noticed that NSAIDs had remarkably superior symptomatic clinical efficacy compared to paracetamol, for those who used paracetamol before switching to the new protocol, for controlling high fever, headache, and malaise. Notably, it was recently suggested that NSAIDs might influence COVID-19 outcomes through modulation of the immune-inflammatory responses rather than modifying susceptibility to infection or viral replication and it was also shown that NSAID treatment did not affect ACE2 expression in human cells and mice nor did NSAIDs affect SARS-CoV-2 entry or replication in vitro, yet NSAIDs were shown to dampen the induction of proinflammatory cytokines that are upregulated by SARS-CoV-2 infection in mice[29] and we agree with their call to assess their effects in humans and we suggest basing on our real-life practice that recommended the use NSAIDs for COVID-19 that it is probable to discover beneficial NSAIDs effects on both the humoral and cellular immunity[7]. Moreover, the significant elevation of lymphocytes frequently observed with the majority of our patients might be considered as a preliminary clinical proof of our suggested COVID-19 pathogenesis theory[6,30,31] while the significant decrease of the elevated neutrophils count in some patients might represent the efficacy of azithromycin in eliminating any associated secondary bacterial infection. Interestingly, the absolute lymphocyte count was shown to be an early prognostic marker associated with disease severity and other clinical outcomes in COVID-19[32].

Notably, the imaging tests including CT were shown to lack specificity and the PCR and SARS CoV-2 Ig M tests were also shown to possess sensitivity flaws[33] and we suggest that our management protocol has a major advantage that it could be started early to manage COVID-19 suspected patients without the need of expensive/complex investigations. Moreover, most of the patients who received our protocol early in their COVID-19 course have improved during its five-day duration as compared to other patients who contacted us relatively later complaining of COVID-19 related severe malaise, anorexia, moderate diarrhea, anosmia, dysgeusia, ageusia, moderate to severe flank, back pain or herpetic labialis who have been totally improved in two weeks.

Interestingly, some young individuals were close contacts to positive COVID-19 cases with no or very mild symptoms e.g., mild sore throat or mild cough without fever and for those suspected silent carriers, only isolation +/- zinc and vitamins was advised and reassurance was granted during their smooth follow up. Importantly, we initially used ibuprofen to manage our COVID-19 patients basing on our article that acquitted it from the claimed potential damage [34] and yet we soon shifted, with comparable efficacy and safety, to diclofenac potassium and other NSAIDs which we have more frequently used to manage most of our non-COVID-19 patients and we reserved ibuprofen for pediatric patients.

We were and are aware that our positive old recommendation to adopt NSAIDs as first choice COVID-19 therapy has long contradicted the more prevalent approach adopted worldwide that has practically avoided, and very unfortunately still in many countries all over the world avoiding, NSAIDs use for COVID-19 in favor for paracetamol that does not possess major peripheral anti-inflammatory effects as compared to NSAIDs[35]. Eventually, the very unfortunate academic misconduct that led to the avoidance of NSAIDs to be prioritized for COVID-19 has been fully illustrated and refuted from pharmacological and clinical perspectives to be noted that since March 2020 we have struggled to refute these contradictory claims to ultimately manage six months later in publishing a peer-reviewed article to join other colleagues [34,36,37]. Notably, aspirin, which is a non-steroidal anti-inflammatory drug, has been also shown in an observational cohort study to be associated with a significantly lower rate of mechanical ventilation, intensive care unit admission, and in-hospital mortality after controlling for confounding variables[38] and we have preprinted our insight of the interpretation of this important study[39] and added more potential mechanisms that might reason for the potential benefits of NSAIDs in COVID-19 management[40]. Interestingly, ibuprofen use was not shown to be associated with worse COVID-19 clinical outcomes [41-46] and it has been shown to be among the drugs that are significantly associated with diminished COVID-19 risk for hospitalization as revealed by an In silico cohort study that examined the electronic health records from individuals 7,360 individuals with COVID-19 positive test results by PCR. Furthermore, ibuprofen and naproxen, which are both among NSAIDs, were more commonly prescribed among individuals not requiring intensive care [47] and the routinely prescribed NSAIDs

were not found to be associated with COVID-19 mortality and their administration in COVID-19 was advised not to be influenced by unproved fear[46]. Notably, two registered recruiting clinical trials to test the role of ibuprofen in COVID-19 are undergoing; one in the UK testing lipid ibuprofen (NCT04334629) and the other to test experimental inhaled hypertonic ibuprofen in Argentina (NCT04382768). Similarly, The BMJ Best Practice guidelines for COVID-19 management, updated on November 27, 2020 have recommended paracetamol or ibuprofen for the symptomatic management of fever and pain. However, though clearly stating that there is no current evidence of ibuprofen induced severe adverse effects in COVID-19, they have wisely recommended to use ibuprofen at the lowest effective dose for the shortest period to control COVID-19 symptoms and we suggest we have adopted this pharmacovigilant approach in our practice long before these recommendations have evolved. Later, BMJ [<https://bestpractice.bmj.com/topics/en-us/3000168/treatment-algorithm#referencePop618>] followed NICE [<https://www.nice.org.uk/guidance/ng163/chapter/5-Managing-fever>] guidelines recommending either paracetamol or ibuprofen to be used for COVID-19 and we look forward to the day when paracetamol would be the second choice only when NSAIDs are absolutely contraindicated[6]. Importantly, an objective analysis has found no conclusion of causation between ibuprofen and risk of thromboembolism and when the risk is claimed it is often associated with long term and/or the use of high doses[48] which is apparently the opposite to what we have adopted. On the contrary, we claim that the anti-IL-6 properties of our adopted short course of NSAIDs[7] might decrease the incidence of thromboembolism[49]. Unfortunately, we have encountered medical malpractice and misuse of corticosteroids and anticoagulants in mild-moderate COVID-19 that sometimes costed the lives of young patients to be noted that those physicians are confident of impunity in the developing countries as the mortality is simply attributed to COVID-19.

Notably, we allowed all patients to continue the already prescribed vitamin C, Vitamin D, zinc, lactoferrin or any other food supplements, although their proven clinical benefit, if any, are yet to be proved. However, we have changed any already prescribed dose of zinc according to our clinical and academic judgment, it should be kept to the minimum[11] and we suggest these supplements when administered, in their proper dosage, are almost harmless regardless if they might or might not prove beneficial synergistic effect.

On the other hand, we admit that the small number of patients is a very important limitation of our reported observations, yet clinical case reports are known to detect novelties, generate hypotheses as well as to solve ethical constraints[50]. Moreover, we are aware that observational studies have a known bias of over interpretation tendency[50], yet we confirm that we presented only the most trustworthy findings, confirming that we have no conflict of interests of whatever and more importantly we have for almost a year repeatedly recommended performing sufficiently powered controlled clinical trials with double blind randomization against a standard care protocol.

Furthermore, we had to consider not to ask for extensive investigations for each patient as some reported limited economic or logistic resources and we received, with gratitude, the provided photocopies of the performed investigations which they captured using their mobile phones and we could not ask for better quality photos as we knew, this is the best they could offer. However, we suggest that other researchers with better capabilities should build on this protocol as well as other scientifically supported drugs [11] and release their results and/or modifications soonest for the best interests of patients who eagerly anticipate these results [4,6].

Importantly, we wish to suggest that our described COVID-19 short course management protocol, including NSAIDs as integral component, has shown prompt efficacy, full compliance, excellent tolerability, and no reported serious adverse effects. Moreover, we wish to suggest that the described immunomodulatory properties of its adopted drugs might prove as potentially lifesaving not only for COVID-19 but also for other fatal viral diseases especially when these drugs are used early in their immunopathologic course [31] while using relatively safe and FDA approved drugs which are readily available in most countries all over the world and very much economic especially for the best interests of patients in developing countries. Furthermore, we suggest that our early pioneering and repeatedly ignored positive recommendation to use of NSAIDs as early as possible in the course of COVID-19, would also be soon proven lifesaving as ours for nitazoxanide/azithromycin, wishing it might be adopted soonest in a trial to save precious lives of patients who might not promptly receive a vaccine in the developing countries and of patients who are not permitted to receive a vaccine like pediatric, pregnant and other patients as well as of those

patients who might encounter a vaccine-resistant SARS CoV-2 variant in the developed countries as we truly believe that all human lives are equal, precious and worth saving.

Ethics, consent, and permissions

This research was carried out according to the ethical considerations recognized by the principles of the World Medical Association Helsinki declaration (64th WMA General Assembly, Fortaleza, Brazil, October 2013) and all its amendments. None of the used drugs was ever contraindicated to be used for COVID-19 patients by the WHO or FDA and according to the risk benefit ratio, our protocol had a potential significant benefit and less than minimal risk especially when compared to some standard care repurposed protocols that proved a failure and potentially hazardous later[51-54]. However, in every case, an informed verbal consent, which was also evident by the written mutual conversations through the mentioned social media applications, was obtained from each case/legal guardian involved in this study.

Consent to publish

Informed consent was obtained from all patients for this study.

Acknowledgments

All the mentioned medical consultations were performed free of charge and my Lord Jesus Christ who has always protected and helped me while enduring so much depression and trouble is the One who should be thanked. This work is dedicated to the memory of my great forefather St. Athanasius of Alexandria (296 – 373 AD) who once stood bravely, with the help of great Egyptian believers, against the world, I am very proud of his example. My mother; Neama Botros Rezk, wife; Ereny Frans Abdelsayed and two beloved daughters; Elena and Eleanor have been and still are my main motive to search for a safe management of COVID-19, I am totally indebted to their love, patience, and endurance. I wish also to sincerely thank all the Arab patients mentioned in this manuscript and their family members who carefully watched their treatment. Also, many thanks to Dr. Haroun Akhnoukh from Egypt and Dr. Pablo Juárez from Mexico for their precious confirmatory clinical feedback after they have read preprints of this manuscript.

Competing interests

The author declares no competing interests.

References

1. Ibarondo FJ, Fulcher JA, Goodman-Meza D, Elliott J, Hofmann C, Hausner MA, Ferbas KG, Tobin NH, Aldrovandi GM, Yang OO: **Rapid Decay of Anti-SARS-CoV-2 Antibodies in Persons with Mild Covid-19.** *New England Journal of Medicine* 2020.
2. Kemp SA, Collier DA, Datir R, Gayed S, Jahun A, Hosmillo M, Ferreira IATM, Rees-Spear C, Mlcochova P, Lumb IU, et al.: **Neutralising antibodies drive Spike mediated SARS-CoV-2 evasion.** *medRxiv* 2020:2020.2012.2005.20241927.
3. Kelleni MT: **Autoimmunity and Antibody Dependent COVID-19 Enhancement of SARS CoV-2 Vaccination: Moving from Nobel Prize to Prison Sentence.** *OSFPREPRINTS (Preprint)* 2021.
4. Kelleni MT: **Nitazoxanide/Azithromycin combination for COVID-19: A suggested new protocol for COVID-19 early management.** *Pharmacological Research* 2020:104874.
5. Kelleni M: **Ibuprofen potential addition to COVID-19 early management protocols: could it be superior to paracetamol and hydroxychloroquine?** In *Authorea (Preprint)* 2020.
6. Kelleni MT: **Early use of non-steroidal anti-inflammatory drugs in COVID-19 might reverse pathogenesis, prevent complications and improve clinical outcomes.** *Biomedicine & Pharmacotherapy* 2021, **133**:110982.
7. Kelleni MT: **Non-steroidal Anti-inflammatory Drugs/nitazoxanide/azithromycin Potential Beneficial COVID-19 Effects: Preventing the Cytokine Storm via Mitigation of the Interleukin-6 Amplifier and Monocytic Immunological Dysrhythmia.** *OSFPREPRINTS (Preprint)*, 2021.
8. Pappan N, Benkhadra R, Papincak D, Ashker K, Uchin J, Sidique N, Pirani Z, Clemenza P: **Values and Limits of Telemedicine: a Case Report.** *SN Comprehensive Clinical Medicine* 2021.
9. la Marca G, Barp J, Frenos S, Mugelli A, Galli L, Calistri E, Biasucci G, De Masi S, Guerrini R: **Thermal inactivation of SARS COVID-2 virus: Are steam inhalations a potential treatment?** *Life Sciences* 2021, **265**:118801.
10. Borowiec A, Dąbrowski R, Kowalik I, Rusinowicz T, Hadzik-Błaszczak M, Krupa R, Życińska K: **Elevated levels of d-dimer are associated with inflammation and disease activity rather than risk of venous thromboembolism in patients with granulomatosis with polyangiitis in long term observation.** *Advances in Medical Sciences* 2020, **65**:97-101.
11. Kelleni MT: **Resveratrol-zinc nanoparticles or pterostilbene-zinc: Potential COVID-19 mono and adjuvant therapy.** *Biomed Pharmacother* 2021, **139**:111626.
12. Baghaki S, Yalcin CE, Baghaki HS, Aydin SY, Daghan B, Yavuz E: **COX2 inhibition in the treatment of COVID-19: Review of literature to propose repositioning of celecoxib for randomized controlled studies.** *International Journal of Infectious Diseases* 2020, **101**:29-32.
13. Hong W, Chen Y, You K, Tan S, Wu F, Tao J, Chen X, Zhang J, Xiong Y, Yuan F, et al.: **Celebrex Adjuvant Therapy on Coronavirus Disease 2019: An Experimental Study.** *Frontiers in Pharmacology* 2020, **11**.
14. Wahba-Yahav AV: **Chronic leukocytoclastic vasculitis associated with polycythemia vera: effective control with pentoxifylline.** *J Am Acad Dermatol* 1992, **26**:1006-1007.

15. Seirafianpour F, Mozafarpour S, Fattahi N, Sadeghzadeh-Bazargan A, Hanifiha M, Goodarzi A: **Treatment of COVID-19 with pentoxifylline: Could it be a potential adjuvant therapy?** *Dermatologic therapy* 2020, **33**:e13733-e13733.
16. Hu H-R: **Fatal Vitamin K-Dependent Coagulopathy Associated with Cefoperazone/Sulbactam: A Case Report.** *Drug safety - case reports* 2019, **6**:6-6.
17. Walsh KA, Spillane S, Comber L, Cardwell K, Harrington P, Connell J, Teljeur C, Broderick N, de Gascun CF, Smith SM, et al.: **The duration of infectiousness of individuals infected with SARS-CoV-2.** *Journal of Infection* 2020, **81**:847-856.
18. Li M, Chen P, Yuan Q, Song B, Ma J: **Transmission characteristics of the COVID-19 outbreak in China: a study driven by data.** *medRxiv* 2020:2020.2002.2026.20028431.
19. Xiao AT, Tong YX, Gao C, Zhu L, Zhang YJ, Zhang S: **Dynamic profile of RT-PCR findings from 301 COVID-19 patients in Wuhan, China: A descriptive study.** *Journal of Clinical Virology* 2020, **127**:104346.
20. Koren G, Florescu A, Costei AM, Boskovic R, Moretti ME: **Nonsteroidal Antiinflammatory Drugs During Third Trimester and the Risk of Premature Closure of the Ductus Arteriosus: A Meta-Analysis.** *Annals of Pharmacotherapy* 2006, **40**:824-829.
21. Vosu J, Britton P, Howard-Jones A, Isaacs D, Kesson A, Khatami A, Marais B, Nayda C, Outhred A: **Is the risk of ibuprofen or other non-steroidal anti-inflammatory drugs increased in COVID-19?** *Journal of Paediatrics and Child Health* 2020, **56**:1645-1646.
22. Grant RA, Morales-Nebreda L, Markov NS, Swaminathan S, Querrey M, Guzman ER, Abbott DA, Donnelly HK, Donayre A, Goldberg IA, et al.: **Circuits between infected macrophages and T cells in SARS-CoV-2 pneumonia.** *Nature* 2021.
23. Pairo-Castineira E, Clohisey S, Klaric L, Bretherick AD, Rawlik K, Pasko D, Walker S, Parkinson N, Fourman MH, Russell CD, et al.: **Genetic mechanisms of critical illness in Covid-19.** *Nature* 2020.
24. Lopez L, Sang PC, Tian Y, Sang Y: **Dysregulated Interferon Response Underlying Severe COVID-19.** *Viruses* 2020, **12**.
25. Cadegiani FA, Goren A, Wambier CG, McCoy J: **Early COVID-19 Therapy with Azithromycin Plus Nitazoxanide, Ivermectin or Hydroxychloroquine in Outpatient Settings Significantly Reduced Symptoms Compared to Known Outcomes in Untreated Patients.** *medRxiv* 2020:2020.2010.2031.20223883.
26. Rocco PRM, Silva PL, Cruz FF, Junior MACM, Tierno PFGMM, Moura MA, De Oliveira LFG, Lima CC, Dos Santos EA, Junior WF, et al.: **Early use of nitazoxanide in mild Covid-19 disease: randomized, placebo-controlled trial.** *medRxiv* 2020:2020.2010.2021.20217208.
27. Rocco PRM, Silva PL, Cruz FF, Junior MACM, Tierno PFGMM, Moura MA, De Oliveira LFG, Lima CC, Dos Santos EA, Junior WF, et al.: **Early use of nitazoxanide in mild Covid-19 disease: randomised, placebo-controlled trial.** *European Respiratory Journal* 2020:2003725.
28. Mendieta Zerón H, Meneses Calderón J, Paniagua Coria L, Meneses Figueroa J, Vargas Contreras MJ, Vives Aceves HL, Carranza Salazar FM, Californias Hernández D, Miraflores Vidaurri E, Carrillo González A, et al.: **Nitazoxanide as an early treatment to reduce the intensity of COVID-19 outbreaks among health personnel.** *World Acad Sci J* 2021, **3**:23.
29. Chen JS, Alfajaro MM, Chow RD, Wei J, Filler RB, Eisenbarth SC, Wilen CB: **Nonsteroidal Anti-inflammatory Drugs Dampen the Cytokine and Antibody Response to SARS-CoV-2 Infection.** *Journal of Virology* 2021, **95**:e00014-00021.

30. Kelleni MT: **SARS CoV-2 Might Exploit Cells of the Innate Immune System to Induce the Novel Acute Immune Dysrhythmic Syndrome (n-AIDS) and Para COVID-19 Syndrome.** *OSFPREPRINTS (Preprint)* 2021.
31. Kelleni MT: **COVID-19 and Ebola Reclassification as Novel Acute Immune Deficiency Syndrome (n-AIDS): Potential Curative Role for Immunomodulators.** *OSFPREPRINTS (Preprint)*, 2021.
32. Wagner J, DuPont A, Larson S, Cash B, Farooq A: **Absolute lymphocyte count is a prognostic marker in Covid-19: A retrospective cohort review.** *International Journal of Laboratory Hematology* 2020, **42**:761-765.
33. Goudouris ES: **Laboratory diagnosis of COVID-19.** *Jornal de pediatria* 2021, **97**:7-12.
34. Kelleni MT: **ACEIs, ARBs, ibuprofen originally linked to COVID-19: the other side of the mirror.** *Inflammopharmacology* 2020, **28**:1477-1480.
35. Anderson BJ: **Paracetamol (Acetaminophen): mechanisms of action.** *Pediatric Anesthesia* 2008, **18**:915-921.
36. Moore N, Carleton B, Blin P, Bosco-Levy P, Droz C: **Does Ibuprofen Worsen COVID-19?** *Drug safety* 2020, **43**:611-614.
37. Giollo A, Adami G, Gatti D, Idolazzi L, Rossini M: **Coronavirus disease 19 (Covid-19) and non-steroidal anti-inflammatory drugs (NSAID).** *Annals of the Rheumatic Diseases* 2021, **80**:e12.
38. Chow JH, Khanna AK, Kethireddy S, Yamane D, Levine A, Jackson AM, McCurdy MT, Tabatabai A, Kumar G, Park P, et al.: **Aspirin Use Is Associated With Decreased Mechanical Ventilation, Intensive Care Unit Admission, and In-Hospital Mortality in Hospitalized Patients With Coronavirus Disease 2019.** *Anesthesia & Analgesia* 2021, **132**.
39. Kelleni MT: **The potential crucial role of COX-1 inhibition and/or Aspirin triggered lipoxins and resolvins in amelioration of COVID-19 mortality.** *OSFPREPRINTS (Preprint)*, 2021.
40. Kelleni MT: **NSAIDs, SARS CoV-2 ORF Proteins, Caspases, and CARD14: Solving the Mystery of COVID-19 and Beyond.** *OSFPREPRINTS (Preprint)*, 2021.
41. Rinott E, Kozar E, Shapira Y, Bar-Haim A, Youngster I: **Ibuprofen use and clinical outcomes in COVID-19 patients.** *Clinical Microbiology and Infection.*
42. Lund LC, Kristensen KB, Reilev M, Christensen S, Thomsen RW, Christiansen CF, Stovring H, Johansen NB, Brun NC, Hallas J, et al.: **Adverse outcomes and mortality in users of non-steroidal anti-inflammatory drugs who tested positive for SARS-CoV-2: A Danish nationwide cohort study.** *PLoS Med* 2020, **17**:e1003308.
43. Abu Esba LC, Alqahtani RA, Thomas A, Shamas N, Alswaidan L, Mardawi G: **Ibuprofen and NSAID Use in COVID-19 Infected Patients Is Not Associated with Worse Outcomes: A Prospective Cohort Study.** *Infectious diseases and therapy* 2020:1-16.
44. WHO (Scientific Brief): **The use of non-steroidal anti-inflammatory drugs (NSAIDs) in patients with COVID-19.** 2020, April 19.
45. Abu Esba LC, Alqahtani RA, Thomas A, Shamas N, Alswaidan L, Mardawi G: **Ibuprofen and NSAID Use in COVID-19 Infected Patients Is Not Associated with Worse Outcomes: A Prospective Cohort Study.** *Infectious diseases and therapy* 2021, **10**:253-268.
46. Wong AYS, MacKenna B, Morton CE, Schultze A, Walker AJ, Bhaskaran K, Brown JP, Rentsch CT, Williamson E, Drysdale H, et al.: **Use of non-steroidal anti-inflammatory drugs and risk of death from COVID-19: an OpenSAFELY cohort analysis based on two cohorts.** *Annals of the Rheumatic Diseases* 2021:annrheumdis-2020-219517.

47. Castro VM, Ross RA, McBride SMJ, Perlis RH: **Identifying common pharmacotherapies associated with reduced COVID-19 morbidity using electronic health records.** *medRxiv* 2020:2020.2004.2011.20061994.
48. Arjomandi Rad A, Vardanyan R, Tas NR: **Ibuprofen and thromboembolism in SARS-COV2.** *Journal of Thrombosis and Haemostasis* 2020, **18**:2425-2427.
49. Tamaki H, Khasnis A: **Venous thromboembolism in systemic autoimmune diseases: A narrative review with emphasis on primary systemic vasculitides.** *Vascular Medicine* 2015, **20**:369-376.
50. Nissen T, Wynn R: **The clinical case report: a review of its merits and limitations.** *BMC research notes* 2014, **7**:264-264.
51. Tan Q, Duan L, Ma Y, Wu F, Huang Q, Mao K, Xiao W, Xia H, Zhang S, Zhou E, et al.: **Is oseltamivir suitable for fighting against COVID-19: In silico assessment, in vitro and retrospective study.** *Bioorganic chemistry* 2020, **104**:104257-104257.
52. Pan H, Peto R, Karim QA, Alejandria M, Henao-Restrepo AM, García CH, Kieny M-P, Malekzadeh R, Murthy S, Preziosi M-P, et al.: **Repurposed antiviral drugs for COVID-19 –interim WHO SOLIDARITY trial results.** *medRxiv* 2020:2020.2010.2015.20209817.
53. Horby PW, Mafham M, Bell JL, Linsell L, Staplin N, Emberson J, Palfreeman A, Raw J, Elmahi E, Prudon B, et al.: **Lopinavir-ritonavir in patients admitted to hospital with COVID-19 (RECOVERY): a randomised, controlled, open-label, platform trial.** *The Lancet* 2020, **396**:1345-1352.
54. Kelleni MT: **Tocilizumab, Remdesivir, Favipiravir, and Dexamethasone Repurposed for COVID-19: a Comprehensive Clinical and Pharmacovigilant Reassessment.** *SN Comprehensive Clinical Medicine* 2021, **3**:919-923.

Figure 1: pre-treatment CBC showing absolute lymphopenia



Figure 2: post-treatment CBC showing a highly significant increase in lymphocytes

Complete blood picture				
Test	Result	Unit	Reference range	
Hb&indices				
Haemoglobin	15.6	gm/dl	12.5 - 17.0	
Haematocrit (PCV)	44.7	%	39 - 49	
Red Cell Count	5.18	mil/cmm	4.3 - 5.7	
MCV	86	fl	80 - 99	
MCH	30	pg	27 - 34	
MCHC	35	%	32 - 37	
TLC & Differential				
	<u>Result</u>	<u>Relative</u>	<u>Absolute Result</u>	<u>Absolute Normal</u>
White cell count	6.3		Thousand/cmm	4 - 11
Basophils	0	0 - 2	0 /cmm	0 - 100
Eosinophils	2	1 - 4	126 /cmm	0 - 800
Staff	1	0 - 6	63 /cmm	0 - 200
Segmented	48	37-75	3024 /cmm	2000 - 7200
Lymphocytes	43	20-45	2709 /cmm	1500 - 3500
Monocytes	6	2 -10	378 /cmm	200 - 900
PLT				
Platelet count	270		Thousand/cmm	150 - 450
MPV	8.6		fl	6.5 - 12
PDW	11.3			9 - 17
P-LCC	49		$\times 10^9/L$	30 - 90
Comments				
BLOOD PICTURE IS WITHIN NORMAL RANGE FOR AGE & SEX.				

Figure 3: Pre-treatment CBC showing relative lymphocytopenia

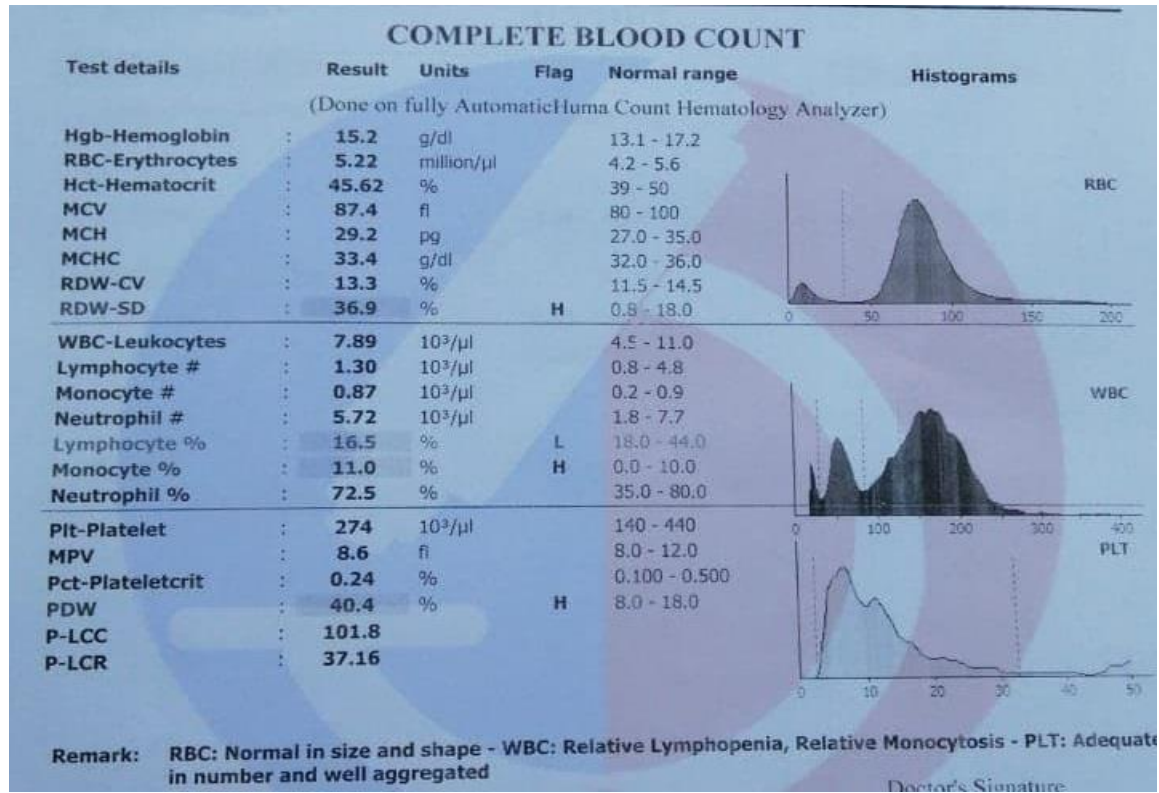


Figure 4: Post-treatment CBC showing normal significantly elevated lymphocytopenia

COMPLETE BLOOD COUNT				
Test details	Result	Units	Flag	Normal range
• Hgb-Hemoglobin	13.6	g/dl		13.1 - 17.2
• RBC-Erythrocytes	5.42	million/ μ l		4.2 - 5.6
Hct-Hematocrit	46	%		39 - 50
MCV	85	fL		80 - 100
MCH	25	pg	L	27.0 - 35.0
MCHC	29.5	g/dl	L	32.0 - 36.0
RDW-CV	14	%		11.5 - 14.5
• Plt-Platelet	373	$10^3/\mu$ l		150 - 440
MPV	8.5	fL		8.0 - 12.0
Pct-Plateletcrit	0.315	%		0.100 - 0.500
PDW	9.5	%		8.0 - 18.0
• WBC-Leukocytes	6.9	$10^3/\mu$ l		4.5 - 11.0
WBC differential		Relative count %	Absolute count $10^3/\mu$ l	
LYM%	36.2	18.0 - 44.0	2.4	0.8 - 4.8
MON%	8.3	0.0 - 10.0	0.5	0.2 - 0.9
GRA%	53.4	35.0 - 80.0	3.68	1.8 - 7.7
Segm.%	53.4	35 - 80	3.68	1.6 - 7.1
Band%	0	0 - 11	0	0.0 - 1.2
EOS%	2.1	0.0 - 3.0	0.14	0.0 - 0.8
BAS%	0	0.0 - 1.0	0	0.0 - 0.1

Figure 5: Pre-treatment CBC showing leucopenia

Complete Blood Picture				
Haemoglobin	13.7	g/dl		12.5 - 17.5
Haematocrit (PCV)	41.1	%		41 - 52
RBCs Count	4.96	Millions / cmm		4.5 - 5.9
MCV	82.9	fl		80 - 100
MCH	27.6	pg		27 - 33
MCHC	33.3	g/dl		31 - 37
RDW-CV	13.7	%		11.5 - 15
Platelet Count (EDTA Blood)	259	thousands / cmm		150 - 450
Total Leucocytic Count (EDTA Blood)	3.5	thousands / cmm		4 - 11
	<u>Percent Values</u>		<u>Absolute Values</u>	
Neutrophils	57.8	%	2.04	x10 ⁹ /L
Lymphocytes	27.5	%	0.97	x10 ⁹ /L
Monocytes	14.4	%	0.51	x10 ⁹ /L
Eosinophils	0.0	%	0.00	x10 ⁹ /L
Basophils	0.3	%	0.01	x10 ⁹ /L

Figure 6: Post-treatment CBC showing normal leucocytic count

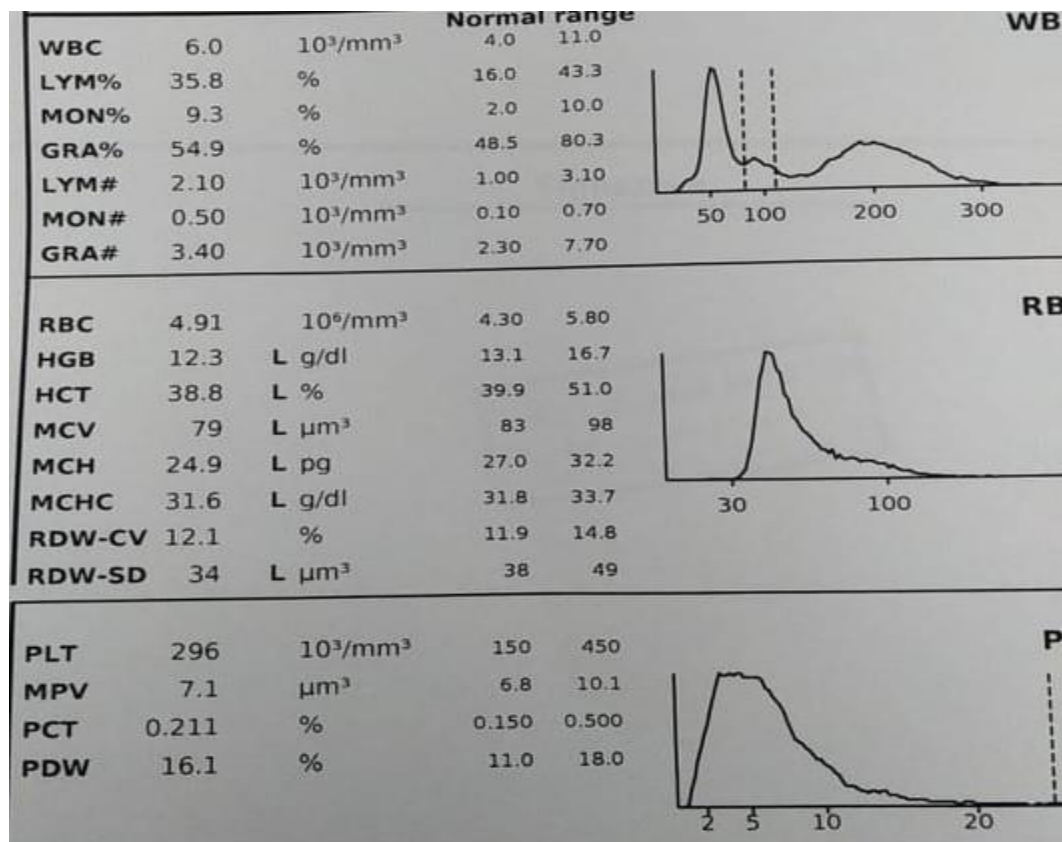


Figure 7: CT showing features highly suspicious of COVID-19

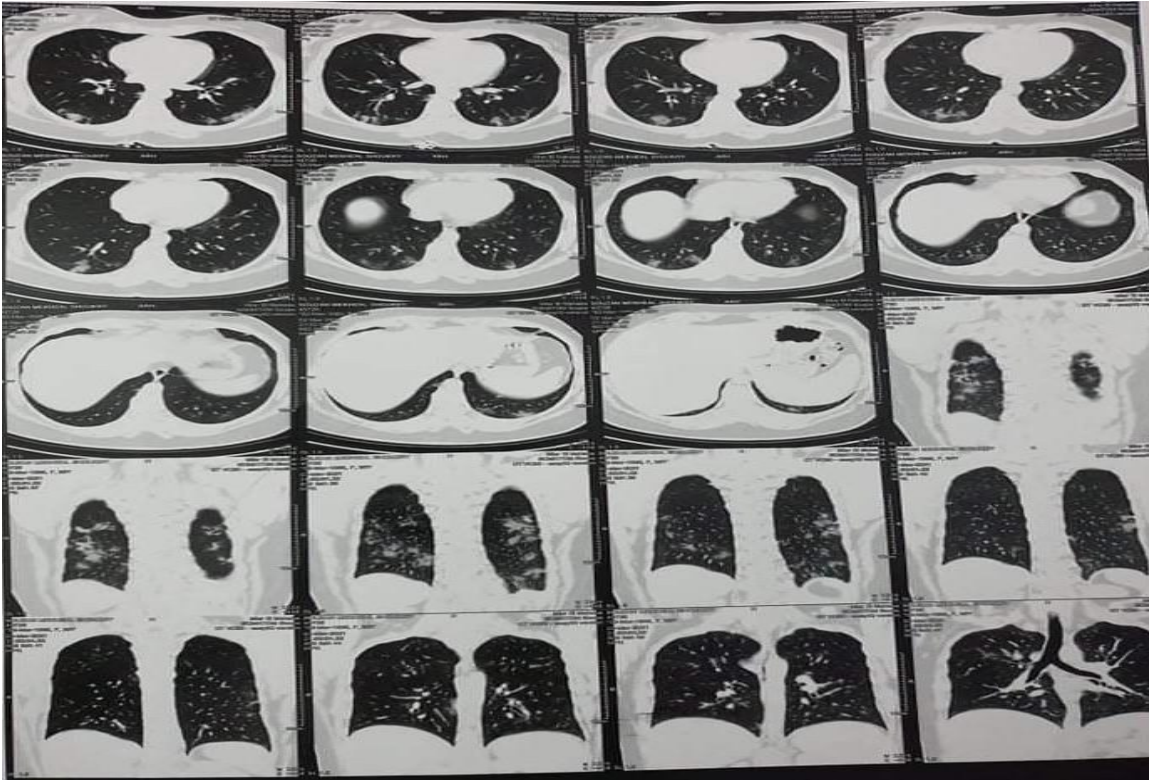

Figure 8: Pre-treatment CBC showing leucopenia and lymphopenia

HEMATOLOGY REPORT					
			Reference Range		
Hgb (Hemoglobin)	11.4	L	11.7 - 16.0 g/dl		
RBCs (Red Blood Cells)	4.5		3.8 - 5.3 x 10 ³ Cells/uL		
Hct (Hematocrit)	34.7	L	35 - 47 %		
MCV	77				
MCH	77.1	L	80 - 100 fL/cell		
MCHC	25.3	L	27 - 34 pg/cell		
RDW	32.9		32 - 37 g/dl		
Plt (Platelet)	14.3		11.5 - 14.5 %		
• Pct	134	L	150 - 440 x 10 ³ /mm ³		
• MPV	1.42	H	0.100 - 0.500 %		
• PDW	106	H	8.0 - 12.0 fL		
WBCs (Leukocytes)	16.6		10.0 - 18.0 %		
Test	3.64	L	4.5 - 11.0 x 10 ³ /mm ³		
			Relative count %		Absolute count K/uL
• Neutrophil	75		35.0 - 80.0		2.73 1.8 - 7.7
• Lymphocytes	15	L	18 - 44	0.55 L	0.8 - 4.8
• Monocytes	8		0 - 10		0.29 0.2 - 0.5
• Eosinophils	2		0 - 3		0.07 0 - 0.8
• Basophils	0		0 - 1		0 0 - 0.1

Figure 9: Post-treatment CBC showing normal leucocytic and lymphocytic counts

HEMATOLOGY REPORT				
Blood Picture:			Reference Range :	
Hgb (Hemoglobin)	:	10.7 L	11.0 - 16.0 g/dL	
RBCs (Red Blood Cells)	:	4.21	4.0 - 6.0 x 10 ³ Cells/ μ L	
Hct (Hematocrit)	:	34.3 L	35 - 50 %	
MCV	:	81.5	73 - 93 fL/cell	
MCH	:	25.4 L	27 - 34 pg/cell	
MCHC	:	31.2	29 - 40 g/dL	
Plt (Platelet)	:	215	150 - 450 x 10 ³ /mm ³	
WBCs (Leukocytes)	:	7.4	4.0 - 11.0 x 10 ³ /mm ³	
Test	Relative count %		Absolute count K/ μ L	
Neutrophil	:	64 40 - 75	4.74	1.5 - 7.0
Lymphocytes	:	30 20 - 45	2.22	1.0 - 3.7
Monocytes	:	5 2 - 10	0.37	0.0 - 0.7
Eosinophils	:	1 1 - 5	0.07	0.0 - 0.4
Basophils	:	0 0 - 1	0	0 - 0.1

Figure 10: Pre-treatment CBC showing absolute lymphopenia

Complete Blood Picture				
Hemoglobin	:12.7	Gm/dl	(N. M 13 - 17 , F 12 - 15)
R.B.Cs.	:4890.000.....	cu mm.	(N. 4.500.000 - 6.500.000)
Haematocrite	:38.9%	(N. 41 - 52 %)
M.C.V.	:	86	fL	(80 - 100)
M.C.H.	:	25	Pico.gm	(27 - 31)
M.C.H.C.	:	30	%	(32 - 36)
Reticulocytes	:		%	(0.5 - 2.5)
RDW	:	12.7	%	(10.0 - 15.0)
Total Leucocytic Count	:	... 5.100	/ cu mm	(N. 4.000 - 11.000)
Platelet Count	: 186.000	/ cu mm	(N. 150.000 - 450.000)
<u>DIFFERENTIATION COUNT:</u>				
	Patients		Normal	Absolute C. Normal
Staff	4		1 - 5	(10 ³ /mm ³) (10 ³ /mm ³)
Segment	78		45 - 75	4.3 2-7
Lymphocyte	12		25 - 45	0.6 1-3
Monocyte	6		2 - 8	0.3 0.3-1.0
Eosinophil	0		1 - 6	0 0.1-0.5
Basophil	0		0 - 1	
Other Cells :				
Comment				
*Absolute lymphopenia			Signature	

Figure 11: Post-treatment CBC showing a highly significant increase in lymphocytes

<u>Complete Blood Picture</u>				
Hemoglobin	:12.6	Gm/dl	(N. M 13 - 17 , F 12 - 15)
R.B.Cs.	:4.870.000.....	cu mm.	(N. 4.500.000 – 6.500.000)
Haematocrite	:38.7%	(N. 41 - 52 %)
M.C.V.	:	79	fL	(80 -100)
M.C.H.	:	25	Pico.gm	(27 -31)
M.C.H.C.	:	33	%	(32 -36)
Reticulocytes	:		%	(0.5 – 2.5)
RDW	:	12.9	%	(10.0 – 15.0)
Total Leucocytic Count	:	... 6.000	/ cu mm	(N. 4.000 – 11.000)
Platelet Count	: 236.000	/ cu mm	(N. 150.000 - 450.000)
<u>DIFFERENTIATION COUNT :</u>				
	Patients	Normal	Absolute C.	Normal
		1 – 5	(10 ³ /mm ³)	(10 ³ /mm ³)
Staff	4	45 – 75	4.2	2-7
Segment	64	25 – 45	1.3	1-3
Lymphocyte	23	2 – 8	0.5	0.3-1.1
Monocyte	9	1 – 6	0	0.1-0.6
Eosinophil	0	0 – 1		
Basophil	0			
Other Cells :				

Figure 12: Pre-treatment chest CT suggestive of COVID-19

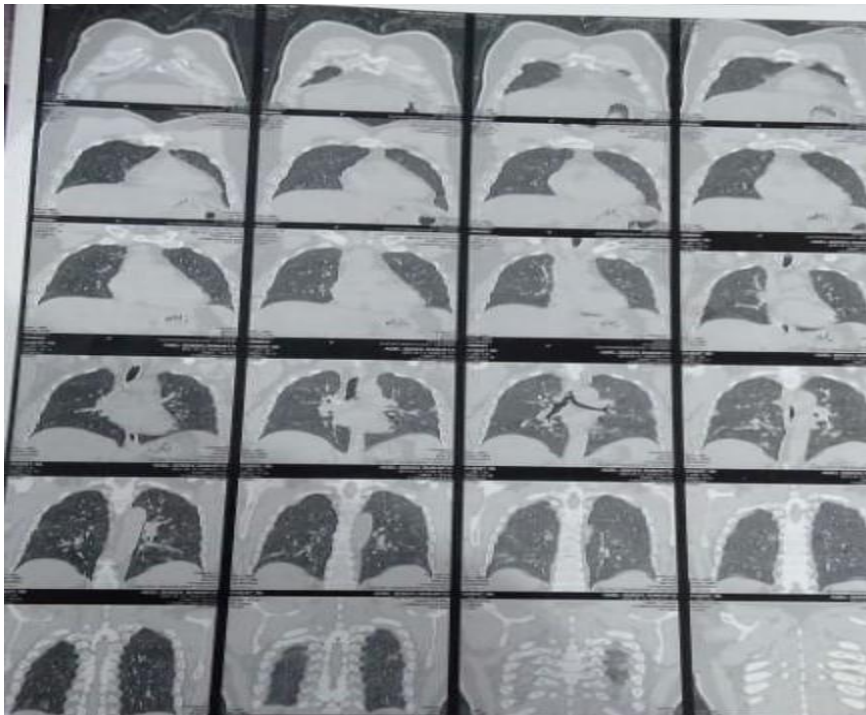

Figure 13: Suspected COVID-19 recovery rash on the neck

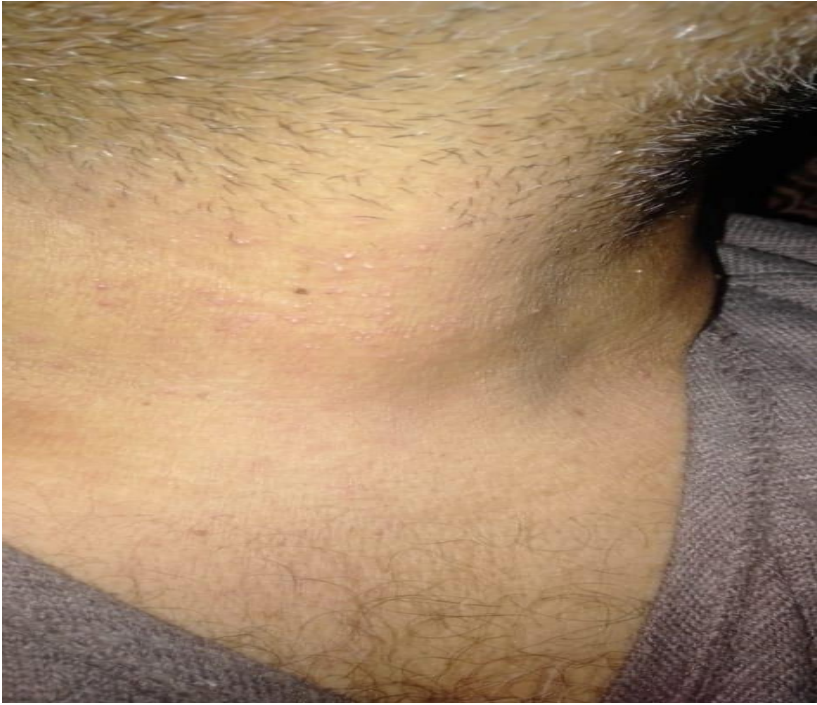


Figure 14: Suspected COVID-19 recovery rash on the back

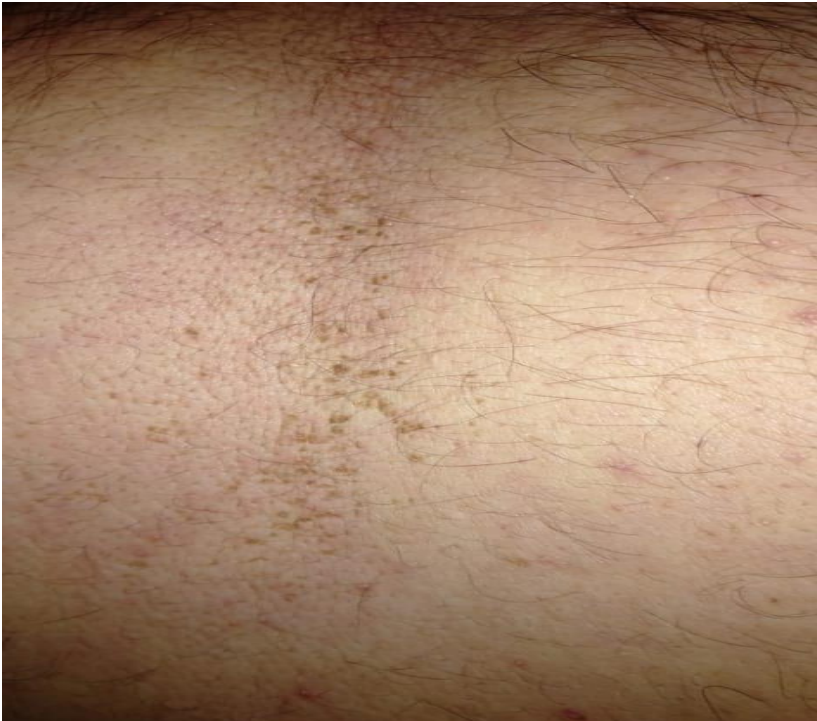


Figure 15: Pre-treatment CBC showing leucopenia

COMPLETE BLOOD COUNT

Red cell count	4.36	$10^6/\text{cmm}$	<u>Ref. range</u>
Haemoglobin	11.2*	g/dL	3.8 - 5.8
Haematocrit (PCV)	34.3	vol%	11.5 - 15.5
MCV	78.7*	fL	35 - 47
MCH	25.7*	pg	80 - 96
MCHC	32.7	%	27 - 32
Platelets count	193	$10^3/\text{cmm}$	30 - 35
White cell count	2.42*	$10^3/\text{cmm}$	150 - 450
			4 - 11

Differential white cell count

	<u>Relative</u>		<u>Absolute</u>	
	<u>Result %</u>	<u>Normal</u>	<u>Result /cmm</u>	<u>Normal</u>
Bands	0	0 - 6		
Segmented	38.5			
Neutrophils	38.5	20 - 80	932*	2000 - 7000
Lymphocytes	51.1*	20 - 45	1237	1000 - 4000
Monocytes	10.4*	1 - 10	252	200 - 800

Figure 16: Post-treatment CBC showing normal leucocytic count

HEMATOLOGY REPORT				
Blood Picture:			Reference Range :	
Hgb (Hemoglobin)	:	12.6	11.0 - 16.0 g/dL	
RBCs (Red Blood Cells)	:	4.39	$4.0 - 6.0 \times 10^3 \text{ Cells}/\mu\text{L}$	
Hct (Hematocrit)	:	38.5	35 - 50 %	
MCV	:	87.7	73 - 93 fL/cell	
MCH	:	28.7	27 - 34 pg/cell	
MCHC	:	32.7	29 - 40 g/dL	
Plt (Platelet)	:	207	$150 - 450 \times 10^3/\text{mm}^3$	
WBCs (Leukocytes)	:	5.30	$4.0 - 11.0 \times 10^3/\text{mm}^3$	
Test		Relative count %	Absolute count K/uL	
Neutrophil	:	44 40 - 75	2.33	1.5 - 7.0
Lymphocytes	:	45 20 - 45	2.38	1.0 - 3.7
Monocytes	:	9 2 - 10	0.48	0.0 - 0.7
Eosinophils	:	2 1 - 5	0.11	0.0 - 0.4
Basophils	:	0 0 - 1	0	0 - 0.1
Comment : RBCs show normal in size and shape, WBCs show no significant abnormality, PLTs show adequated in number and well aggregated				

Figure 17: Pre-treatment chest CT suggestive of COVID-19

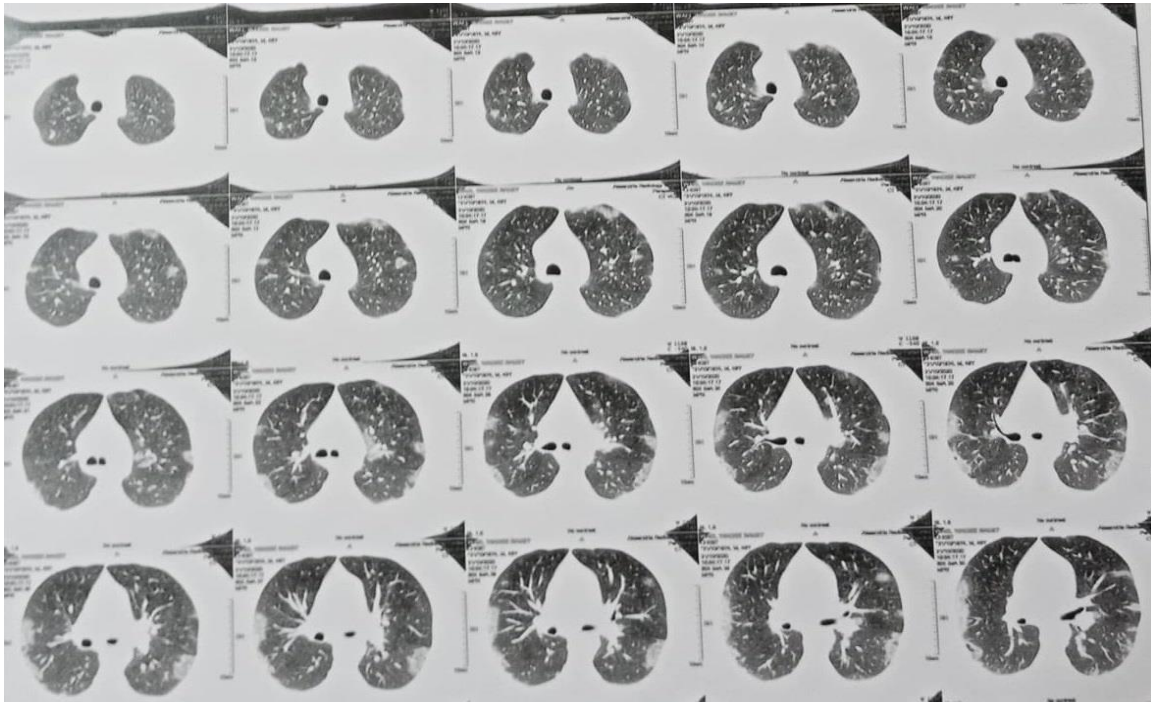


Figure 18: pre-treatment CBC showing a relative lymphocytic count of 30%

<u>COMPLETE BLOOD PICTURE</u>					
	Result	Unit	Ref. range for Male		
Haemoglobin	: 14.9	g/dl.	13 - 17		
R.B.Cs	: 5.40	$\times 10^6/\mu\text{L}$	4.5 - 5.9		
Haematocrit	: 46.0	%	40 - 52		
M.C.V.	: 85.2	fL	76 - 96		
M.C.H.	: 27.6	pg	27 - 32		
M.C.H.C.	: 32.4	g/dl.	32 - 37		
Platelets	: 301	$\times 10^3/\mu\text{L}$	150 - 400		
WBCs	: 6.6	$\times 10^3/\mu\text{L}$	4 - 11		
<u>Differential Leucocytic Count</u>					
			Reference Range	Results	Absolute values / μL Reference Range
Basophils	: 0	%	0 - 1	0	<110
Eosinophils	: 3	%	1 - 6	198	<600
Neutrophils	: 62.0	%	40 - 70	4,092	2,000 - 8,000
<i>staff</i>	: 2	%	0 - 5		
<i>Seg.</i>	: 60	%	40-70		
Lymphocytes	: 30	%	20 - 45	1,980	1,500 - 4,000
Monocytes	: 5	%	2 - 8	330	80 - 800
Comment	: Normal hemoglobin, red cell counts and morphology. Normal white cells count and morphology. Normal platelets count and morphology.				

Figure 19: post-treatment CBC showing a relative lymphocytic count of 47.9%

Complete Blood Picture					
Haemoglobin	14.7	g/dl			12.5 - 17.5
Haematocrit (PCV)	45.5	%			41 - 52
RBCs Count	5.18	Millions / cmm			4.5 - 5.9
MCV	87.8	fl			80 - 100
MCH	28.4	pg			27 - 33
MCHC	32.3	g/dl			31 - 37
RDW-CV	12.2	%			11.5 - 15
Platelet Count (EDTA Blood)	407	thousands / cmm			150 - 450
Total Leucocytic Count (EDTA Blood)	7.3	thousands / cmm			4 - 11
	<u>Percent Values</u>		<u>Absolute Values</u>		
Neutrophils	38.2	%	2.78	x10 ⁹ /L	2 - 7
Staff	4	%	0.29	x10 ⁹	
Segmented	34.2	%	2.50	x10 ⁹	
Lymphocytes	47.9	%	3.50	x10 ⁹ /L	1 - 4.8
Monocytes	10.7	%	0.78	x10 ⁹ /L	0.2 - 1
Eosinophils	2.7	%	0.20	x10 ⁹ /L	0.1 - 0.45
Basophils	0.5	%	0.04	x10 ⁹ /L	0 - 0.1
<u>Other Cells</u>					
Comment:					
RELATIVE LYMPHOCYTOSIS					
RELATIVE MONOCYTOSIS					
Follow up is recommended.					