

TITLE PAGE

- a) **Title:** Prolonged right ventricular outflow tract endocardial activation duration and presence of deceleration zones in patients with idiopathic premature ventricular contractions. Association with low voltage areas
- b) **List of authors:** Leonor Parreira MD^{1,2}, Pedro Carmo MD², Rita Marinheiro MD¹, Dinis Mesquita MD¹, José Farinha MD¹, Ana Esteves MD¹, Pedro Amador MD¹, António Ferreira MD², Marta Fonseca MD¹, Pedro Adragao PhD²
- c) **Institutions:**
- ¹ Setubal Hospital Centre, Cardiology Department, Setubal Portugal.
- ² Luz Hospital Lisbon, Cardiology Department, Lisbon Portugal.
- d) **Corresponding author and contact details**
- Leonor Parreira
- Address: Av Dr António Rodrigues Manito, 114 2900-064 Setubal Portugal
- Email: leonor.parreira@gmail.com
- e) **No financial support**
- f) **No conflicts of interest**

STRUCTURED ABSTRACT

Background and aims: Activation wavefront is rapid and uniform in normal myocardium. Fibrosis is associated with deceleration zones (DZ) and late activated zones. Our aim was to study the right ventricular outflow tract (RVOT) endocardial activation duration (EAD) in sinus rhythm, and assess the presence of DZs, in patients with PVCs and controls.

Methods: We studied 29 patients with idiopathic PVCs from the outflow tract, subjected to catheter ablation and an activation and voltage map of the RVOT in sinus rhythm. A control group of 15 patients without PVCs that underwent ablation of supraventricular arrhythmias was also studied. The RVOT EAD and number of 10 ms isochrones were assessed. DZ were defined as a zone with >3 isochrones within 1 cm radius. Low voltage areas (LVA) defined as areas with local electrogram amplitude <1.5 mV.

Results: The two groups did not differ in relation to age, gender or number of points in the map. EAD and number of 10 ms isochrones were higher in the PVC group; 56 (41-66) ms vs 39 (35-41) ms, $p=0.001$ and 5 (4-8) vs 4 (4-5), $p=0.001$. Presence of DZs and LVAs were more frequent in the PVC group; 20 (69%) vs 0 (0%), $p<0.0001$ and 21 (72%) vs 0 (0%), $p<0.0001$. Patients with LVAs had longer EAD 60 (52-67) vs 36 (32-40) ms, $p<0.0001$ and more DZ than patients without LVA 95% vs 0%, $p<0.0001$.

Conclusions: EAD was longer and DZs were more frequent in patients with PVCs and were associated with presence of LVAs.

KEYWORDS

Premature ventricular contractions; Right ventricular outflow tract; Idiopathic; Low voltage areas; Deceleration zones; Endocardial activation duration; Voltage mapping; Isochronal mapping; Catheter ablation

MAIN ARTICLE

1. INTRODUCTION

It is usually accepted that PVCs from the outflow tracts result from triggered activity and occur in structurally normal hearts [1]. Most studies with cardiac magnetic resonance (CMR) have failed to demonstrate the presence of structural abnormalities. Still, studies with intracardiac mapping have shown the presence of low voltage areas (LVA) [2-7]. Whether these LVAs correspond to a form of incipient manifestation of a disease of the RVOT remains unproved. Also, it was previously pointed out that patients with frequent PVCs had worse RV global longitudinal strain values (and therefore sub-clinical myocardial dysfunction) than healthy controls patients with structurally apparent normal hearts, irrespective of the absence of abnormalities on the CMR [8]. The activation wavefront is rapid and uniform in normal myocardium. Fibrosis is associated with late local activation and areas of slow conduction and slower wavefront propagation speed, known as deceleration zones (DZ) [9,10]. It has been previously observed that the velocity of the wavefront propagation of the PVC across the RVOT is slower in patients with PVCs from the RVOT than from the left ventricular outflow tract (LVOT), but the authors attributed this finding to the presence of differences in myocardial fiber orientation [11,12]. However, this finding might be due to subtle disease of the RVOT manifested by the presence of LVAs. Based on previous studies it has become clear that activation delay is a hallmark of arrhythmogenic right ventricular cardiomyopathy (ARVC) [13].

The aim of this study was to assess the pattern of propagation of the endocardial activation in RVOT looking for the presence of DZs in patients with PVCs and in controls and evaluate the association with the presence of LVAs.

2. METHODS

2.1. Study population

From July 2019 to December 2020, we prospectively studied consecutive patients with symptomatic idiopathic frequent PVCs (>10000/24h) with a LBBB or RBBB, vertical axis, negative polarity in lead aVL, that were referred for catheter ablation by the same operator. Independently of the site of origin

of the arrhythmia all patients had an electroanatomical activation and voltage map of the RVOT obtained in sinus rhythm. This study was carried out in two hospitals. All patients underwent transthoracic echocardiography, including 2-dimensional, M-mode, and Doppler study and 12-lead electrocardiogram (ECG). All patients in the PVC group had a CMR with late gadolinium enhancement (LGE) to exclude the presence of structural heart disease.

Arrhythmogenic right ventricular cardiomyopathy was ruled out according to the Task Force Criteria [14]. A 24-Hour Holter recording was performed before ablation and the number of PVCs per 24 hours and the presence of episodes of non-sustained ventricular tachycardia (NSVT), defined as >3 PVCs in a run were assessed. Patients with evidence of structural heart disease, conduction delays, electrical diseases or abnormal QRS morphology, as well as patients with previous ablation were excluded.

A control group of consecutive patients without PVCs, that underwent catheter ablation of supraventricular tachycardias since 2019 and agreed to have an electroanatomical map of the RVOT obtained in sinus rhythm was also studied.

2.2. Study Design

We assessed the duration of the endocardial activation (EAD) on the RVOT in sinus rhythm as well as the presence of DZ in patients with PVCs and in controls. The presence of low voltage areas (LVAs) in sinus rhythm was also assessed. We tested for the association between the EAD and DZs and the presence of LVAs.

2.3. Electroanatomic mapping and ablation

Patients were studied in a fasting non sedate state. All beta-blockers and antiarrhythmic drugs were discontinued at least five half-lives before the electrophysiological study. Diagnostic catheters were positioned via the femoral vein with fluoroscopic guidance in the His position and in the great cardiac vein via the coronary sinus. During endocardial mapping of the LVOT heparin was administered to achieve an ACT of 250-300 sec. After the completion of the sinus rhythm map, isoprenaline was administered intravenously, as needed, and titrated to a dose capable of inducing PVCs.

All patients underwent electroanatomical mapping with CARTO 3 (Biosense-Webster) or EnSite Precision (Abbott). With the former, all procedures were performed using the Niobe magnetic navigation system (Stereotaxis) working with the monoplane fluoroscopy system AXIOM Artis (Siemens) as previously described [15]. An irrigated tip Navistar RMT Thermocool catheter (Biosense-Webster) was used with a 3.5-mm distal tip electrode and a 2-5-2 interelectrode distance. With the EnSite Precision system all procedures were done manually with the monoplane fluoroscopy system BV Pulsera (Philips) and using an irrigated tip FlexAbility catheter (Abbott) with a 4-mm distal tip electrode and a 1-4-1 interelectrode distance. The ablation catheter was introduced via the femoral vein, manually advanced to the right atrium and then automatically advanced to the His bundle and RVOT in the magnetic navigation system patients or manually in the EnSite patients, under fluoroscopic guidance. The ablation catheter was then placed at multiple sites on the endocardial surface of the RVOT. The 12-lead surface ECGs and intracardiac electrograms were recorded simultaneously by a digital multichannel system, filtered at 30–300 Hz for bipolar electrograms and at 0.05–525 Hz for unipolar electrograms, displayed at 100 mm/s speed. During sinus rhythm two maps were created, activation and voltage map and during PVC, activation map.

All the intracardiac electrograms were reviewed by two senior electrophysiologists.

2.3.1. Sinus rhythm activation and voltage map

The sinus rhythm maps were obtained without isoprenaline. With the Carto system, local activation time (LAT) was defined as the time of the maximum downslope of the unipolar distal electrogram displayed on the corresponding bipolar signal. With the Ensite system LAT was defined as the time of the first peak of the bipolar electrogram [16]. Total RVOT EAD was measured as the time interval from the earliest RVOT endocardial activation to the latest RVOT endocardial activation recorded during sinus rhythm. The geometry of the RVOT depicting the LAT recorded was constructed in real time with the electrophysiological information colour coded and superimposed on the reconstruction. The data derived from the isochronal map and analysis were obtained offline, and therefore, the procedure results were not dependent on these data. Activation isochronal maps were displayed as 10

ms isochrones, those maps were generated automatically with the Carto3 system. In the case of Ensite Precision the RVOT isochronal map was always displayed as eight 10 ms isochrones, considering the earliest isochrone the one encompassing the first 10 ms of activation time in the RVOT, and the last isochrone covering the latest activation time above 80 ms. Six other 10 ms isochrones were considered for LAT between those two extreme values. The total number of 10 ms isochrones across the RVOT was measured as well as the maximum number of 10 ms isochrones per 1cm radius [10]. Zones with slower wavefront propagation speed, known as DZs were defined as zones with >3 isochrones within 1 cm radius.

The electrograms were also analysed in regard of their amplitude and the information was used to generate a 3-dimensional electroanatomical voltage map of the RVOT, with the electrophysiologic information, colour-coded and superimposed on the geometry. The colour display for voltage mapping ranged from purple, representing electroanatomical normal tissue (amplitude ≥ 1.5 mV), to red, representing electroanatomical scar tissue (amplitude <0.5 mV). LVAs were defined as areas with bipolar electrograms with an amplitude <1.5 mV. The level of RVOT/pulmonary valve junction was thoroughly determined based on electroanatomical voltage mapping by passing the catheter into the pulmonary artery and slowly withdrawing it to the RVOT. The voltage above the pulmonary valve is usually less than 0.5 mV. The area immediately below the level of the pulmonary valve displays intermediate colours, corresponding to a bipolar voltage between 0.5 mV a 1.5 mV, defined as the transitional-voltage zone [2]. Presence of LVAs outside the transitional-voltage zone, were assessed. The sinus rhythm maps were obtained in patients with PVCs and in patients from the control group.

2.3.2. PVC activation map and ablation

The activation map was created by mapping several points during each PVCs while using a surface ECG lead as reference. The ablation site was selected based on the earliest endocardial activation time in relation to the onset of the surface QRS, with a QS pattern at the unipolar electrogram and confirmed by the pace mapping that provided at least 11 out of 12 pace matches between paced and spontaneous PVCs. Energy was delivered from an EP Shuttle RF generator (Stockert) between the distal electrode

of the ablation catheter and a cutaneous patch, for up to 120 seconds, to a maximum temperature of 43°C and a power output limit of 50 W. When the application was ineffective, additional applications were delivered to sites adjacent to the earliest activation site. During ablation, light sedation with midazolam (bolus) or remifentanyl (continuous perfusion) was administered when needed. Success was defined as abolition of PVCs under isoprenaline infusion until thirty minutes after ablation.

2.1. Statistical analysis

All analyses were performed using SPSS statistical software, version 26.0 (SPSS, Inc, Chicago, Illinois). Data is presented as median and lower and upper quartile (Q₁-Q₃) for continuous variables, as median and minimum and maximum (min-max) for ordinal variables and as absolute numbers and percentages for binary variables. Continuous variables and ordinal variables were compared with the use of Mann Whitney test for independent samples. Categorical variables were compared with the use of two-side Fischer's exact-test or the chi square test as appropriate for independent samples. The ROC curve was used to assess the cut point value of EAD that ensures the presence of LVS and its specificity and sensitivity based on 2x2 contingency table and chi square test. For all tests a two-tailed p value <0.05 was considered as statistically significant.

2.2. Ethics

All patients signed the informed consent form, and the study was approved by the Ethical Committee of both hospitals. The study is in compliance with the Helsinki Declaration.

3. RESULTS

2.1. Study population

44 patients were enrolled, 29 patients in the PVC group and 15 patients in the control group of whom, twelve underwent ablation of atrioventricular nodal reentrant tachycardia, one of atrioventricular reentrant tachycardia and two of typical atrial flutter. Physical examination, 12-lead ECG and transthoracic echocardiography were normal. Both groups did not differ in relation to age, gender, or other clinical, standard electrocardiographic and echocardiographic parameters (Table 1). PVCs

originated in the RVOT in 23 patients and in the LVOT in six. In the PVC group, all patients were symptomatic, all complained of palpitations and one patient had one syncopal episode typically vagal in nature. No patient had family history of sudden death. The 24-hour Holter recording showed a high PVC burden with a median of 21164 (15000-28750) PVCs/24 hours and presence of NSVT in 11 patients (38%). The CMR did not show evidence of RVOT abnormalities in any patient.

2.2. Electroanatomic mapping and ablation

2.2.1. Activation and voltage map in sinus rhythm

The sinus rhythm electroanatomical mapping was successfully acquired in all patients, the median number of points per patient, collected in the RVOT to obtain the map was 387 (340-506) and was not significantly different between patients with PVCs and the control group, respectively 412 (343-533) versus 345 (339-450), $p=0.193$ (Table 2). The earliest RVOT endocardial activation occurred anteriorly in the free wall, while the latest endocardial activation was observed at the sub-pulmonary valve areas in all cases. The median EAD, the median number of 10 ms isochrones and the maximum number of 10 ms isochrones per 1 cm radius was significantly higher in the PVC group than in the control group, respectively, 56 (41-66) versus 39 (35-41) ms, $p=0.001$; 5 (4-8) versus 4 (4-5), $p=0.001$; 4 (3-6) versus 3 (3-3), $p<0.0001$ (Table 2). DZs were present in 20 patients (69%) and LVAs in 21 patients (72%) in the PVC group, but both were absent in control subjects, $p<0.0001$. (Figure 1).

2.2.2. Association between duration of endocardial activation in the RVOT and presence of LVAs in patients with PVCs

In the PVC group, the presence of LVAs was more frequent in patients with PVCs from the RVOT than in patients with PVCs from the left side, 83% versus 33%, $p=0.033$.

The longer the EAD the higher the likelihood of displaying LVAs in the RVOT. According to the ROC curve the cut point value is above 42 ms, with a sensitivity and specificity of 100%, $p<0.0001$. All patients with LVAs had EADs above 42 ms (Figure 2), they also displayed a higher number of 10 ms isochrones across the RVOT and maximum number of 10 ms isochrones per 1 cm radius (Table 3). In twenty out of twenty-one (95%) was possible to identify the presence of DZs that were absent in all

patients without LVAs, $p < 0.0001$ DZs occurred in areas of normal voltage in just two patient (10%) Figure 3.

2.2.3. PVC activation map and ablation

In the PVC group the electroanatomical mapping was performed with Carto 3 in 11 patients and with Ensite Precision in 18 patients. The earliest activation site was located in the RVOT septum in 15 patients, the RVOT free wall in 8 patients, the left coronary cusp in two, the LVOT in three and the LV summit in one. The access to the LVOT was obtained by retrograde transaortic approach in all six patients. The earliest activation site was located within the LVAs in 15 (52%) patients and in 10 (35%) patients was located in a DZ. In patients with DZ, this percentage increased to 50% (Figure 4 and 5). At the earliest activation site, the precocity of the LAT in relation to the onset of the surface QRS was -41 (-33- (-51)) ms. The median procedure time, fluoroscopy time and RF time were respectively, 120 (90-130) minutes, 6 (4-11) minutes and 440 (223-648) seconds. The comparison between patients with DZ and patients without DZ is presented in Table 4. Success was achieved in 25 patients (86%) and was not associated with the presence of LVAs or DZs.

4. DISCUSSION

The first important finding of this study was the demonstration of a lower velocity of propagation of the wavefront of activation over the endocardium of the RVOT in patients with PVCs in comparison with the control subjects. To the best of our knowledge this is the first report assessing the propagation of the wavefront of endocardial activation in sinus rhythm in patients with PVCs from the RVOT in comparison with a control group without PVCs. Masuda et al studied the velocity of propagation of the PVC in a group of 23 patients with idiopathic arrhythmias from the outflow tracts [12]. Mapping of the RVOT during the PVC was performed using an ultra-high resolution electroanatomic mapping system. The wavefront propagation speed of the PVC over the RVOT was slower for PVCs originating from the RVOT than for PVCs originating from adjacent sites. The authors used this information to differentiate arrhythmias originating from the RVOT from the non-RVOT arrhythmias as previously

described by Herczku et al using a conventional mapping catheter in a point-by-point manner [11]. Both groups explained their findings based on the myocardial fiber arrangement in the RVOT that leads to a different propagation speed according to the site of origin of the arrhythmia. Therefore, when the PVC originates in the LVOT it reaches the RVOT through multiple connections and the activation becomes faster in this case.

On the contrary, we believe that this slower conduction is related to the presence of a pathological substrate in the RVOT rather than a difference in the connections between the origin of the arrhythmia and the RVOT. In fact, in our study group the presence of a longer EAD was significantly associated with the presence of LVAs. Previous studies have shown the presence of LVAs in the RVOT of patients undergoing catheter ablation of frequent PVCs despite normal CMR [2-7]. The presence of LVAs did not match the results of the CMR in any of the studies. These findings may suggest the presence of an underlying substrate too subtle to be identified by CMR techniques. In fact, the type of interstitial fibrosis that occurs in the initial phases of ARVC is not reliably detected with CMR with LGE [17]. These LVAs are located at the site of origin of the arrhythmia in most cases and have been suggested as a target for ablation in case of low PVC burden during the procedure [7,18]. Using two-dimensional speckle tracking echocardiography (2D-STE) Fonseca et al [8], in a previous study have demonstrated that the right ventricle global longitudinal strain was significantly lower in patients with RVOT PVCs when compared with a control group, irrespective of the previous PVCs burden and success of the catheter ablation procedure. Concerning strain values determined by CMR, Zghaib et al [19] have previously demonstrated, in ARVC patients, that lower regional strain could identify low voltage areas on endocardial and epicardial electroanatomical mapping and had a better correlation with VT substrate than late gadolinium enhancement sites. These subtle morphological abnormalities may be the cause for the abnormal wavefront propagation observed in our population.

In our group of patients, although the EAD was significantly longer in the PVC group than in controls, it was nevertheless still within the normal range previously described by other authors [13,20]. Tandri et al studied a group of 25 patients with frequent left bundle branch block morphology premature ventricular complexes, 14 with ARVC and 11 with idiopathic PVCs [13]. The authors evaluated the

total right ventricular (RV) endocardial activation duration and observed that an EAD higher than 65 ms was highly suggestive of ARVD and was never present in patients with idiopathic PVCs. The authors concluded that total RV EAD was a more sensible and earlier marker of disease than low voltage [13]. Letsas et al, performed a high-density map of the RVOT in 8 patients with Brugada Syndrome and 20 patients with idiopathic PVCs. The mean RVOT endocardial activation time was significantly prolonged in patients with Brugada Syndrome in comparison with patients with idiopathic arrhythmias, 86.4 ± 16.5 vs. 63.4 ± 9.7 ms, $p < 0.001$ [20]. None of the above-mentioned authors have studied a population of normal subjects without PVCs, thus the value of 65 ms and 63.4 ms reported as control might as well be augmented in relation to people without PVCs.

In a previous work using non-invasive mapping we observed the presence of abnormal electrophysiological characteristics in the RVOT in a group of seven patients with PVCs from the RVOT when compared with a control group [21]. Although we could not demonstrate the presence of an activation delay, we found the presence of a higher dispersion of the activation recovery interval across the epicardium of the RVOT in patients with PVCs when compared to normal controls. suggesting once again the presence of an underlying substrate [21].

The second important finding was the presence of DZs in the RVOT in patients with PVCs that were absent in the control group. They were associated with the presence of LVAs and were absent in patients without LVAs. However, in 10 % of cases they occurred outside the LVAs and this was also described by Tandri et al [13] that observed that the presence of delayed activated areas was not always associated with decreased endocardial voltage and/or fractionated potentials. Even in the case of patients with structural heart disease as described by Aziz et al [10], DZ were also present in normal voltage zones. Voltage mapping is dependent on contact force, electrode area and orientation of the catheter tip in relation to the direction of the wavefront activation and so may be less accurate to evaluate substrate, whereas activation mapping is less dependent on these parameters. Nevertheless, even the latter is dependent on the methodology of LAT annotation and may be influenced by the presence of low amplitude pre-potentials, presence of multiple components or fractionated electrograms [22]. So, it is

difficult to support that the activation delay represented by DZs was secondary to local fibrosis, although very subtle interstitial fibrosis cannot be completely excluded.

Finally, the earliest activation site was found to be located outside the DZ and LVAs in half the patients. Thus, it is difficult to accept that the DZ and LVAs are the origin of the PVCs but may rather represent the result of the electric remodeling triggered by the frequent PVCs. The median PVC burden in our group was 21164 PVC/24 hours PVC. Higher PVC burden can be associated with an excess mortality in idiopathic patients [23], and a burden over 20.000 PVCs /24 hours is associated with a higher risk of PVC-related cardiomyopathy [24]. So, it remains to be demonstrated if the delayed activation and presence of DZs may denote the presence of a subtle substrate for the PVCs or the electrical and anatomical remodeling as a consequence of the high PVC burden. One way or the other, those patients should continue to be closely followed after ablation to evaluate the evolution of the disease.

5. LIMITATIONS

Two mapping systems were used with different annotation methodologies. However, assuming that the methodology is consistent for all mapping points acquired in each case, the activation duration and the presence of DZ representing intervals rather than absolute values are perfectly comparable. Thus, although the minimal and maximal absolute values may be different between systems in absolute terms, the EAD and 10 ms isochrones are independent of the annotation methodology.

Another limitation is the definition of DZs as more than three isochrones per 1 cm radius. This value was based on previous studies in patients with structural heart disease and may underestimate the presence of slow conduction in patients with idiopathic PVCs. However, in our group none of the normal subjects had less than three isochrones per 1 cm radius so considering abnormal a number above three seems adequate.

Finally, it would be interesting to investigate whether these abnormalities persist after ablation of the PVCs however, using invasive electroanatomical mapping to achieve that goal would be ethical unacceptable, leaving space for other techniques like for instance noninvasive mapping, echocardiographic longitudinal strain and cardiac magnetic resonance

6. CONCLUSIONS

Patients with PVCs display a slower wavefront propagation of the activation across the RVOT in sinus rhythm than controls. Deceleration zones are present exclusively in patients with PVCs and occur mostly at LVAs. However, only half the patients present the SOO of the PVCs in those zones.

7. ACKNOWLEDGEMENTS

The authors are grateful to Catalin Marinescu, Joana Pinho and Lia Marques for the Carto and Ensite images, and to Silvia Nunes and Duarte Chambel for their help in collecting data.

8. REFERENCES

1. Lerman B. Outflow tract ventricular arrhythmias: An update. *Trends Cardiovasc Med.* 2015; 25: 550–558.
2. Yamashina Y, Yagi T, Namekawa A, et al. Distribution of successful ablation sites of idiopathic right ventricular outflow tract tachycardia. *Pacing Clin Electrophysiol.* 2009; 32:727-733.
3. Furushima H, Chinushi M, Iijima K, et al. Relationship between electroanatomical voltage mapping characteristics and break-out site of ventricular activation in idiopathic ventricular tachyarrhythmia originating from the right ventricular out-flow tract septum. *J Interv Card Electrophysiol.* 2012; 33:135-41
4. Parreira L, Marinho R, Carmo P, et al. Premature ventricular contractions of the right ventricular outflow tract: Upward displacement of the ECG unmasks ST elevation in V1 associated with the presence of low voltage areas. *Rev Port Cardiol.* 2019;38:83-91
5. Parreira L, Marinho R, Carmo P, et al. Isolated diastolic potentials as predictors of success in ablation of right ventricular outflow tract idiopathic premature ventricular contractions. *PLoS ONE* 2019;14:e0211232. <https://doi.org/10.1371/journal.pone.0211232>
6. Parreira L, Marinho R, Carmo P, et al. Idiopathic Premature Ventricular Contractions From the Outflow Tract Display an Underlying Substrate That Can Be Unmasked by a Type 2 Brugada Electrocardiographic Pattern at High Right Precordial Leads. *Front. Physiol.*, 07 August 2020 doi.org/10.3389/fphys.2020.00969

7. Letsas K, Efremidis M, Vlachos K, et al. Right ventricular outflow tract low-voltage areas identify the site of origin of idiopathic ventricular arrhythmias: A high-density mapping study. *J Cardiovasc Electrophysiol.* 2019; 30:2362-2369
8. Ferreira Fonseca M, Parreira L, Lopes A, et al. Right ventricular outflow tract premature ventricular contractions: is there an incipient underlying disease? An echocardiographic strain analysis. *Europace* 2019;21 (Supp2): ii163. doi.org/10.1093/europace/euz093
9. Raiman M, Tung R. *Computers in Biology and Medicine* 2018. 102:336-340.
10. Aziz Z, Shatz D, Raiman M, et al. Targeted Ablation of Ventricular Tachycardia Guided by Wavefront Discontinuities During Sinus Rhythm A New Functional Substrate Mapping Strategy. *Circulation.* 2019; 140:1383–1397.
11. Herczku C, Berruezo A, Andreu D, et al. Mapping Data Predictors of a Left Ventricular Outflow Tract Origin of Idiopathic Ventricular Tachycardia With V3 Transition and Septal Earliest Activation. *Circ Arrhythm Electrophysiol.* 2012;5:484-491.
12. Masuda M, Asai M, Iida O, et al. Centrifugal Wave Front Propagation Speed for Localizing the Origin of Ventricular Arrhythmias. Investigation Using a New Ultra-High-Resolution Mapping System. *J Am Coll Cardiol EP* 2018;4:355–63
13. Tandri H, Asimaki A, Abraham T, et al. Prolonged RV endocardial activation duration: A novel marker of arrhythmogenic right ventricular dysplasia/cardiomyopathy. *Heart Rhythm* 2009; 6:769–775
14. Marcus F, McKenna W, Sherrill D, et al. Diagnosis of arrhythmogenic right ventricular cardiomyopathy/dysplasia: proposed modification of the Task Force Criteria. *Eur Heart J.* 2010; 31:806–814
15. Parreira L, Cavaco D, Reis-Santos K, et al. Remote magnetic navigation for mapping and ablation of right and left ventricular outflow tract arrhythmias. *Rev Port Cardiol.* 2013; 32:489–95.
16. Kim Y-H, Chen S-A, Sabine E, et al. 2019 APHRS expert consensus statement on three-dimensional mapping systems for tachycardia developed in collaboration with HRS, EHRA, and LAHRS. *Journal of Arrhythmia* 2020;36:215–270.

17. Puntmann V, Peker E, Chandrashekar Y, Nagel E. T1 Mapping in Characterizing Myocardial Disease a Comprehensive Review. *Circ Res.* 2016; 119: 277-299
18. Wang Z, Zhang H, Peng H, et al. Voltage combined with pace mapping is simple and effective for ablation of noninducible premature ventricular contractions originating from the right ventricular outflow tract. *Clinical Cardiology* 2016; 39: 733–738
19. Zghaib T, Ghasabeh M, Assis F, et al. Regional Strain by Cardiac Magnetic Resonance Imaging Improves Detection of Right Ventricular Scar Compared With Late Gadolinium Enhancement on a Multimodality Scar Evaluation in Patients With Arrhythmogenic Right Ventricular Cardiomyopathy *Circ Cardiovasc Imaging.* 2018;11:e007546. DOI: 10.1161/CIRCIMAGING.118.007546
20. Letsas K, Efremidis K, Vlachos K, et al. Right ventricular outflow tract high-density endocardial unipolar voltage mapping in patients with Brugada syndrome: evidence for electroanatomical abnormalities. *Europace* 2018; 20, f57–f63
21. Parreira L, Carmo P, Adragão P, et al. Non-invasive electrocardiographic imaging in patients with idiopathic premature ventricular contractions from the right ventricular outflow tract: New insights into arrhythmia substrate. *Journal of Electrocardiology* 2019; 57: 69–76
22. Saba M, Li A. Mapping and Ablation of Ventricular Outflow Tract Arrhythmias. *Card Electrophysiol Clin* 2019;11:597–607
23. Parreira L, Marinheiro R, Amador P, et al. Frequent premature ventricular contractions. Association of burden and complexity with prognosis according to the presence of structural heart disease. *Ann. Noninvasive Electrocardiol.* 2021;26:e12800. doi.org/10.1111/anec.12800
24. Nielsen J, Lin Y-J, Figueiredo M, et al. European Heart Rhythm Association (EHRA)/Heart Rhythm Society (HRS)/Asia Pacific Heart Rhythm Society (APHRS)/Latin American Heart Rhythm Society (LAHRS) expert consensus on risk assessment in cardiac arrhythmias: use the right tool for the right outcome, in the right population. *Europace* 2020; 22: 1147–1148

9. TABLES

Table 1. Baseline characteristics and comparison between PVC group and control group

	Overall sample (n=42)	PVC group (n=29)	Control group (n=15)	P value
Demographic data				
Age in years, median (Q ₁ -Q ₃)	53 (35-65)	51(37-65)	56 (28-66)	0.710
Male Gender, n (%)	20 (46)	14 (48)	6 (40)	0.752
Body surface area in m ² , median (Q ₁ -Q ₃)	1.81 (1.59-1.92)	1.79 (1.57-1.95)	1.82 (1.60-1.95)	0.757
Risk factors and medications				
Hypertension, n (%)	17 (39)	10 (35)	7 (47)	0.521
Diabetes, n (%)	8 (18)	6 (21)	2 (13)	0.695
Betablockers, n (%)	25 (58)	18 (62)	7 (50)	0.521
Antiarrhythmic drugs, n (%)	9 (21)	8 (28)	1 (7)	0.231
12 lead ECG				
QRS duration in ms, median (Q1-Q3)	87 (80-90)	89 (80-90)	83(80-90)	0.288
T wave inversion beyond V1, n (%)	0 (0)	0 (0)	0 (0)	
24-Hour Holter Monitoring*				
Number of PVCs, median (Q1-Q3) *	-	21164 (15000-28750)		
NSVT, n (%)*	-	11 (38)		
Echocardiogram				
LVEF in %, median (Q ₁ -Q ₃)	58 (56-59)	57 (56-60)	58 (57-59)	0.416
LAD in mm, median (Q ₁ -Q ₃)	35 (30-40)	37 (30-41)	33 (31-41)	0.121

* in the PVC group; LAD: left atrial diameter in parasternal view; LVEF: left ventricular ejection fraction; NSVT: non sustained ventricular tachycardia; PVC: premature ventricular contractions

Table 2. Sinus rhythm activation and voltage mapping data

	Overall sample (n=44)	PVC group (n=29)	Control group (n=15)	P value
Number of points in the map, median (Q ₁ -Q ₃)	387 (340-506)	412 (343-533)	345 (339-459)	0.193
EAD, median ((Q ₁ -Q ₃))	42 (37-60)	56 (41-66)	39 (35-41)	0.001
N° of 10 ms isochrones in the RVOT, median (min-max)	5(4-8)	5 (4-8)	4 (4-5)	0.001
Max. n° of 10 ms isochrones per 1 cm radius, median (min-max)	3 (3-6)	4 (3-6)	3 (3-3)	<0.0001
Presence of DZs, n (%)	20 (46)	20 (69)	0 (0)	<0.0001
Presence of LVAs, n (%)	21 (48)	21 (72)	0 (0)	<0.0001

EAD: endocardial activation duration; DZ: deceleration zone; RVOT: right ventricular outflow tract;

LVA: low voltage area; PVC: premature ventricular contractions

Table 3. Sinus rhythm activation data in the PVC group according to the presence of LVAs

	Overall PVC Group (n=29)	With LVAs (n=21)	Without LVAs (n=8)	P value
Number of points in the map, median (Q ₁ -Q ₃)	412 (343-533)	465 (366-533)	313 (214-544)	0.083
EAS in the RVOT, n (%)	23 (79)	19 (91)	4 (50)	0.033
EAD, median ((Q ₁ -Q ₃)	56 (41-66)	60 (52-67)	36 (32-40)	<0.0001
N° of 10 ms isochrones in the RVOT, median (min-max)	5 (4-8)	6 (5-8)	4 (4-5)	<0.0001
Max. n° of 10 ms isochrones per 1 cm radius, median (min-max)	4 (3-6)	4 (3-6)	3 (3-3)	<0.0001
Presence of DZ, n (%)	20 (69)	20 (95)	0 (0)	<0.0001

EAD: endocardial activation duration; EAS: earliest activation site; DZ: deceleration zone; LVA: low

voltage area; RVOT: right ventricular outflow tract; PVC: premature ventricular contractions

Table 4. Activation mapping during PVCs and ablation data according to the presence of DZs*

	PVC group (n=29)	With DZ (n= 20)	Without DZ (n=9)	p-value
Carto/Ensite, n (%) / n (%)	11 (38) /18 (62)	7 (35)/13 (65)	4 (44)/5 (56)	0.694
PVCs from RVOT/LVOT, n (%) / n (%)	23 (79) /6 (21)	18 (90)/2 (10)	4 (44)/5 (56)	0.056
Presence of LVAs	21 (72)	20 (100)	1 (11)	<0.0001
EAS in LVAs, n (%)	15 (52)	14 (70)	1 (11)	0.005
LAT at the EAS in ms, median (Q ₁ -Q ₃)	-41 (-33-(-51))	-42 (-35-(-50))	-37 (-31-(-53))	0.900
Procedure time in min, median (Q ₁ -Q ₃)	120 (90-130)	120 (88-145)	120 (90-125)	0.934
Fluoroscopy time in min, median (Q ₁ -Q ₃)	6 (4-11)	5 (4-10)	8 (4-12)	0.637
RF time in min, median (Q ₁ -Q ₃)	440 (223-648)	430 (270-612)	565 (157-690)	0.760
Success, n (%)	25 (86)	17 (85)	8 (89)	1.000

EAS: earliest activation site; DZ: deceleration zone; LAT: local activation time; LVA: low voltage area;

LVOT: left ventricular outflow tract; RF: radiofrequency; RVOT: right ventricular outflow tract; PVC:

premature ventricular contractions

10. FIGURES

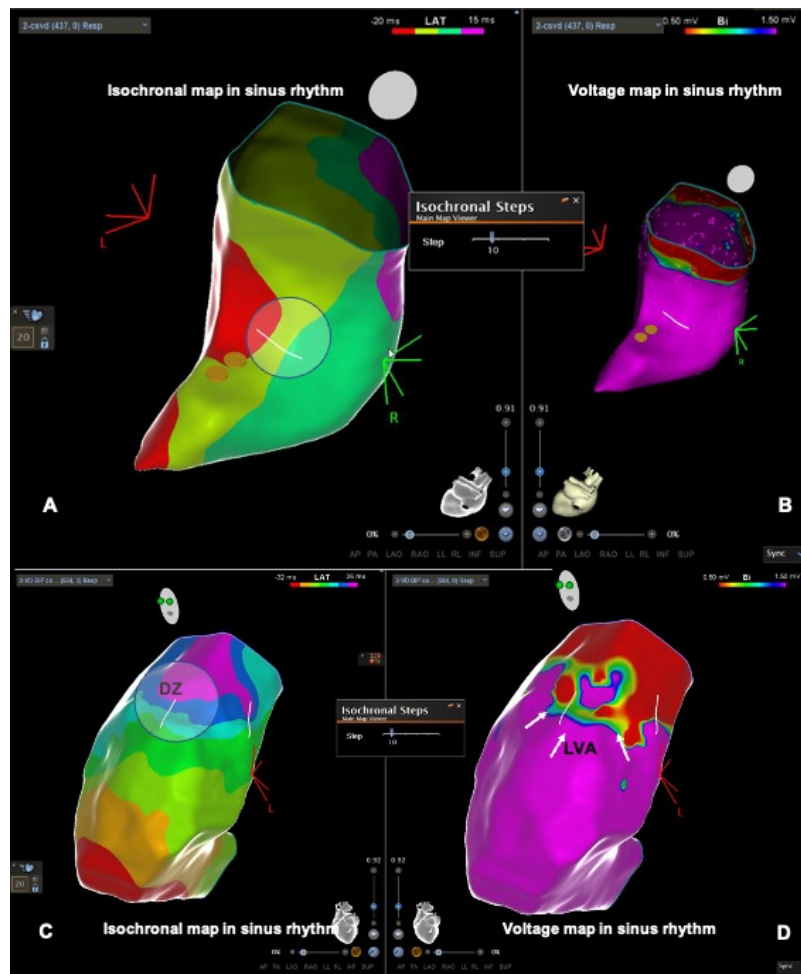


Figure 1. RVOT activation and voltage maps in sinus rhythm. Superior panels: patient from the control group without DZs (A) or LVAs (B). Inferior panels: patient from the PVC group with DZ in the RVOT free wall (C) and LVA at the same location (D). DZ: deceleration zone; LVA: low voltage area; RVOT: right ventricular outflow tract

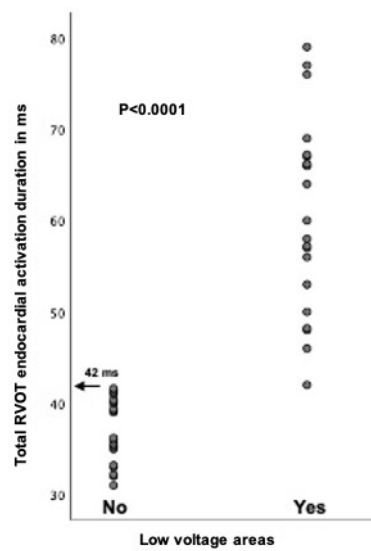


Figure 2. Total RVOT endocardial activation time is significantly higher in patients with LVAs. None of the patients without LVAs had EAD longer than 42 ms (arrow). LVA: low voltage area; RVOT: right ventricular outflow tract

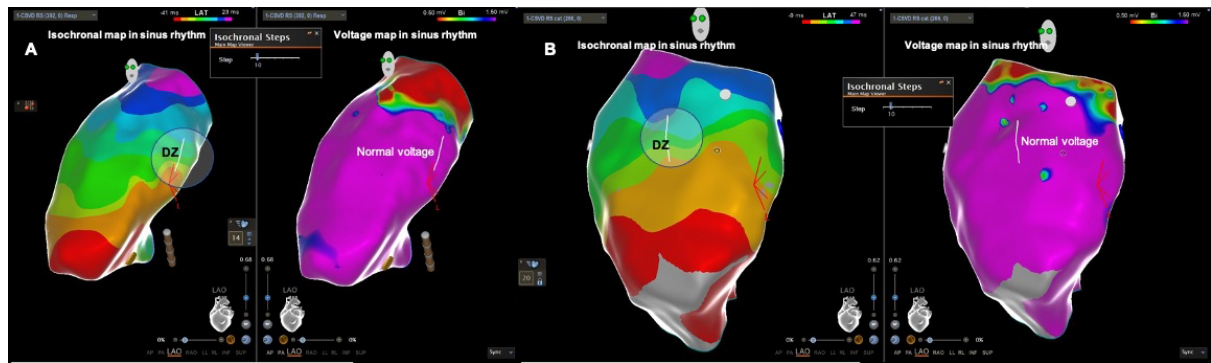


Figure 3. RVOT activation and voltage maps in sinus rhythm in the 2 patients with DZ outside the LVAs (panel A, first patient; panel B, second patient). DZ: deceleration zone

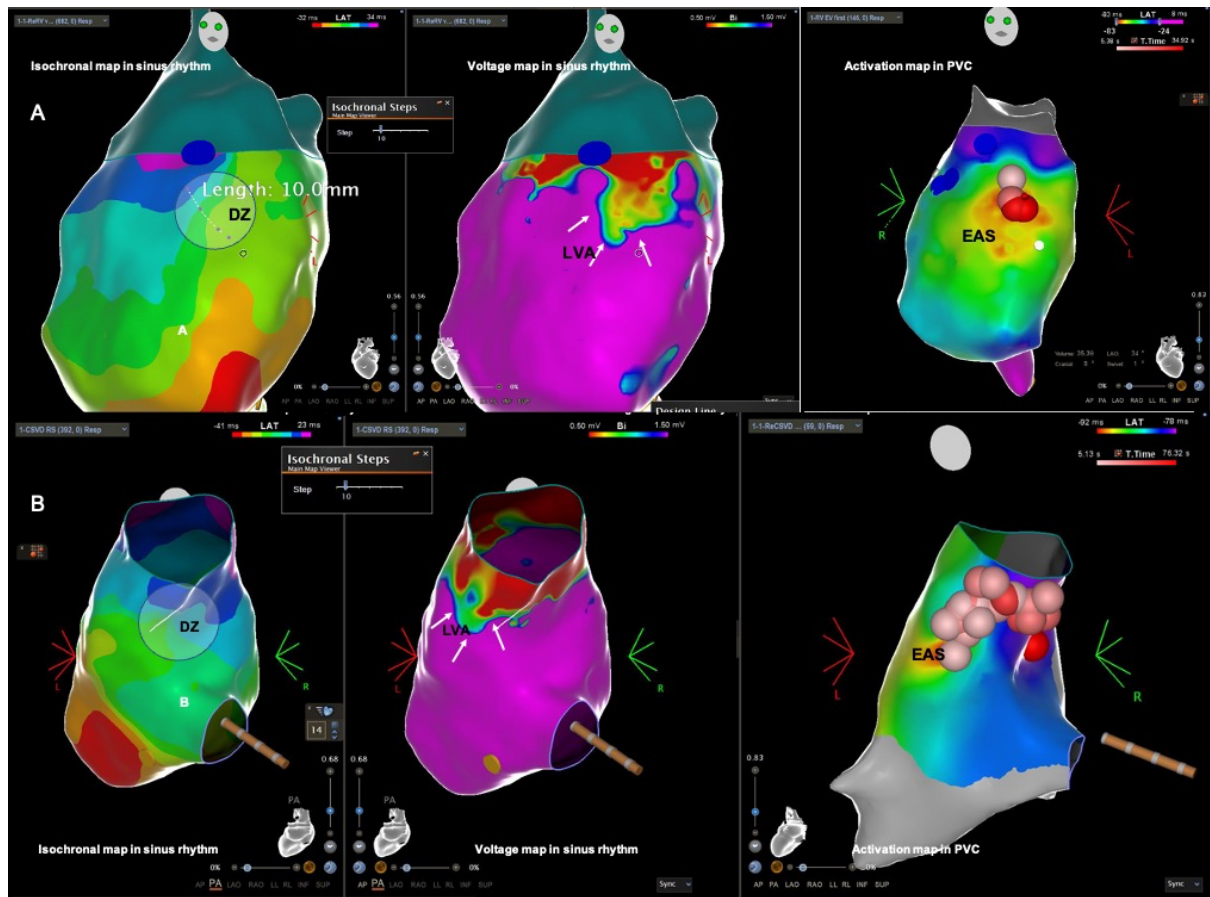


Figure 4. Two patients (panel A and panel B) with the DZ in the LVA and the earliest activation site located in that zone. EAS: earliest activation site; DZ: deceleration zone; LVA: low voltage area; PVC: premature ventricular contractions

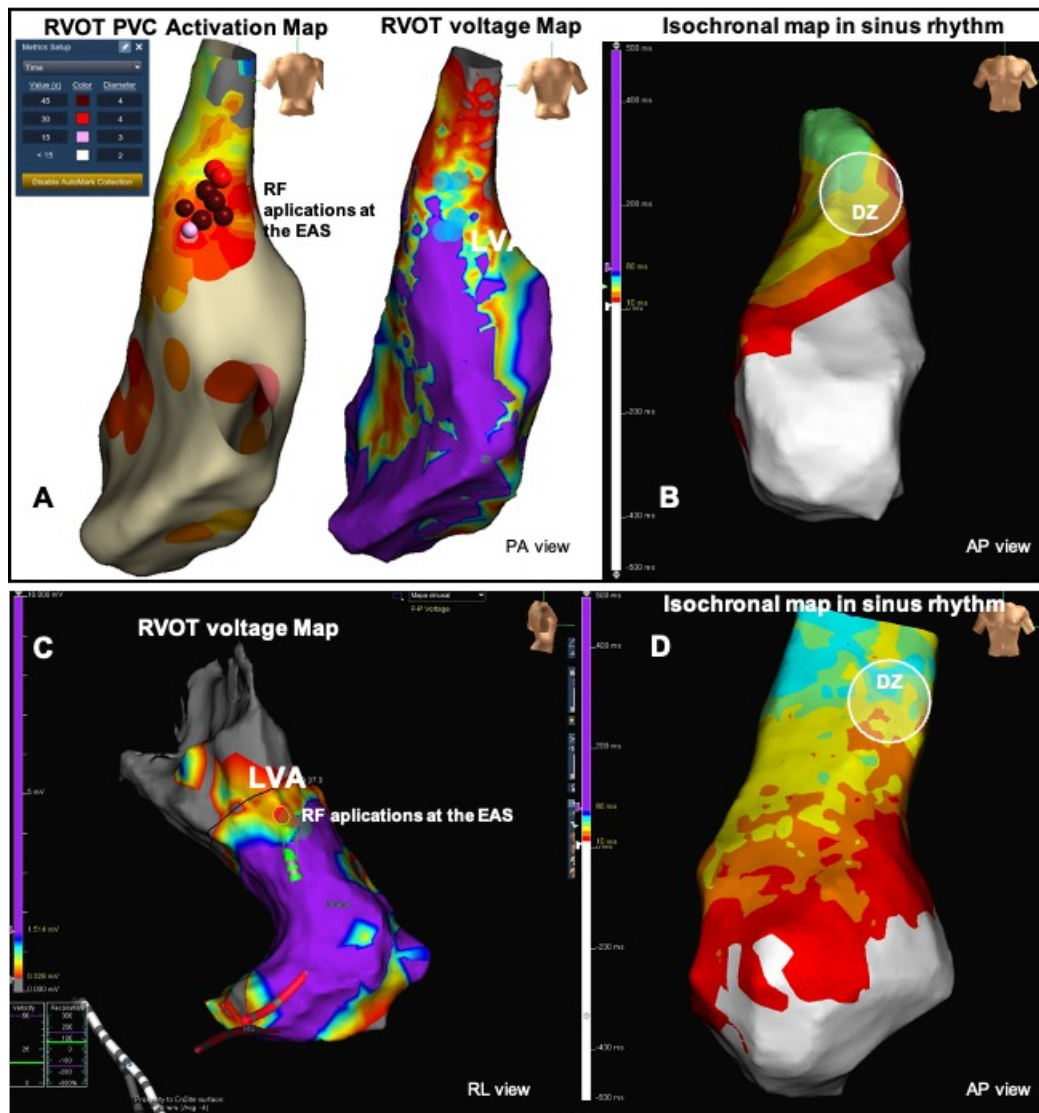


Figure 5. Two patients in whom the EAS was located outside the DZs. First patient's activation map during PVC with RF applications at the EAS (panel A) and voltage map in sinus rhythm displaying isochronal map and DZ (panel B). Second patient's voltage map displaying the RF applications at the EAS superimposed on the voltage map (panel C), and the isochronal map with DZ (panel D). EAS: earliest activation site; DZ: deceleration zone; LVA: low voltage area; RVOT: right ventricular outflow tract; PVC: premature ventricular contractions