

Use of Computational ECG Mapping to Guide Successful Surgical Cryoablation of a PVC Originating near an Intramural Anomalous Coronary Artery

Candace L. Jackson¹, David Krummen¹, Matthew Carazo¹, Gregory Feld¹, Jonathan Artrip¹, and Gordon Ho¹

¹University of California San Diego Health System

August 25, 2023

Abstract

Introduction: Premature ventricular contractions (PVC) and anomalous coronary arteries have not been previously associated. **Methods:** 40-year-old female presented with symptomatic PVCs. Pre-ablation imaging revealed an anomalous right coronary artery (RCA) originating from the left coronary cusp with an interarterial, intramural course. Novel ECG mapping localized PVCs to the septal right ventricular outflow tract (RVOT) near the anomalous RCA. **Results:** Surgical PVC cryoablation at the endocardial RVOT was performed, followed by unroofing surgery, with <1% PVCs at 2 years. **Conclusion:** This is the first report associating PVCs to the site of an anomalous RCA. Surgical cryoablation during unroofing surgery was guided by novel ECG mapping.

Introduction:

Anomalous coronary arteries are rare. A malignant course occurs when the anomalous coronary artery takes an interarterial course between the aorta and pulmonary artery (with or without an intramural segment) and is associated with ischemia and an increased risk of sudden cardiac death due to extrinsic compression.¹⁻⁵ Although the occurrence of ventricular fibrillation (VF) has been reported in patients with malignant anomalous coronary arteries,⁶ ventricular arrhythmias have not been previously localized to the site of an anomalous coronary artery.

We report for the first time the association of a premature ventricular contraction (PVC) originating near an anomalous right coronary artery (RCA), and the successful use of a novel computational mapping algorithm based solely on a standard 12-lead electrocardiogram (ECG) to guide concomitant surgical PVC ablation during coronary artery unroofing.

Case Report:

A 40-year-old female presented with symptomatic palpitations and was found to have 8% burden of monomorphic PVCs of inferior axis left bundle branch block (LBBB) morphology (**Figure 1A**) despite titration of metoprolol and flecainide doses. During workup for PVC ablation, cardiac computed tomography (CT) revealed an anomalous RCA originating from the left sinus of Valsalva with an interarterial, intramural course (**Figure 1B**). Given the intramural course, she was referred for surgical unroofing of the anomalous RCA⁷ and concomitant surgical cryoablation of the PVC.

A novel peri-operative surgical PVC ablation workflow was designed utilizing a non-invasive 12-lead ECG based mapping system (vMap, Vektor Medical Inc, Carlsbad, CA). In the outpatient clinic, the patient's PVCs were captured using a standard 12-lead ECG acquisition system (Muse, GE Medical) and digitized

using custom software. The ECG data file was imported into the computational ECG mapping system. Patient characteristics (absence of scar or left ventricle dilation) were recorded, and the PVC exit site was localized to the septal right ventricular outflow tract (RVOT) underneath the pulmonic valve, near the course of the anomalous RCA. The site of origin was visualized on a 3D model (**Figure 1C**) within 36 seconds of total mapping time.

Subsequently, the patient was placed under general anesthesia and underwent sternotomy. She was initiated on cardiopulmonary bypass, and the heart was arrested. An incision was made in the pulmonary artery, and 3 cryoablation lesions using a cryoablation probe of 90 second durations to -50° Celsius were placed at the PVC exit site localized to the septal RVOT (**Figure 1D**). The pulmonary artery incision was then sutured. Coronary artery unroofing of the intramural RCA was performed, after which the heart was re-perfused, and the patient was weaned off bypass uneventfully.

Post-operatively, the patient recovered without any complications. There were no PVCs on telemetry, and she was discharged from the hospital in 4 days. Her palpitations and PVCs were eliminated durably, with event monitors showing $<1\%$ PVC burden at 2-year follow-up.

Discussion:

Anomalous coronary arteries with a malignant course are associated with an increased risk of arrhythmias and sudden cardiac death,⁴⁻⁶ though ventricular arrhythmias have not been previously localized to the site of an anomalous coronary artery. This is the first report associating a PVC to the site of an anomalous, interarterial, intramural coronary artery.

PVC localization and surgical cryoablation were guided by the use of a novel ECG mapping system. ECG data are imported into the computational mapping system that then localizes and integrates the highest probabilistic location for the PVC focus onto the patient's CT 3D reconstruction model. This algorithm is based on forward-solution computational simulation libraries of arrhythmias including PVCs originating from sites around the heart with or without scar. The simulation libraries are based on 3D finite element models of monodomain cardiac action potential propagation using the Continuity simulation environment. The models consist of detailed descriptions of cardiac geometry, myofiber orientation, and scar. The simulation library incorporates >1 million simulated arrhythmia cycles.

There are many advantages to this technique. This method is less time consuming than traditional invasive catheter-based mapping and is easy to incorporate into any clinical workflow, including mapping in an outpatient clinic using standard widely-available ECG equipment. It has been shown to be a rapid and accurate technique, with a recent blinded multicenter clinical trial showing segmental accuracy of 100% [96-100%] and spatial accuracy of 11mm [5-22mm] for PVC localization.⁸

The use of a non-invasive 12-lead ECG based mapping system to successfully guide surgical ablation of ventricular arrhythmias is a novel approach that can expand the indications for concomitant arrhythmia ablation during cardiac surgery for other indications. The familiarity of the 12-lead ECG to all physicians including cardiac surgeons is attractive as it can be easily integrated into any clinical pre-procedural workflow.

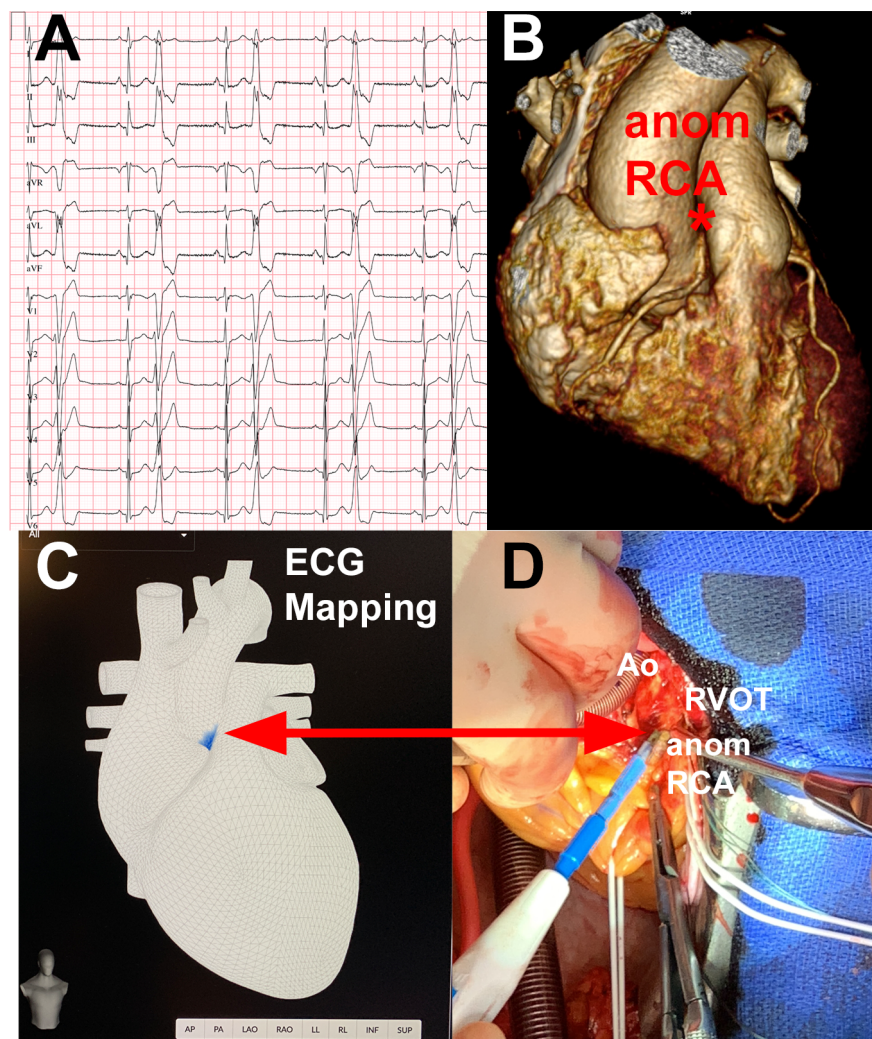
Conclusion:

For the first time, we describe the association of a PVC to the site of an anomalous RCA and the use of a novel arrhythmia ECG mapping algorithm to localize and guide successful concomitant surgical cryoablation during coronary artery unroofing surgery, resulting in long-term elimination of PVCs.

References

1. Cheezum MK, Liberthson RR, Shah NR, et al. Anomalous Aortic Origin of a Coronary Artery From the Inappropriate Sinus of Valsalva. *J Am Coll Cardiol* . Mar 28 2017;69(12):1592-1608. doi:10.1016/j.jacc.2017.01.031
2. Kragel AH, Roberts WC. Anomalous origin of either the right or left main coronary artery from the aorta

- with subsequent coursing between aorta and pulmonary trunk: analysis of 32 necropsy cases. *Am J Cardiol* . Oct 01 1988;62(10 Pt 1):771-7. doi:10.1016/0002-9149(88)91220-9
3. Cheitlin MD, De Castro CM, McAllister HA. Sudden death as a complication of anomalous left coronary origin from the anterior sinus of Valsalva, A not-so-minor congenital anomaly. *Circulation* . Oct 1974;50(4):780-7. doi:10.1161/01.cir.50.4.780
 4. Brothers J, Carter C, McBride M, Spray T, Paridon S. Anomalous left coronary artery origin from the opposite sinus of Valsalva: evidence of intermittent ischemia. *J Thorac Cardiovasc Surg* . Aug 2010;140(2):e27-9. doi:10.1016/j.jtcvs.2009.06.029
 5. Basso C, Maron BJ, Corrado D, Thiene G. Clinical profile of congenital coronary artery anomalies with origin from the wrong aortic sinus leading to sudden death in young competitive athletes. *J Am Coll Cardiol* . May 2000;35(6):1493-501. doi:10.1016/s0735-1097(00)00566-0
 6. Anantha Narayanan M, DeZorzi C, Akinapelli A, et al. Malignant Course of Anomalous Left Coronary Artery Causing Sudden Cardiac Arrest: A Case Report and Review of the Literature. *Case Rep Cardiol* . 2015;2015:806291. doi:10.1155/2015/806291
 7. Stout KK, Daniels CJ, Aboulhosn JA, et al. 2018 AHA/ACC Guideline for the Management of Adults With Congenital Heart Disease: A Report of the American College of Cardiology/American Heart Association Task Force on Clinical Practice Guidelines. *Circulation* . Apr 02 2019;139(14):e698-e800. doi:10.1161/CIR.0000000000000603
 8. Krummen DE, Villongco CT, Ho G, et al. Forward-Solution Noninvasive Computational Arrhythmia Mapping: The VMAP Study. *Circ Arrhythm Electrophysiol* . Sep 2022;15(9):e010857. doi:10.1161/CIRCEP.122.010857



Figures

