

# Silicosis unveiled: Improving diagnostic accuracy and distinguishing it from tuberculosis: A case report from a low and middle-income country

Sanskriti Chapagain<sup>1</sup>, Abhigan Shrestha<sup>2</sup>, shumneva shrestha<sup>3</sup>, sajina shrestha<sup>4</sup>, Vikash Jaiswal<sup>5</sup>, Hritik Yadav<sup>6</sup>, and Nilasma Shrestha<sup>7</sup>

<sup>1</sup>Devdaha Medical College and Research Institute

<sup>2</sup>M Abdur Rahim Medical College Hospital

<sup>3</sup>Tribhuvan University Institute of Medicine Maharajgunj Medical Campus

<sup>4</sup>KIST Medical College

<sup>5</sup>AMA School of Medicine

<sup>6</sup>M Abdur Rahim Medical College

<sup>7</sup>Kathmandu Medical College

July 27, 2023

## Silicosis unveiled: Improving diagnostic accuracy and distinguishing it from tuberculosis: A case report from a low and middle-income country

Chapagain, Sanskriti<sup>1</sup>, Shrestha, Abhigan Babu<sup>2</sup>, Shrestha, shumneva<sup>3</sup>, Shrestha, sajina<sup>4</sup>, jaiswal, vikash<sup>5</sup>, yadav, Hritik Raj<sup>2</sup>, Shrestha, Nilasma<sup>6</sup>

1. Devdaha Medical College and Research Institute, Bhaluhi, Rupandehi, Nepal

2. M Abdur Rahim Medical College Hospital, Department Of Internal Medicine  
Dinajpur, Bangladesh

3. Tribhuvan University Institute of Medicine Maharajgunj Medical Campus, Nepal

4. KIST Medical College, Department Of Internal Medicine, patan Imadol, Lalitpur, Nepal

5. Medical AMA School of Medicine, Medicine Bangkal makati, Philippines Makati City, Luzon

6. Kathmandu Medical College, Kathmandu, Nepal

**Corresponding author** : Chapagain, Sanskriti

Devdaha Medical College and Research Institute, Bhaluhi, Rupandehi, Nepal

sanskritichapagain527@gmail.com

## Abstract

Silicosis is an occupational lung disease caused by exposure to crystalline quartz particles, leading to lung inflammation and scarring. Pulmonary tuberculosis is an infectious disease caused by *Mycobacterium tuberculosis*, primarily affecting the lungs. Silicosis increases the risk of developing tuberculosis in high-burden settings. We present the case of a 40-year-old smoker male, with a history of stone crushing for 10 years, who presented to the emergency department with dyspnea and cough which increased progressively for the

past nine months with sputum production. All pulmonary TB patients should have their sputum examined by microscopy to determine if they are infectious or not but in this case the sputum examination is negative, posing a diagnostic challenge and previously diagnosed as active TB based on X-ray abnormalities and clinical findings and had a full course of TB treatment. This case emphasizes the difficulty in differentiating silicosis from tuberculosis, as tuberculosis can mask the symptoms and radiological features of silicosis. Thus, a comprehensive occupational history, clinical features, and radiological evaluation are crucial for an accurate diagnosis.

## Keywords

Occupational, Silicosis, Tuberculosis

## Introduction

Silicosis is an irreversible and fibrotic interstitial lung disease that is frequently brought on by inhaling crystalline silica or silicon dioxide.<sup>1</sup> According to the Global Burden of Disease (GBD) report, silicosis continued to be the most important risk factor for pneumoconiosis in 2017 with 39% of cases being attributed to it. It is manifested by a range of respiratory symptoms such as cough, shortness of breath, chest tightness, and sputum expectoration<sup>2</sup>. Since there is no complete cure for the illness, prevention and early diagnosis through clinical features and radiological features are essential.<sup>3</sup>

Patients with silicosis are three to four times more likely to get TB than those who do not have silicosis.<sup>4</sup> There may be difficulty in differentiating silicosis from tuberculosis, as tuberculosis can mask the symptoms and radiological features of silicosis. Here, we report the case of a 40-year-old man with silicosis having a history of stone crushing for 10 years he was previously misdiagnosed with tuberculosis based on X-ray abnormalities and clinical findings and had a full course of TB treatment.

## Case description

A 40-year-old male, a stone crusher for the past 10 years, presented to the emergency department with a complaint of shortness of breath at rest for 4 hours. He also presented with an exaggeration of cough for about 10 years which increased progressively for the past nine months. There was no history of fever, night sweats, anorexia, weight loss, joint pain, or skin rashes. He did not report any chest pain and hemoptysis. Notably, the individual had been clinically diagnosed with active TB based on X-ray abnormalities and clinical findings and had a full course of TB treatment. There was no history of smoking and alcohol consumption. On examination, the patient was with a modified medical research council (MMRC) dyspnea scale of 4, a blood pressure of 130/95 mmHg, a rapid pulse rate of 140 bpm, respiratory rate of 30 breaths per min, temperature of 98.6 degrees F and an oxygen saturation level of 83% without supplemental oxygen. On the chest, examination revealed tracheal deviation towards the right, accompanied by diminished vesicular breath sounds and diffuse crepitations. The patient was admitted with a provisional diagnosis of silicosis based on clinical examinations and a chest X-ray.

## Investigation

A complete blood count showed potassium elevation but no other abnormality. A sputum examination yielded negative results for acid-fast bacilli. A chest x-ray illustrated profuse, multifocal, poorly defined consolidations predominantly localized in the upper and middle lung lobes. Additionally, a ground-glass appearance was observed in the lower lobes, concomitant with tracheal deviation towards the right as shown in the figure. Due to the invasive procedure of High-Resolution Computed Tomography (HRCT) and the financial constraints faced by the patient, he made the decision not to proceed with HRCT and explore alternative diagnostic options that were more affordable and less invasive. Based on the above findings differential diagnosis includes pneumoconiosis, pulmonary tuberculosis, emphysema, sarcoidosis, rheumatoid arthritis, and other interstitial diseases.

The absence of AFB in sputum, -ve for test gen expert and characteristic chest x-rays favor the diagnosis of silicosis. The patient was admitted to the ward, and high-flow oxygen therapy and steroid administration

were given. Furthermore, bronchodilators and leukotriene antagonists were employed to relax the airways and reduce inflammation. Two samples of sputum, one from one spot and another from another morning were negative for AFB. The patient was discharged with an improvement in symptoms. The patient could not follow up due to non-compliance.

## Discussion

Individuals working in occupations such as sandblasting, mining, quarrying, flour milling, glass manufacturing, building construction, brick manufacturing, road repairs, and concrete manufacturing often experience the adverse effects of silicosis.<sup>5</sup> The crystalline silica particles measuring less than 1  $\mu\text{m}$  are widely considered to be the most pathogenic.<sup>6,7</sup> Worldwide, silicosis caused more than 12.9 thousand fatalities, and in 2019 it was responsible for 655.7 thousand disability-associated life years (DALY).<sup>2</sup> Along the disease's spectrum, chronic forms, accelerated forms, and acute silicosis are found.<sup>8</sup> One case report has documented similar chief complaints to those observed in our case.<sup>9</sup> Exposure to silica results in the activation of alveolar macrophages and induces reactive oxygen (ROS) and nitrogen (RNS) which results in elevated susceptibility to bacterial infections due to a decrease in antioxidant defense mechanism, particularly those caused by *Mycobacterium tuberculosis*.<sup>10,11,12</sup>

According to the WHO Global TB Report 2021, 43% of people living in the South-East Asia (SEA) Region have an incidence of TB.<sup>13</sup> In this case, the patient had a previous tuberculosis diagnosis based on the disease's prevalence and radiological features, even though the sputum test for acid-fast bacilli (AFB) and gene expert test were negative. The patient received anti-TB treatment, however, it did not relieve his symptoms. People with silicosis had a 2.8 ratio chance of developing pulmonary tuberculosis and a 3.7 ratio risk of developing extra-pulmonary tuberculosis compared to those without the condition.<sup>14</sup> However, among those who had silicosis, the prevalence of TB was significantly higher at 917 cases per 100,000 individuals.<sup>15</sup> In this case, having a thorough occupational history is essential for establishing an accurate diagnosis. There are no specific treatment modalities for silicosis. The primary goals of treatment revolve around slowing down the progression of the disease and alleviating symptoms. Strategies include eliminating silica and lung irritants exposure, quitting smoking, oxygen therapy, and screenings.<sup>3</sup> Recently, Pirfenidone and nintedanib, both approved by the US Food and Drug Administration (FDA), have been extensively examined in silicosis models, yielding substantial evidence.<sup>16,17</sup> In severe cases where the disease has significantly progressed and lung function is severely compromised, lung transplantation is done.<sup>18</sup> One of the challenges associated with silicosis and tuberculosis is the potential for misdiagnosis due to similar presentations and inadequate occupational histories. All pulmonary TB patients should have their sputum examined by microscopy/Xpert MTB/RIF to determine if they are infectious or not but in this case the sputum examination is negative, posing a diagnostic challenge and diagnosed as active TB based on X-ray abnormalities and clinical findings and had a full course of TB treatment. Chest X-ray and high-resolution computed tomography (HRCT) are usually used to diagnose pneumoconiosis but due to financial constraints, the patient did not go for HRCT and multiple differential diagnoses had been proposed based on our patient's clinical presentation and chest x rays such as silicosis, bronchitis, bronchitis, emphysema, pulmonary tuberculosis, Sarcoidosis, and rheumatoid arthritis. Our patient's clinical features and occupational exposure to stone crushers for 10 years, different physical findings, sputum negative for acid-fast bacilli on microscopy/Xpert MTB/RIF, which later suggests a diagnosis of silicosis.

As silicosis progresses, improper or postponed disease management can have negative effects on patients and result in treatment failure. In addition, patients' financial, psychological, and emotional effects shouldn't be disregarded because they could feel anxious, frustrated, or lose faith in the healthcare system. Healthcare professionals should be encouraged to improve diagnostic methods, including thorough occupational histories, and radiological imaging, and, to effectively differentiate between the two conditions in high-risk industries associated with silicosis.

## Conclusion

This case report highlights the diagnostic challenge posed by silicosis and the importance of considering

occupational exposure history, characteristic radiographic findings, and clinical presentation for an accurate diagnosis. With an abnormal chest X-ray, an anti-TB drug shouldn't be started in a high TB area unless we make a diagnosis. Hence, prompt recognition, early intervention, and occupational safety measures are crucial to prevent the occurrence and progression of silicosis among workers exposed to crystalline silica.

**AUTHOR CONTRIBUTIONS**All authors contributed equally to this manuscript, conceptualization, writing, editing, and preparation of the manuscript, and reviewed it before submission. A.B.S supervised the manuscript.

#### Declaration of patient consent

Written informed consent was obtained from the patient for the publication of this case report and accompanying images. A copy of the written consent is available for review by the Editor-in-Chief of this journal on request.

#### Sources of funding

N/A

#### Conflicts of Interest disclosure

No conflict of interest

#### Provenance and peer review

Not commissioned, externally peer-reviewed.

#### Acknowledgments

No acknowledgments.

#### Ethical approval

N/A

#### Consent

Written informed consent was obtained from the patient for publication of the case report. A copy of the written consent is available for review by Editor-in-chief of the journal on request.

#### References

1. Hoy RF, Jeebhay MF, Cavalin C, et al. Current global perspectives on silicosis—Convergence of old and newly emergent hazards. *Respirology*. 2022;27(6):387-398. doi:10.1111/resp.14242
2. Global burden of 369 diseases and injuries in 204 countries and territories, 1990–2019: a systematic analysis for the Global Burden of Disease Study 2019. *Lancet*. 2020;396(10258):1204-1222. doi:10.1016/S0140-6736(20)30925-9
3. Fernández Álvarez R, Martínez González C, Quero Martínez A, Blanco Pérez JJ, Carazo Fernández L, Prieto Fernández A. Guidelines for the diagnosis and monitoring of silicosis. *Arch Bronconeumol*. 2015;51(2):86-93. doi:10.1016/j.arbres.2014.07.010
4. Rupani MP. A mixed-methods study on impact of silicosis on tuberculosis treatment outcomes and need for TB-silicosis collaborative activities in India. *Sci Rep*. 2023;13(1):2785. doi:10.1038/s41598-023-30012-4
5. Chen FF, Tang HY, Yu F, et al. Renal involvement in a silicosis patient – case report and literature review. *Ren Fail*. 2019;41(1):1045-1053. doi:10.1080/0886022X.2019.1696209

6. Rom WN, Bitterman PB, Rennard SI, Cantin A, Crystal RG. Characterization of the lower respiratory tract inflammation of nonsmoking individuals with interstitial lung disease associated with chronic inhalation of inorganic dusts. *Am Rev Respir Dis*. 1987;136(6):1429-1434. doi:10.1164/ajrccm/136.6.1429
7. Reiser KM, Last JA. Silicosis and fibrogenesis: fact and artifact. *Toxicology*. 1979;13(1):51-72.
8. Guarnieri G, Bizzotto R, Gottardo O, et al. Multiorgan accelerated silicosis misdiagnosed as sarcoidosis in two workers exposed to quartz conglomerate dust. *Occup Environ Med*. 2019;76(3):178-180. doi:10.1136/oemed-2018-105462
9. Shrestha AB, Yadav AK, Shrestha S, et al. A rare case of silicosis with hepatitis B infection. *Ann Med Surg (Lond)*. 2022;84:104838. doi:10.1016/j.amsu.2022.104838
10. Tavakol E, Azari M, Zendehdel R, et al. Risk Evaluation of Construction Workers' Exposure to Silica Dust and the Possible Lung Function Impairments. *Tanaffos*. 2017;16(4):295-303.
11. Mohammadi H, Farhang Dehghan S, Tahamtan A, Golbabaei F. Evaluation of potential biomarkers of exposure to crystalline silica: A case study in an insulator manufacturer. *Toxicol Ind Health*. 2018;34(7):491-498. doi:10.1177/0748233718770073
12. Hamaguchi Y, Nishizawa Y, Yasui M, et al. Intercellular Adhesion Molecule-1 and L-Selectin Regulate Bleomycin-Induced Lung Fibrosis. *The American Journal of Pathology*. 2002;161(5):1607-1618. doi:10.1016/S0002-9440(10)64439-2
13. Tuberculosis. Accessed July 15, 2023. <https://www.who.int/southeastasia/health-topics/tuberculosis>
14. Cowie RL. The epidemiology of tuberculosis in gold miners with silicosis. *Am J Respir Crit Care Med*. 1994;150(5 Pt 1):1460-1462. doi:10.1164/ajrccm.150.5.7952577
15. Farazi A, Jabbariasl M. Silico-tuberculosis and associated risk factors in central province of Iran. *Pan Afr Med J*. 2015;20:333. doi:10.11604/pamj.2015.20.333.4993
16. Cao Z jie, Liu Y, Zhang Z, et al. Pirfenidone ameliorates silica-induced lung inflammation and fibrosis in mice by inhibiting the secretion of interleukin-17A. *Acta Pharmacol Sin*. 2022;43(4):908-918. doi:10.1038/s41401-021-00706-4
17. Wollin L, Maillet I, Quesniaux V, Holweg A, Ryffel B. Antifibrotic and anti-inflammatory activity of the tyrosine kinase inhibitor nintedanib in experimental models of lung fibrosis. *J Pharmacol Exp Ther*. 2014;349(2):209-220. doi:10.1124/jpet.113.208223
18. Hoy RF, Chambers DC. Silica-related diseases in the modern world. *Allergy*. 2020;75(11):2805-2817. doi:10.1111/all.14202

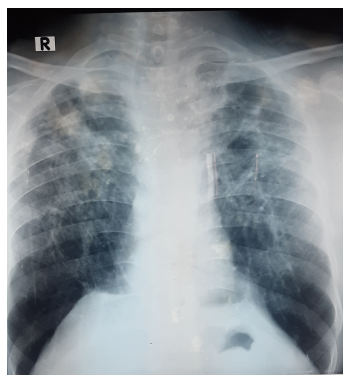


Figure. Chest X-ray showed profuse, multifocal, poorly defined consolidations predominantly localized in the upper, middle lung lobes, and a ground-glass appearance was observed in the lower lobes, concomitant with tracheal deviation towards the right.