

Disseminated Tuberculosis in an immunocompetent woman from the Himalayan region of Nepal: A case report

Ram Subedi¹, Subi Acharya², Ayush Adhikari³, Sabin Banmala⁴, Tibbin Shiwakoti⁵, Pearlbiga Karki⁶, Shekhar Gurung⁷, Bhuwan Bhatta⁸, Naresh Kharbujia¹, and Raju Paudel¹

¹Grande International Hospital

²Patan Academy of Health Sciences

³Tribhuvan University Teaching Hospital

⁴Sindhuli Hospital

⁵Karnali Academy of Health Sciences

⁶Nepalese Army Institute of Health Sciences

⁷Shivanagar Primary Health Care Center

⁸Kantipur Hospital

April 7, 2023

Introduction

Tuberculosis (TB) is one of the most common global health burdens caused by *Mycobacterium Tuberculosis*.¹ Almost half of the TB cases remain unreported, contributing to the underdiagnosis of extrapulmonary tuberculosis.² The worldwide incidence of disseminated TB is also in increasing trend. Central nervous system (CNS) involvement is one of the most devastating complications of tuberculosis and is seen in 10% of all disseminated TB cases, accounting for 1% of all TB cases.³ CNS involvement may present as meningitis, cerebral tuberculoma, tuberculoma abscess, and thoracic transverse myelopathy.^{1,4}

The predominant symptoms of disseminated TB are fever, cough, malaise, loss of appetite, weakness, and weight loss. In addition, symptoms according to system involvement are often seen, like a headache in the case of meningeal tuberculosis and abdominal pain in peritoneal or intestinal tuberculosis.⁵

Although the treatment of disseminated and pulmonary TB are considered the same, CNS involvement warrants a longer duration of treatment. The four-drug regimen of rifampicin, isoniazid, pyrazinamide, and ethambutol is administered daily for two months, followed by rifampicin and isoniazid for two months. In disseminated cases, these two drug regimens can be extended. There is no clear evidence of the effectiveness of corticosteroids in disseminated TB cases. However, steroids are often used in disseminated cases.⁶ Early identification and prompt management are the cornerstones for optimal patient management in disseminated TB with CNS involvement.

We reported this case following the updated consensus-based Surgical Case Report (SCARE) Guidelines.⁷

Case Presentation

A 25-year-old female with no known comorbidities presented with complaints of fever, productive cough, generalized body weakness, vomiting, and anorexia for five months. However, she gave no history of evening rise in temperature, significant weight loss, blood in sputum, or contact with TB-positive people. Physical examination, including vitals and general and systemic examination was normal.

Chest X-ray showed miliary nodules in bilateral lung fields, while gene Xpert sputum test revealed rifampicin-sensitive *Mycobacterium tuberculosis*. Pulmonary tuberculosis was thus diagnosed on the grounds of a positive gene Xpert test and features of tuberculosis in a chest radiograph. Antitubercular therapy (ATT) with rifampicin, isoniazid, pyrazinamide and ethambutol was started. However, as she developed increased oxygen requirements, she was admitted to the medical ICU. During ICU stay, the patient developed irrelevant talking, altered mental status, and increased shortness of breath. She also had an episode of a generalized tonic-clonic seizure. Following this, a lumbar puncture was done, which showed lymphocyte predominance, increased protein, and decreased glucose level. However, adenosine deaminase (ADA) was within normal range, and acid-fast bacillus was not seen. Thus, TB meningitis was diagnosed on the background of pulmonary tuberculosis.

The patient was referred to our center five days after starting ATT for better management. At the time of presentation, her vitals showed blood pressure of 135/70 mmHg, pulse rate of 82 bpm, temperature of 36 C, respiratory rate of 20 breaths per minute, and oxygen saturation of 100% in 15 liters per minute of oxygen. On auscultation of the chest, decreased air entry and crepitations were heard in bilateral lung fields. The patient had spontaneous eye opening, inappropriate vocalization, and localizing movement with pain (E4V3M5). Motor examination revealed power of 4/5 in bilateral upper and lower extremities, normal tone and deep tendon reflexes in bilateral upper limbs and lower limbs, normal plantar reflex, and intact sensation. Neck rigidity was present while Brudzinkis and Kernig's signs were absent.

Lab investigations showed increased liver enzymes; AST: 78 U/L, ALT: 80 U/L, GGT: 95 U/L, increased CRP (73 mg/L), methicillin-sensitive coagulase-negative *Staphylococcus* in blood culture, Na- 133mmol/Lt, K-3.6 mmol/Lt, Hb-11.5 g/dl, total leukocyte count of 9489 / cubic mm. Serology of HCV antibody, HBsAg, HIV 1 and 2 antibodies was negative. In the NCCT head, mild effacement of sulcal spaces in bilateral cerebral hemispheres was seen. FLAIR imaging showed features suggestive of hydrocephalus. (Figure 1) MRI of coronal section of brain showed multiple enhancing nodular lesions in bilateral hemispheres. (Figure 2) A high-resolution CT scan of the chest showed mild pneumomediastinum, numerous randomly distributed miliary nodules in bilateral lungs, patchy areas of consolidation, and few patches of ground glass opacities in bilateral lower lobes. Based on findings of LP, MRI head, HRCT chest, and gene Xpert test, the final diagnosis of disseminated tuberculosis was made.

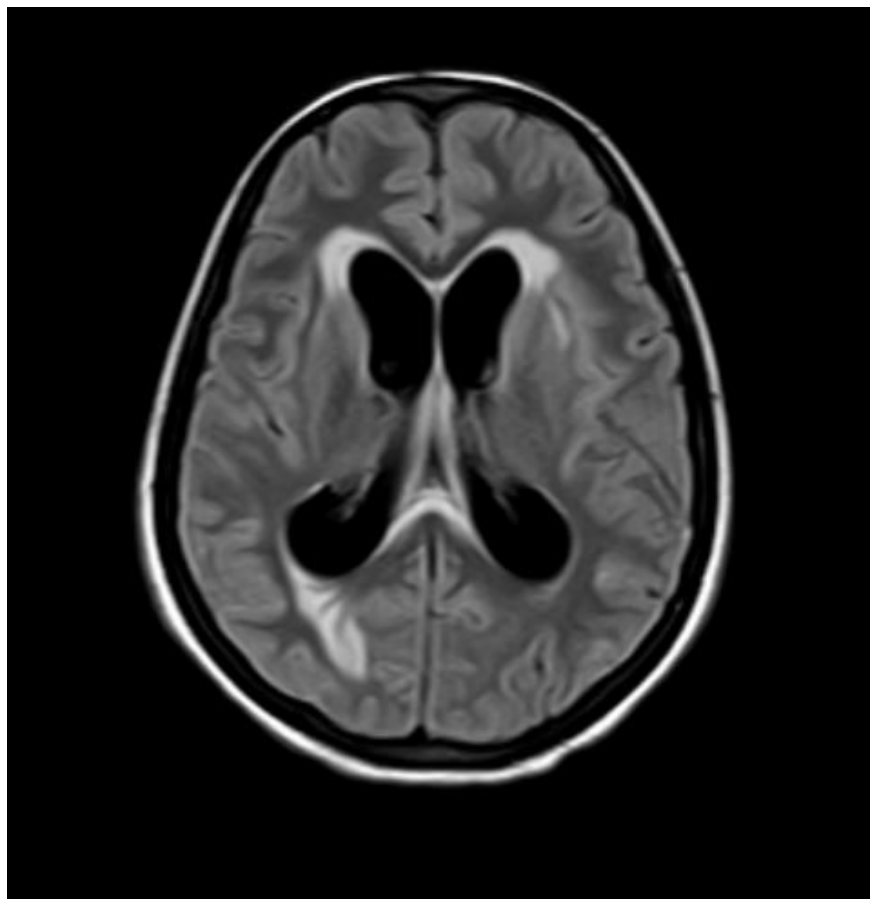


Figure 1: FLAIR (Fluid Attenuated Inverse Recovery) showing dilatation of the ventricular system with periventricular ooze suggestive of hydrocephalus

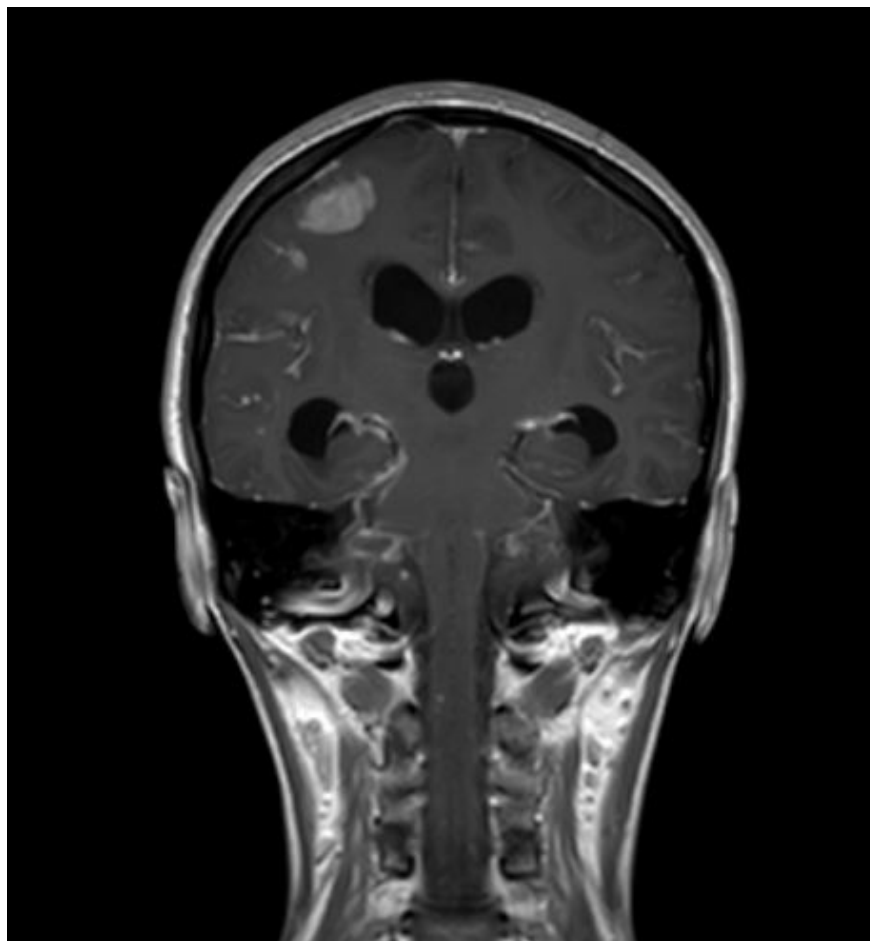


Figure 2: Post contrast MRI coronal section showing diffuse leptomeningeal enhancement in bilateral cerebral hemispheres with multiple enhancing nodular lesions in bilateral cerebral hemispheres, basal ganglia and brainstem.

Along with the continuation of antitubercular therapy, the patient was started on dexamethasone 4mg TDS for four weeks, which was tapered off and stopped. During her hospital stay, she developed ATT-induced hepatitis, for which she was kept in liver friendly regimen until recovery. She was reinitiated on ATT after improvement in liver function. The patient had developed pneumoperitoneum with pneumomediastinum, which was managed conservatively.

At the time of discharge, she could walk without support and was oriented to time place and person. Two weeks later, she presented with fever and burning micturition, which was treated with appropriate antibiotics. Her SARS COV-2 report was positive despite being previously vaccinated with two doses of Vero cell vaccine. She was admitted to the COVID-19 isolation ward, where her stay was uneventful. On the follow-up visit, patient was doing fine and was taking intensive phase of ATT drugs. Her steroid dosage was gradually tapered on follow up visit.

Discussion

Disseminated tuberculosis (TB) resulting from lymphohematogenous dissemination of *Mycobacterium tuberculosis* during primary infection or reactivation of latent disease is rare among young immunocompetent patients.^{8,9} Central nervous system TB (CNS TB) is one of the most challenging clinical diagnoses, with a

prevalence of 4.55% of all cases of TB. The spectrum of CNS TB includes TB meningitis, tuberculoma, and spinal arachnoiditis, where TB meningitis is the most predominant form.¹⁰ Small tuberculous lesions known as Rich's foci, formed in the cerebral cortex, cerebral parenchyma, or spinal cord, may remain dormant for several years. Rupture of these foci leads to the spread of the bacilli into the subarachnoid space, resulting in tuberculous meningitis.¹¹ Risk factors of miliary TB and extrapulmonary TB include HIV, diabetes mellitus, smoking, alcohol abuse, malnutrition, and overcrowding, which were absent in our patient.^{8,12} Recent research has suggested that this disease form may be predisposed by a genetic abnormality in the interleukin-12 (IL-12) and interferon-gamma pathways. The pathophysiology and genetic components driving immunocompetent hosts' susceptibility to Mycobacterium TB infection are yet unclear.¹³

Due to the variable and non-specific presentation of the disease, CNS TB is difficult and challenging to diagnose. The clinical course is typically subacute or chronic.¹⁴ About one-third of patients on presentation have underlying miliary TB. Careful fundoscopy may reveal choroidal tubercles, offering a valuable clue to the etiology.¹⁵

A definitive diagnosis of tuberculous meningitis may be established with detection of AFB either by positive smear, culture, or with a positive nucleic acid amplification test (NAAT).¹⁶ The poor sensitivity and specificity of diagnostic tests, however, can make it difficult to make a definitive diagnosis. Typically, the CSF in tuberculous meningitis shows an elevated protein level, predominant lymphocytosis, and a decreased glucose concentration.

Adenosine deaminase (ADA) testing has not been helpful in diagnosing TB meningitis, as an ADA cut-off value that optimizes both sensitivity and specificity has been difficult to establish. In 2013, WHO recommended Xpert MTB/Rif assay, a commercial NAAT, preferentially over conventional microscopy and culture for initial TB meningitis testing in resource-limited settings, which is highly specific for TB meningitis but is variable in specificity. Brain imaging in TB meningitis commonly shows basilar meningeal enhancement, hydrocephalus, basal ganglion enhancement, cerebral parenchymal tuberculomas, and infarcts. MRI is superior to CT for detecting TB meningitis.¹⁷ Pulmonary tuberculosis (PTB) gives clues to suspect bacillary etiology of CNS infection. Therefore, this patient's CNS diagnosis was made based on specific CSF findings, CT/MRI findings, ophthalmologic, and simultaneous pulmonary TB diagnosis.

The current WHO recommendations for treating TB meningitis are based on those made to treat PTB and recommend that all patients receive therapy with two months of rifampicin (RMP), isoniazid (INH), pyrazinamide (PZE), and ethambutol (ETB), followed by up to 10 months of RMP and INH. This regimen ignores the many anti-tuberculosis medications' varying capacities for brain penetration. Dexamethasone lowers mortality in HIV-negative TB meningitis; however, there is not enough data to support its usage in HIV co-infection.¹⁸ This patient was started on two months of HRZE, two months of dexamethasone, and continued with HR. Timely diagnosis and treatment are essential since prognosis largely depends on neurological status at presentation, time-to-treatment initiation, HIV co-infection, and drug resistance. Therefore, empiric treatment should be initiated as soon as the diagnosis is suspected. This patient, with no immunocompromised conditions and drug resistance, received timely treatment for TB meningitis and, thus, showed total recovery.

Disseminated TB involving CNS in immunocompetent adults is challenging to diagnose and often delayed or missed. As there is little evidence on the pathophysiology of disseminated TB in the immunocompetent host, further research is essential.

Author Contributions

RCS and SA led data collection, contributed in writing the case information and discussion. AA, SB contributed to the process of original draft preparation and introduction. TS and PK contributed to conceptualization, methodology and discussion. SG and BB revised it critically for important intellectual content, contributed in review and editing. NK and RP edited the rough draft into the final manuscript.

Acknowledgement

The authors thank Grande International Hospital for providing the MRI images.

Funding Information

The study did not receive any grant from funding agencies in the public, commercial, or not-for-profit sectors.

CONFLICT OF INTEREST

The authors report no conflicts of interest.

ETHICAL APPROVAL

This is a case report; therefore, it did not require ethical approval from ethics committee.

CONSENT

Written informed consent was obtained from the patient for publication of this case report and accompanying images. A copy of the written consent is available for review by the editor-in-chief of this journal on request.

REGISTRATION OF RESEARCH STUDIES

Not applicable.

None

References

1. Sharma SK, Mohan A, Sharma A, Mitra DK. Miliary tuberculosis: new insights into an old disease. *Lancet Infect Dis*. 2005 Jul;5(7):415–30.
2. Gaifer Z. Epidemiology of extrapulmonary and disseminated tuberculosis in a tertiary care center in Oman. *Int J mycobacteriology*. 2017;6(2):162–6.
3. Cherian A, Thomas S V. Central nervous system tuberculosis. *Afr Health Sci*. 2011 Mar;11(1):116–27.
4. Garg RK, Sharma R, Kar AM, Kushwaha RAS, Singh MK, Shukla R, et al. Neurological complications of miliary tuberculosis. *Clin Neurol Neurosurg*. 2010 Apr;112(3):188–92.
5. Prout S, Benatar SR. Disseminated tuberculosis. A study of 62 cases. *S Afr Med J*. 1980 Nov;58(21):835–42.
6. Khan FY. Review of literature on disseminated tuberculosis with emphasis on the focused diagnostic workup. *J Family Community Med*. 2019;26(2):83–91.
7. Agha RA, Franchi T, Sohrabi C, Mathew G, Kerwan A. The SCARE 2020 Guideline: Updating Consensus Surgical Case Report (SCARE) Guidelines. *Int J Surg*. 2020 Dec;84:226–30.
8. Rosenthal AH, Rothfield LD, Chamorro Dauer L. Disseminated Tuberculosis in a Healthy Adolescent Female. Vol. 11, *Cureus*. 2019. p. e4967.
9. Hilal T, Hurley P, McCormick M. Disseminated tuberculosis with tuberculous meningitis in an immunocompetent host. Vol. 2014, *Oxford medical case reports*. 2014. p. 125–8.
10. Navarro-Flores A, Fernandez-Chinguel JE, Pacheco-Barrios N, Soriano-Moreno DR, Pacheco-Barrios K. Global morbidity and mortality of central nervous system tuberculosis: a systematic review and meta-analysis. *J Neurol*. 2022 Jul;269(7):3482–94.
11. Dian S, Ganiem AR, van Laarhoven A. Central nervous system tuberculosis. *Curr Opin Neurol*. 2021 Jun;34(3):396–402.
12. Vasconcelos G, Santos L, Couto C, Cruz M, Castro A. Miliary Brain Tuberculomas and Meningitis: Tuberculosis Beyond the Lungs. *Eur J case reports Intern Med*. 2020;7(12):1931.

13. Donovan ML, Schultz TE, Duke TJ, Blumenthal A. Type I Interferons in the Pathogenesis of Tuberculosis: Molecular Drivers and Immunological Consequences. *Front Immunol.* 2017;8:1633.
14. Kent SJ, Crowe SM, Yung A, Lucas CR, Mijch AM. Tuberculous meningitis: a 30-year review. *Clin Infect Dis an Off Publ Infect Dis Soc Am.* 1993 Dec;17(6):987–94.
15. Dunphy L, Shetty P, Randhawa R, Rani KA, Duodu Y. Tuberculous meningitis in an immunocompetent male complicated by hydrocephalus. *BMJ Case Rep.* 2016 Oct;2016.
16. Marais S, Thwaites G, Schoeman JF, Török ME, Misra UK, Prasad K, et al. Tuberculous meningitis: a uniform case definition for use in clinical research. *Lancet Infect Dis.* 2010 Nov;10(11):803–12.
17. Bourgi K, Fiske C, Sterling TR. Tuberculosis Meningitis. *Curr Infect Dis Rep.* 2017 Sep;19(11):39.
18. Davis A, Meintjes G, Wilkinson RJ. Treatment of Tuberculous Meningitis and Its Complications in Adults. *Curr Treat Options Neurol.* 2018 Feb;20(3):5.