

Hypogonadism due to pituitary macroadenoma with inflammatory bowel disease and hemolytic anemia in a 22 years old Sudanese patient

FADI AHMED¹, DANIA DIAB², KHALID FADLALLAH ¹, MOGAHID ALTEIB¹, MONZER SAIFALDEEN¹, AHMED MOHAMMED¹, Mohammed BABIKER ¹, YASIR ELDAI¹, FAYHAA MAHMOOD ¹, and SAMER BALLA ¹

¹University of Sinnar

²Sinnar University Faculty of Medicine and Health Sciences

March 20, 2023

Abstract

We report a case of 22 years old male who presented with headache,bodyaches,cough,fever,vomiting,and diarrhea for short duration. investigations showed features of hypogonadism due to pituitary macroadenoma.He had long history of recurrent attacks of anemia and diarrhea, his anemia was due to MAHA. serial endoscopies and colonoscopies showed features of IBD.

Hypogonadism due to pituitary macroadenoma with inflammatory bowel disease and hemolytic anemia in a 22 years old Sudanese patient.

CASE REPORT STUDY

Authors:

A\First authors : FADI M. TOUM AHMED 1, FAYHAA MAHMOOD MADANI MAHMOOD 2

B\Second authors :DANIA ABDALLA HASSAN DIAB 3, MOJAHID ALTEIB YOUSIF ALTEIB 4, MONZER MOHAMMED ALMAHDI ALI SAIFALDEEN 5

C\Third authors :SAMER MOHAMMED AHMED BALLA 6, AHMED BABIKER ELTAYP MOHAMMED 7, KHALID ALI MUSTAFA FADLALLAH 8, MOHAMMED FAISAL ABBAS BABIKIR 9 ,YASIR AHMED ISMAIL ELDAI10

Affiliation:

1 Internal medicine specialist, sinnar university, sinnar , sudan

2 registrar of internal medicine , sinnar , sudan

3university of sinnar sinnar sudan

4 university of sinnar sinnar sudan

5university of sinnar sinnar sudan

6university of sinnar sinnar sudan

7university of sinnar sinnar sudan

8 university of sinnar sinnar sudan

9 university of sinnar sinnar sudan

10 University of sinnar sinnar sudan

Authors Email addresses:1\ fadi.mtoun2022@gmail.com 2\ Fayhaa_mahmood_madani@gmail.com 3/ daniaabudallah@gmail.com 4/ mogahedhalaly12389@gmail.com 5/ mohammedalmahdimonzer@gamil.com 6/ samermohammed0303@gmil.com 7/ ahmedbabiker2000a@gmail.com 8/ khalidelmustafa1226@gmail.com 9/ mohammed.f.a.babikir@gmail.com 10/ yasoahmed270@gmail.com

Abstract

We report a case of a Patient who presented in our medicine department with headache and body aches for 3 days, cough and fever for 2 days, vomiting, and diarrhea for 1 day.

On physical examination, the patient showed features of thalassemia and hemic murmur over the pericardium. He was suffering from a long history [for more than 10 years] of recurrent attacks of anemia at the frequency of one admission every 2 months, and every time was receiving blood and also has a history of bloody diarrhea 3 times before, and recurrent diarrhea since 2010, HB electrophoresis was normal, and serial upper GI endoscopy was done the last one showed mild erosion in the stomach and duodenum. also, a serial colonoscopy done in the last one showed multiple erosive and skip lesions, and a biopsy was taken and the result showed lymphocytic infiltration , which confirmed inflammatory bowel disease. hormonal analysis was done and showed features of hypogonadism and imaging revealed a pituitary macroadenoma.

1-Introduction

Hypogonadism is a typical endocrine disorder. A man is considered to have hypogonadism according to the Endocrine Society if he exhibits symptoms and physical manifestations of a low level of free or total testosterone in his blood as well as clear-cut, consistent low serum levels of these substances. In contrast, the 2018 definition of hypogonadism by the American Urological Association employs a blood total testosterone level < 300 ng/dL in conjunction with hypogonadism-related symptoms or signs. The doctor must assess the levels of serum luteinizing hormone and follicle-stimulating hormone to distinguish between primary (testicular) and secondary (pituitary-hypothalamic or central) hypogonadisms. Therefore, one must explore possibly reversible reasons in the hypothalamus-pituitary axis if gonadotropins are low or inappropriately normal. In such cases, serum prolactin and iron levels should also be checked. Other pituitary hormone assessments including pituitary magnetic resonance imaging (MRI) may be required when clinically needed. In the event that a pituitary adenoma is suggested by severe pituitary hormone abnormalities, such as increased serum prolactin or MRI(1)

Inflammatory bowel disease has a consistently rising prevalence, has been an issue in healthcare across the world. It comes in two main varieties: ulcerative colitis (UC) and Crohn's disease (CD), which are separate inflammatory chronic bowel diseases that relapse often. Any area of the digestive system can be affected by CD, which can produce transmural inflammation. The perianal region or terminal ileum are the most often affected areas. A CD is frequently accompanied by problems such abscesses, fistulas, and strictures, unlike UC. The colon is the only part of UC that affects patients and it is characterized by mucosal inflammation.(2).

A subgroup of hemolytic anemia known as microangiopathic hemolytic anemia (MAHA) is characterized by fragmentation and hemolysis brought on by injury to erythrocytes in the tiny blood capillaries.(3)

2-PATIENT INFORMATION

Our patient is 22 years old man who presented on 28/1/2022 complaining of headache and body ache for 3 days, cough and fever for 2 days, vomiting, and diarrhea for 1 day. His condition started with the gradual onset of a moderate headache all over the head associated with fever (which was low grade mainly in the evening, not associated with rigor or chills), the headache was also associated with neck pain, and not associated with bullring of vision or projectile vomiting. The cough was dry and associated with stapping

chest pain all over the chest which was aggravated by the cough without shortness of breath. The vomiting was small in volume, 3 times daily, aggravated by cough, and contains food particles not associated with nausea or abdominal pain. The diarrhea was also small in volume in form of loose stool and does not contain blood or mucous.

Other systems were unremarkable in history.

Regarding his past medical history, the patient had been suffering from a long history (for more than 10 years) of recurrent hospital admission due to recurrent attacks of anemia at the frequency of one admission every 2 months, and every time was receiving blood, and also has a history of bloody diarrhea 3 times before, and recurrent diarrhea since 2010.

The patient had undergone an appendectomy in July 2021. The patient is not diabetic or hypertensive. many investigations were done to reach the diagnosis as I'll describe below. His drug, family, and social history were unremarkable.

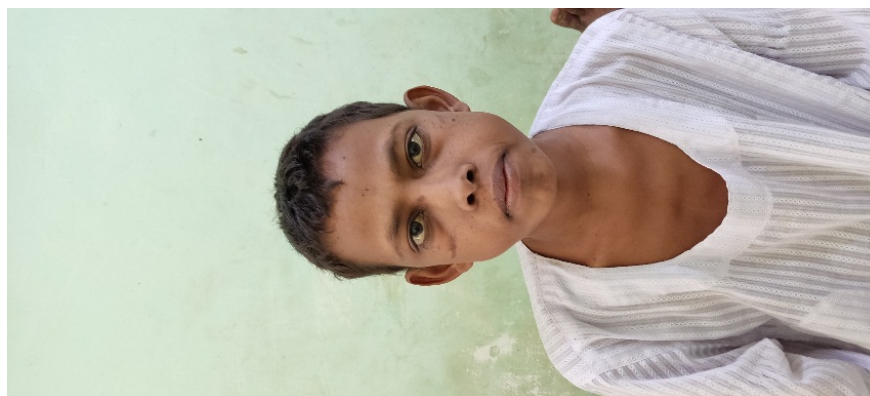

FIGURE1 patient picture, he had features of thalassemia.

3-EXAMINATION

Examination revealed a fully conscious patient (GCS=15), puls 124 beats per minute, and blood pressure was 100/70mmhg. He was pale and his face shows features of thalassemia. His cardiac examination revealed normal first and second heart sound with a humic murmur all over the pericardium. Other systems were clear on examination.

4-INVESTIGATION

On presentation his blood test showed hemoglobin=6.7 g/dl, mean corpuscular volume =87.5 fl, platelets=319 x 10³/Cmm, and WBCs = 8.8 x 10³. urine analysis the pus cells count was 18-20/HPF, RBCs count (was 5-7)/HPF. renal function test was normal, electrolyte showed hyponatremia, hypokalemia, and hypocalcemia. The widal test for brucella was insignificant. No malaria parasites have been seen in the blood film. TSH= 2.69, LFT showed AST 21, ALT 15, ALP 159. Abdominal X-ray showed distended large bowel with an air-fluid level. upper GI endoscopy was done showing several 2mm red spots in the upper body of the stomach. Abdomino-pelvic U/S was done and was normal apart from hepatomegaly. echocardiography was done and was normal. hormonal analysis was done and showed features of hypo gonads (LH, FSH, and testosterone were low), MRI brain was done and showed pituitary macro adenoma. analysis for somatomedin c was done and was on the lower limit of normal, prolactin level done and was normal.

Investigation done regarding his long-standing problems of recurrent anemia, and bloody diarrhea: hemoglobin electrophoresis done was normal, upper GI endoscopy done show mild lower-end esophagitis with incompetent cardia, Colonoscopy was done showed inflamed internal piles, serum amylase = 2064 U/L. Bone marrow aspiration was done and showed hypercellular bone marrow with no abnormal infiltration.

CT's Chest and abdomen did and were normal. bilirubin, LDH, serum ferritin, and serum iron were low, B12 level was high, and BUN/crt was normal. reticulocyte count was low, the direct coombs test was negative and the viral screen was negative, the folate level was negative, and the gliadin screen was less than 0.6.

The last upper GI endoscopy show mild erosion in the stomach and duodenum, and a colonoscopy was done and showed multiple erosive and skip lesions, and biopsy was taken and the result showed lymphocytic infiltration.

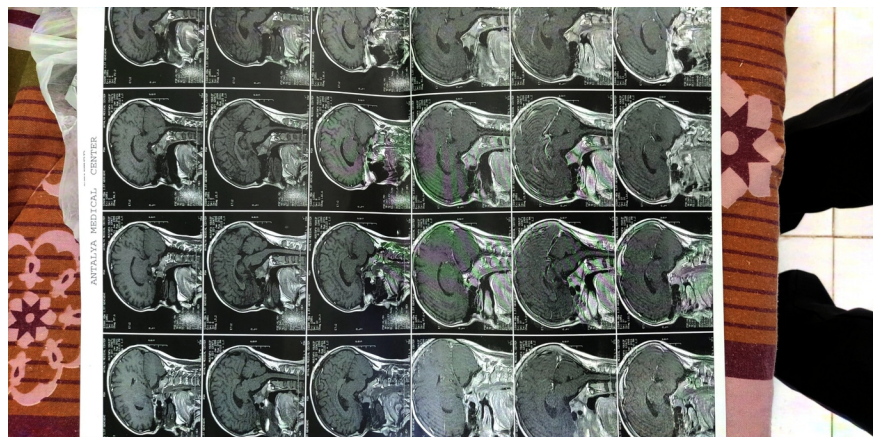


FIGURE 2 MRI Brain showing pituitary macroadenoma

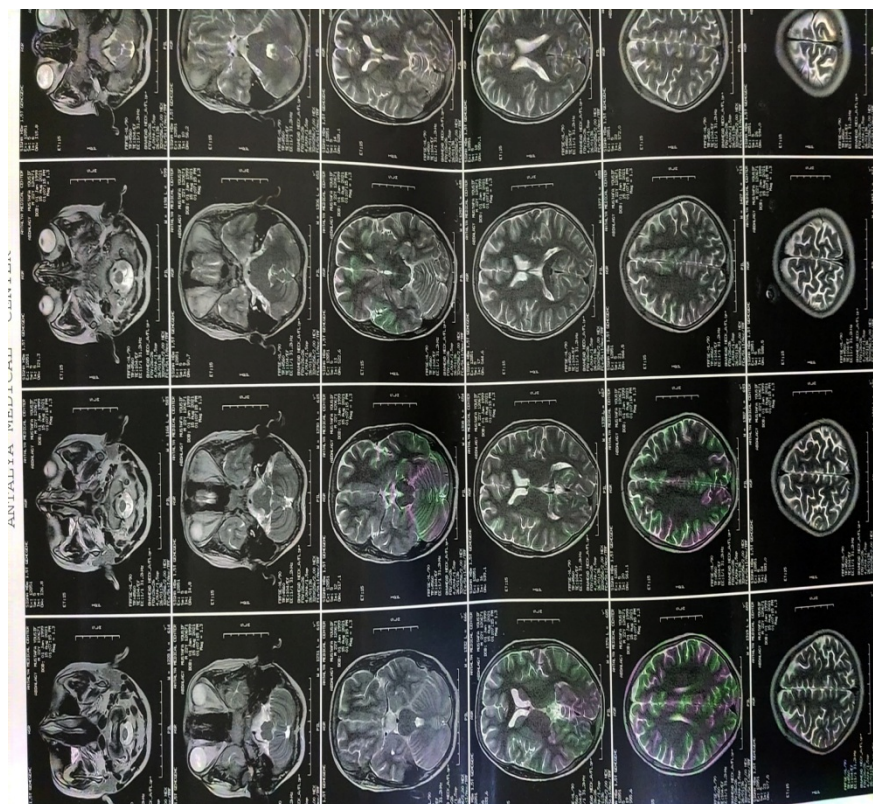


FIGURE3 Show well defined lesion involving the pituitary fossa, mostly represented pituitary macroadenoma.

5-TREATMENT AND FOLLOW UP

About the treatment patient received On the 1st day the patient received blood, potassium, and calcium.

On the 2nd day, the patient developed atrial fibrillation his blood pressure was normal, and no signs of heart failure, and received bisoprolol. TSH was 2.69.

In the 3rd day LFT showed AST = 21, ALT = 15, ALP = 159. At the end of the 3rd day, the patient complained of abdominal pain and absolute constipation since admission, on examination, there was mild abdominal distention with a resonant percussion note, and the patient then was examined by surgical department doctors and there was no fecal impaction on rectal examination, and serum electrolytes and abdominal x-ray (erect and supine) was requested, and patient puted in fasting and IV fluids and potassium.

On the 4th day, serum electrolytes were repeated and showed: Serum Na+ = 134.4 mEq/L, Serum K+= 6.02 mEq/L. Abdominal X-ray showed distended large bowel with an air-fluid level.

On the fifth-day serum electrolytes were repeated and serum K+ =2.84 and serum Na+ = 129.9.

At the end of the fifth day, the patient passed stool. On the 8th day, the patient was discharged in good clinical condition with no symptoms and normal Hb and serum electrolytes.

3 days after admission on 7/feb/2022 the patient returned presenting massive black diarrhea.On examination, he was pale and tachycardic.The patient was stabilized and prepared for an endoscopy the next day.Endoscopy was done and show mild erosion in the stomach and duodenum. The day after, the patient was prepared and a colonoscopy was done which showed multiple erosive and skip lesions, and biopsy was taken and the result showed lymphocytic infiltration

6- DISCUSSION

A typical endocrine disorder is hypogonadism. A man is considered to have hypogonadism according to the Endocrine Society if he exhibits symptoms and physical manifestations of a low level of free or total testosterone in his blood as well as clear-cut, consistent low serum levels of these substances. The 2018 definition of hypogonadism by the American Urological Association, on the other hand, combines symptoms or indicators of hypogonadism with a blood total testosterone level below 300 ng/dL. In order to distinguish between main and secondary (testicular) and Utilizing serum luteinizing hormone and follicle-stimulating hormone concentrations, one can identify secondary (pituitary-hypothalamic or central) hypogonadisms. In light of this, one must take the hypothalamus-pituitary axis into account if gonadotropin levels are low or abnormally normal. Serum prolactin as well as iron levels have to be assessed in such situations. Other pituitary hormone tests including magnetic resonance imaging (MRI) of the pituitary may be required when clinically needed. If a pituitary adenoma is suspected as a result of substantial pituitary hormone abnormalities, such as high serum pro-lectin or MRI (1). An MRI of the brain was performed in our instance and revealed a pituitary mega adenoma, confirming the patient's hypogonadism. Hormonal study was performed, and the findings indicated hallmarks of hypogonadism based on low levels of LH, FSH, and testosterone in the lab.IBD, which has a consistently rising prevalence, has been an issue in healthcare across the world. It comes in two main varieties: ulcerative colitis (UC) and Crohn's disease (CD), which are separate inflammatory chronic bowel diseases that relapse often. Any area of the digestive system can be affected by CD, which can produce transmural inflammation. The perianal region or terminal ileum are the most often affected areas. In contrast to UC, CD frequently results in problems such abscesses, fistulas, and strictures. While UC is confined to the colon and is characterized by mucosal inflammation(2). Bloody diarrhea was the first symptom that our patient had experienced, and he had previously experienced it three times.and colonoscopies were performed repeatedly due to persistent diarrhea since 2010. In the stomach and duodenum, the most recent endoscopic revealed little erosion. A biopsy was performed after the most recent colonoscopy, which revealed several erosive and skip lesions. The biopsy's results revealed lymphocytic infiltration.

Among the subtypes of hemolytic anemia, known as microangiopathic hemolytic anemia (MAHA), there is fragmentation and hemolysis brought on by erythrocyte destruction in the tiny blood vessels (3). The patient was responding well to immunosuppressive medications (steroids) and hydroxychloroquine when we started them, and the patient showed a dramatic improvement in the hemoglobin level and no more hemolysis. Since starting treatment, there has been no history of blood transfusion. The patient had electrolyte disturbance, subacute intestinal obstruction brought on by paralytic ileus, therapy for hypokalemia, and correction of the patient's hypocalcemia all led to a worsening of the case's circumstances.

Because the patient's most recent episodes of hypokalemia and sepsis did not improve with therapy, the patient's decline and reason of death remained unknown. There have never been any records of cases like the one in our case presentation. We hypothesize that the reason may be because recognizing this sickness may be challenging in low-resource countries like Sudan. The availability of complex investigation modalities outside of big cities can be a significant hurdle when it comes to detecting people with suspected hypogonadism caused by macroadenoma and hemolytic anemia with inflammatory bowel disease..

7- Conclusion

Even though it's an uncommon occurrence, a patient from Sudan who is 22 years old and has hemolytic anemia, inflammatory bowel disease, and hypogonadism as a result of a pituitary macroadenoma should be remembered. Regarding his prior medical history, the patient had a lengthy (more than 10 years) history of recurrent hospital admissions due to recurrent attacks of anemia at a frequency of one admission every two months, and every time was receiving blood. The patient also had a history of bloody diarrhea three times before, and recurrent diarrhea since 2010, particularly when the patient presented with the headache associated with neck pain, cough vomiting, and diarrhea. Investigations have supported the patient's previous medical history that macroadenoma causes hypogonadism. When the patient was last admitted, they had severe black diarrhea. An endoscopic revealed minor erosion in the stomach and duodenum. Multiple erosive and skip lesions were seen during a colonoscopy, and when a biopsy was performed, the finding of lymphocytic infiltration proved the presence of Crohn's disease.

When the patient first presented, he often had low hemoglobin levels and clinical signs of thalassemia, which led us to suspect hemolytic anemia. The patient was given hydroxychloroquine and steroids, and he responded well. Hemoglobin electrophoresis was used to rule out sickle cell anemia and thalassemia, which excludes them. Instead, we advised microangiopathic hemolytic anemia.

The patient, however, got therapy and was closely monitored when this diagnosis was determined after a protracted investigation and flow up. Sadly, the patient's condition worsened until he passed away from sepsis, hypokalemia, and sequences of hypokalemia that did not respond to therapy.

ACKNOWLEDGMENT

Not applicable

CONFLICTS OF INTEREST

The authors report no conflict of interest

AUTHOR CONTRIBUTIONS

All authors participated in planning the study. FMT and FMM collected data and did investigations and examinations, and wrote the first draft. DAH, MAY, and MMA supervised the process of study and revised the draft. All authors participated significantly in writing the draft.

ETHICAL APPROVAL

Ethics approval was obtained from the Ethical committee at the University of ALgazera and informed consent was taken from the patient for purposes of publication.

CONSENT

Written informed consent was obtained from the patient for publication of this case report and accompanying images.

DATA AVAILABILITY STATEMENT

The data that support the findings of this study are available with the corresponding author upon reasonable .

REFERENCES

1. Levy S, Arguello M, Macki M, Rao SD. Pituitary Dysfunction Among Men Presenting with Hypogonadism. 2019;
2. Zhang Y, Li Y. Inflammatory bowel disease : Pathogenesis. 2014;20(1):91–9.
3. Thomas MR, Scully M. How I treat microangiopathic hemolytic anemia in patients with cancer. 2021;137(10):1310–7.