

MID – TERM POST-OPERATIVE OUTCOME OF SINUS VENOSUS ATRIAL SEPTAL DEFECT WITH ANOMALOUS PULMONARY VENOUS CONNECTION WITH DIFFERENT SURGICAL STRATEGIES AND THEIR EFFECT ON SINUS NODE FUNCTION AND LATE VENOUS OBSTRUCTION.

Vishal V. Bhende¹, Tanishq S. Sharma², Deepakkumar V. Mehta³, Bhadra Y. Trivedi⁴, Amit Kumar⁵, Viral B. Patel⁶, Gurpreet Panesar⁷, Kunal Soni⁸, Kartik Dhami⁷, Nirja Patel⁹, Sohilkhan R Pathan¹⁰, and Hardil P. Majmudar¹¹

¹Consultant, Pediatric Cardiac Surgery, Bhanubhai and Madhuben Patel Cardiac Centre, Shree Krishna Hospital, Karamsad, Anand, Gujarat-388 325, India.

²Corresponding Author, Pediatric Cardiac Surgery, Bhanubhai and Madhuben Patel Cardiac Centre, Karamsad, Gujarat -388 325, India.

³Professor & Head, Department of Radiodiagnosis & Imaging, Pramukhswami Medical College & Shree Krishna Hospital, Bhalka University, Karamsad, Anand, Gujarat -388 325, India.

⁴Consultant, Pediatric Interventional Cardiologist, Bhanubhai and Madhuben Patel Cardiac Centre, Shree Krishna Hospital, Karamsad, Anand, Gujarat-388 325, India.

⁵Consultant, Pediatric Cardiac Intensivist, Bhanubhai and Madhuben Patel Cardiac Centre, Karamsad, Anand, Gujarat-388 325, India

⁶Professor, Department of Radiodiagnosis & Imaging, Pramukhswami Medical College & Shree Krishna Hospital, Bhalka University, Karamsad, Anand, Gujarat -388 325, India.

⁷Consultant, Cardiac Anaesthesiology, Bhanubhai and Madhuben Patel Cardiac Centre, Shree Krishna Hospital, Karamsad, Anand, Gujarat - 388 325, India.

⁸Consultant, Cardiac Anaesthesiology, Bhanubhai and Madhuben Patel Cardiac Centre, Shree Krishna Hospital, Karamsad, Anand, Gujarat -388 325, India.

⁹Fellow, Cardiac Anaesthesiology, Bhanubhai and Madhuben Patel Cardiac Centre, Shree Krishna Hospital, Karamsad, Anand, Gujarat-388 325, India.

¹⁰Clinical Research Co-ordinator, Bhanubhai and Madhuben Patel Cardiac Centre, Shree Krishna Hospital, Karamsad, Anand, Gujarat -388 325, India.

¹¹Bhanubhai and Madhuben Patel Cardiac Centre

January 20, 2022

Introduction

Sinus venosus atrial septal defects (SVASDs), originally described in 1858, account for approximately 4%-11% of all atrial septal defects (ASDs) [1,2]. The typical SVASD is an interatrial communication that results from a deficiency of the common wall between the superior vena cava (SVC) and the right-sided pulmonary

veins[2,3]. SVASD is commonly associated with anomalous pulmonary venous connections (APVCs) involving some or all of the pulmonary veins[3,4], which produces additional left-to-right shunting. The basic principle of repair is redirection of the APVC through the interatrial communication into the left atrium.

In contrast to operative repair of secundum ASD, the surgical approach for SVASD is more complex and carries the risk of stenosis of the SVC or pulmonary veins, residual shunting, and sinus node dysfunction[4].

We reviewed outcomes for patients who underwent SVASD repair at Bhanubhai and Madhuben Patel Cardiac Centre, Karamsad, Anand, Gujarat, India, with a focus on patient survival and development of arrhythmias.

Materials & Methods

The Institutional Ethics Committee (IEC-2) of the Bhanubhai and Madhuben Patel Centre for Medical Care and Education, Anand, Gujarat, India, approved this study (Approval number - IEC/BU/2021/Cr.48/283).

We identified 10 patients from our computerized cardiovascular database (FTP 192.168.0.5) who underwent primary surgical repair of SVASD between December 2018 and October 2021 (Table 1). Their mean age was 3.7 years (median, 3.5; range, 1-8 years). Seven patients were boys and 3 were girls. One patient (P10) had left upper PAPVC without SVASD and was included in the study for purposes of comparison.

Drainage of the PAPVC was directly to the right atrium-superior vena cava (RA-SVC) junction in the 9 patients with SVASDs; in the other patient (P10), the left upper lobe of the lung exhibited partial anomalous venous drainage through a vertical vein, which in turn drained into the brachiocephalic vein; this scenario was suggestive of partial anomalous pulmonary venous drainage (PAPVD).

TABLE – 1
MATRIX OF THE STUDY POPULATION UNDERGOING SINUS VENOSUS – ATRIAL SEPTAL DEFECT REPAIR BY VARIOUS TECHNIQUES

SR.NO.	PATIENT PRO- FILE	AGE @ RE- PAIR	SEX	WEIGHT	BVC	CPB TIME	ACC TIME	TECHNI- QUE EM- PLOYED	HOSPITAL FROM DATE x	INTRA- OPERATIVE FINDINGS	2-D ECHO CAR- DIO- GRAPHY AT DIS- CHARGE	CHARGES
1	Miss D {P1}	4 Years	Female	11.8 kgs.	Single	104 Min.	71 Min.	Sandwich / Single- Patch	5 Days	SVC 16/13(15) mm Hg SVC- RA junc- tion 15 mm Hg Mid- RA cavity 11/04(08) mm Hg	Flow acceler- ation at SVC to RA junc- tion with gradi- ent of 4/2 (peak/mean) mm Hg	

SR.NO.	PATIENT PRO- FILE	AGE @ RE- PAIR	SEX	WEIGHT	SVC	CPB TIME	ACC TIME	TECHNI- QUE EM- PLOYED	HOSPITAL STAY FROM DOSx	INTRA- OPERATIVE IN- PRES- SURES	2-D ECHO INTRA- OPERATIVE IN- OPERATIVE GRAPHY AT DIS- CHARGE
2	Master S {P2}	1 Years	Male	6.9 kgs.	Single	98 Min.	68 Min.	Sandwich / Single- Patch	8 Days	-	There is tur- bulence in the super- ior vena cava to right atrium junc- tion with peak gradi- ent of 18 mm Hg and mean gradi- ent of 18 mm Hg.
3	Master R {P3}	1 Years	Male	7.8 kgs.	Bilateral	98 Min.	68 Min.	Two- Patch	8 Days	SVC 9 mm Hg; RA 2 mm Hg	There is tur- bulence at the Right SVC to RA junc- tion with gradi- ent of 8.5/4.2 (peak/mean) mm Hg.

SR.NO.	PATIENT PRO- FILE	AGE @ RE- PAIR	SEX	WEIGHT	SVC	CPB TIME	ACC TIME	TECHNI- QUE EM- PLOYED	HOSPITAL STAY FROM DOSx	INTRA- OPERATIVE IN- SIVE PRES- SURES	2-D ECHO CAR- DIO- GRAPHY AT DIS- CHARGE	REMARKS
4	Miss A {P4}	1 Years	Female	6.8 kgs.	Single	97 Min.	66 Min.	Two- Patch	10 Days	SVC 5 mm Hg; RA 1 mm Hg	There is tur- bulence from SVC to RA with gradi- ent of 9/5 (peak/mean) mm Hg.	N
5	Master M {P5}	8 Years	Male	18.40 kgs.	Single	120 Min.	77 Min.	Two- Patch	10 Days	SVC 5 mm Hg; RA 2 mm Hg	WNL	N
6	Master A {P6}	3 Years	Male	12.0 kgs.	Single	103 Min.	79 Min.	Two- Patch	8 Days	SVC 8 mm Hg; RA 8 mm Hg	WNL	N
7	Miss A {P7}	4 Years	Female	12.0 kgs.	Bilateral	113 Min.	82 Min.	Two- Patch	9 Days	SVC 8 mm Hg; RA 5 mm Hg	WNL	N
8	Master S {P8}	5 Years	Male	15.39 kgs.	Single	84 Min.	54 Min.	Two- Patch	8 Days	SVC 5 mm Hg; RA 10 mm Hg	WNL	N
9	Master N {P9}	3 Years	Male	11.4 kgs.	Bilateral	117 Min.	67 Min.	Two- Patch	8 Days	SVC 9 mm Hg; RA 5 mm Hg	WNL	N

SR.NO.	PATIENT PRO- FILE	AGE @ RE- PAIR	SEX	WEIGHT	SVC	CPB TIME	ACC TIME	TECHNI- QUE EM- PLOYED	HOSPITAL STAY FROM DOSx	INTRA- OPERATIVE PRES- SURES	2-D ECHO CAR- DIO- GRA- PHY AT DIS- CHARGE	M
10	Master P {P10}	7 Years	Male	20.0 kgs.	Single	150 Min.	106 Min.	Left PA- PVC Re- routing + ASD Closure + Pul- monary Valvotomy	6 Days	-	WNL	M

N.B. :

RA- Right Atrium, SVC – Superior Vena Cava, CPB – Cardio-pulmonary Bypass, ACC-Aortic Cross-clamp, PAPVC – Partial Anomalous Pulmonary Venous Connection, ASD – Atrial Septal Defect, WNL – Within Normal Limits

Codes for Patients – Miss D (P1), Master S (P2), Master R (P3), Miss A (P4), Master M (P5), Master A (P6),

Miss A(P7), Master S (P8), Master N (P9), Master P (P10)

ECHOCARDIOGRAPHIC DATA –

All 10 patients enrolled in the study underwent 2-D Echocardiography pre-operatively and also post-operatively at the time of discharge.

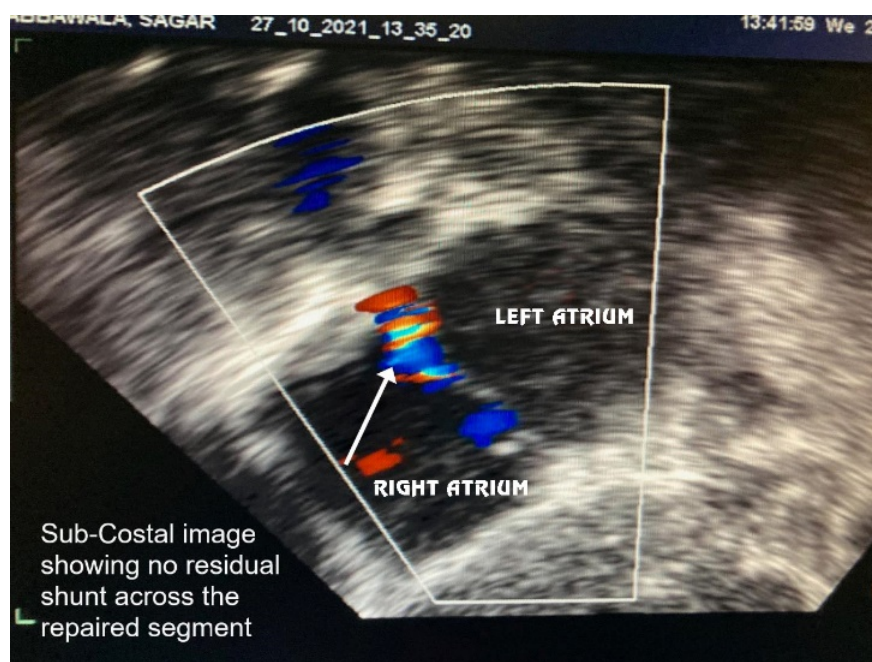
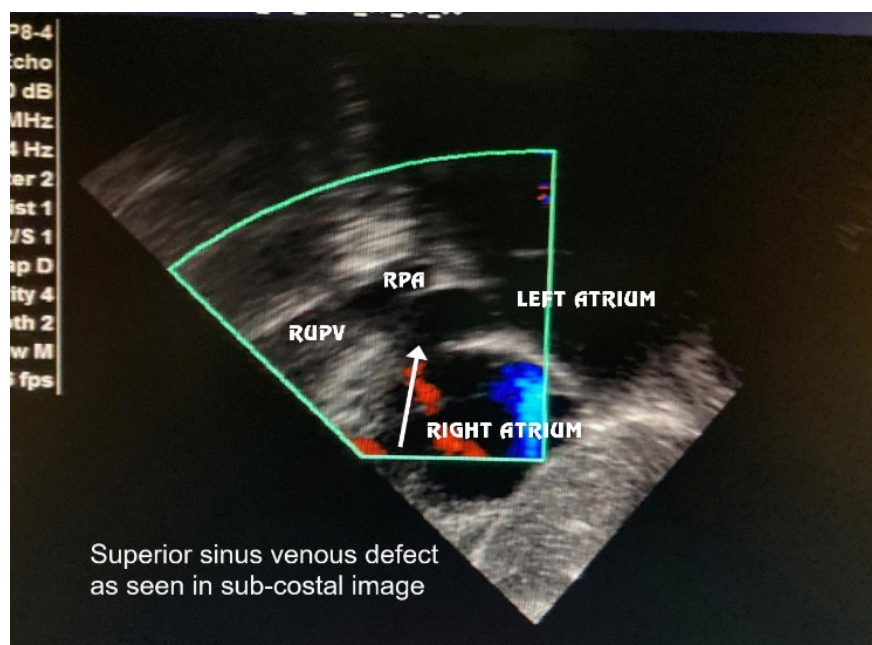


Figure 1 : PRE-OPERATIVE 2-D ECHOCARDIOGRAPHY FOR P 9 PATIENT
Figure 2 : POST-OPERATIVE 2-D ECHOCARDIOGRAPHY FOR P 9 PATIENT

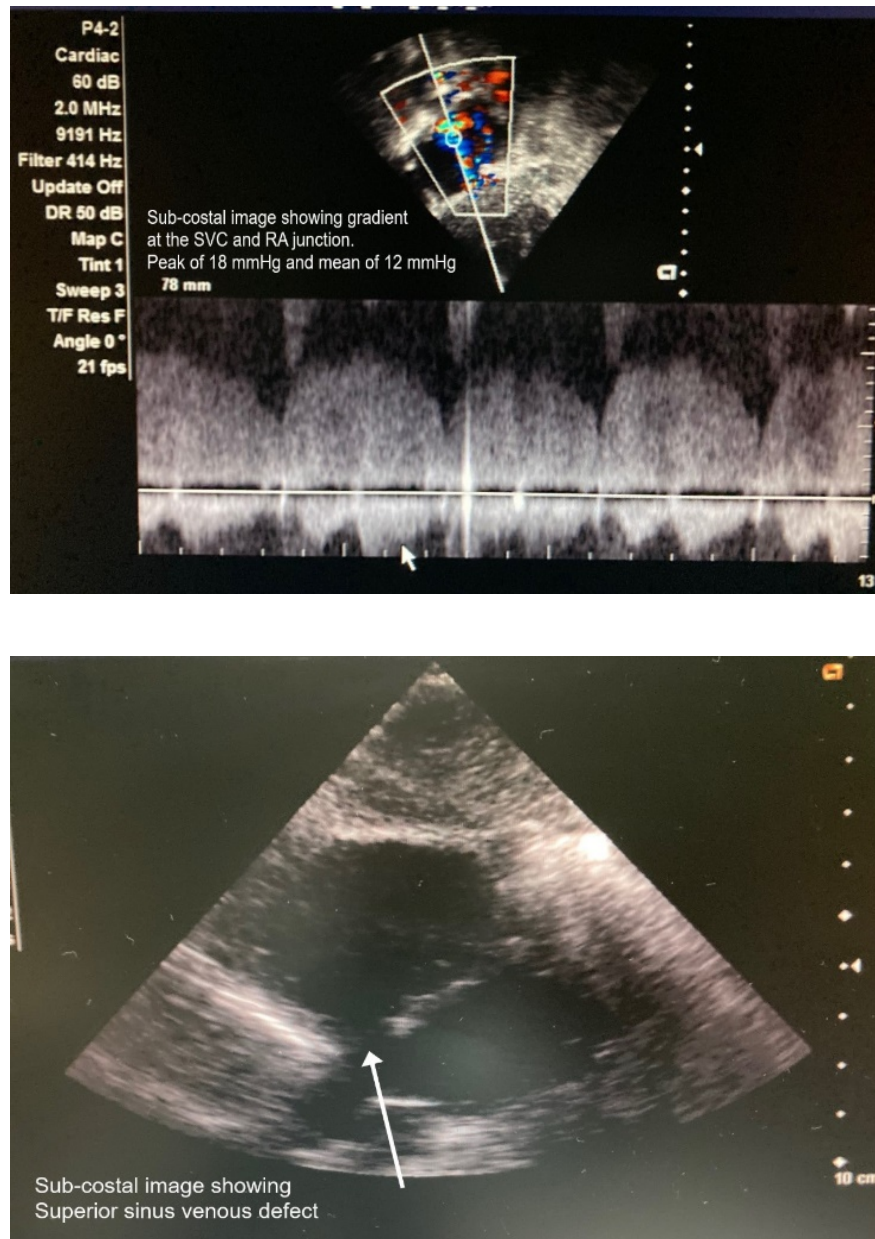


Figure 3 : PRE-OPERATIVE 2-D ECHOCARDIOGRAPHY FOR P 1 PATIENT
Figure 4 : POST-OPERATIVE 2-D ECHOCARDIOGRAPHY FOR P 2 PATIENT

(Image Credits, Figure 1 – 4 : Dr.Bhadra Y. Trivedi)

Dynamic cardiac computed tomography

Dynamic cardiac computed tomography (CT) was performed preoperatively in our series for two patients. In patient P4, intracranial arteriovenous malformations were strongly suspected of leading to dilatation of the SVC. Dynamic cardiac CT revealed a moderately large ASD (superior sinus venous type; Figures 5 to 8). The right superior pulmonary vein drained into the terminal portion of the SVC. This scenario was

suggestive of both PAPVC and PAPVD. The main, right, and left pulmonary arteries were dilated, which was suggestive of pulmonary arterial hypertension. The left vertebral artery arose directly from the aortic arch as a third branch. The proximal, middle, and distal diameters of the SVC each measured approximately 8.7 mm.

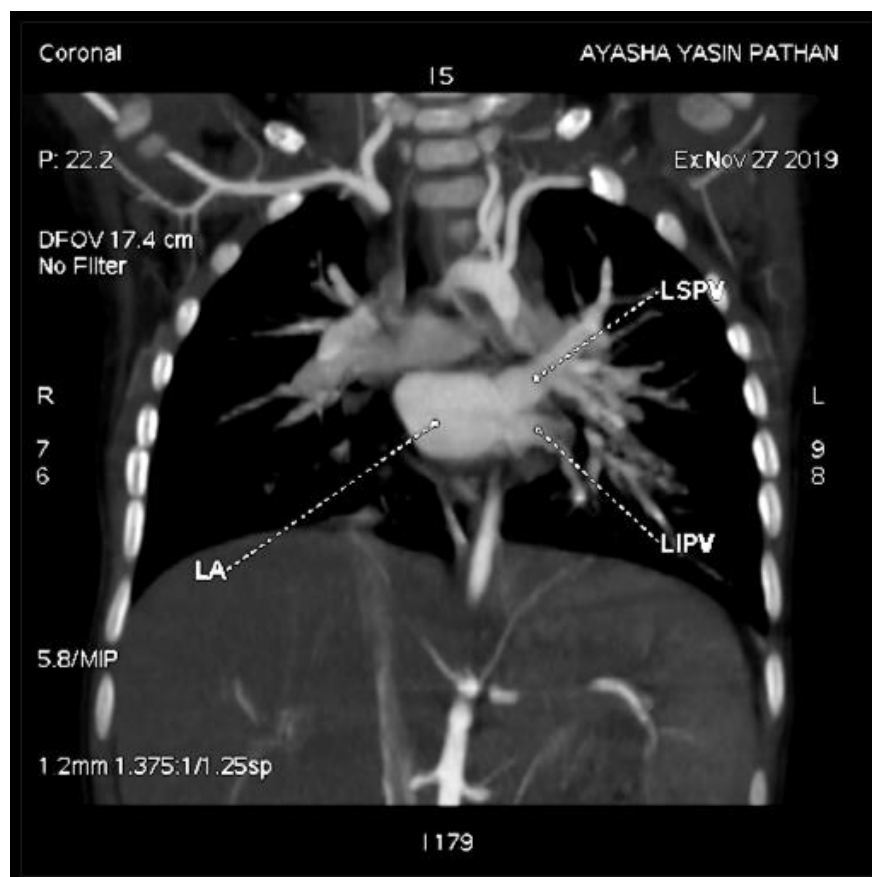
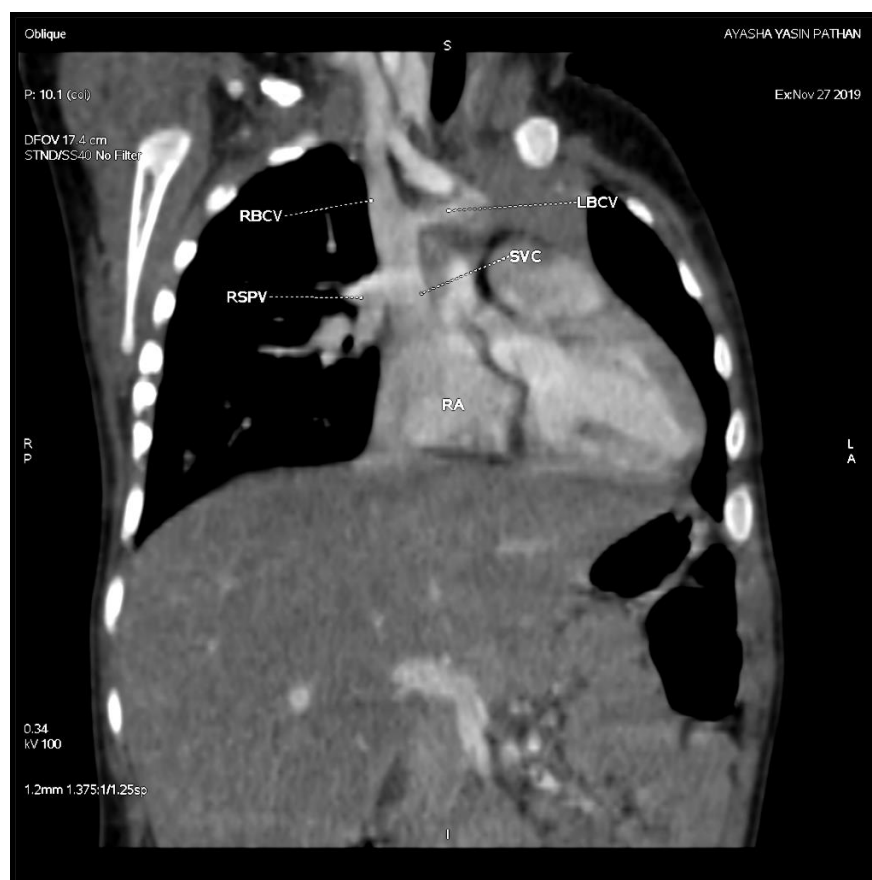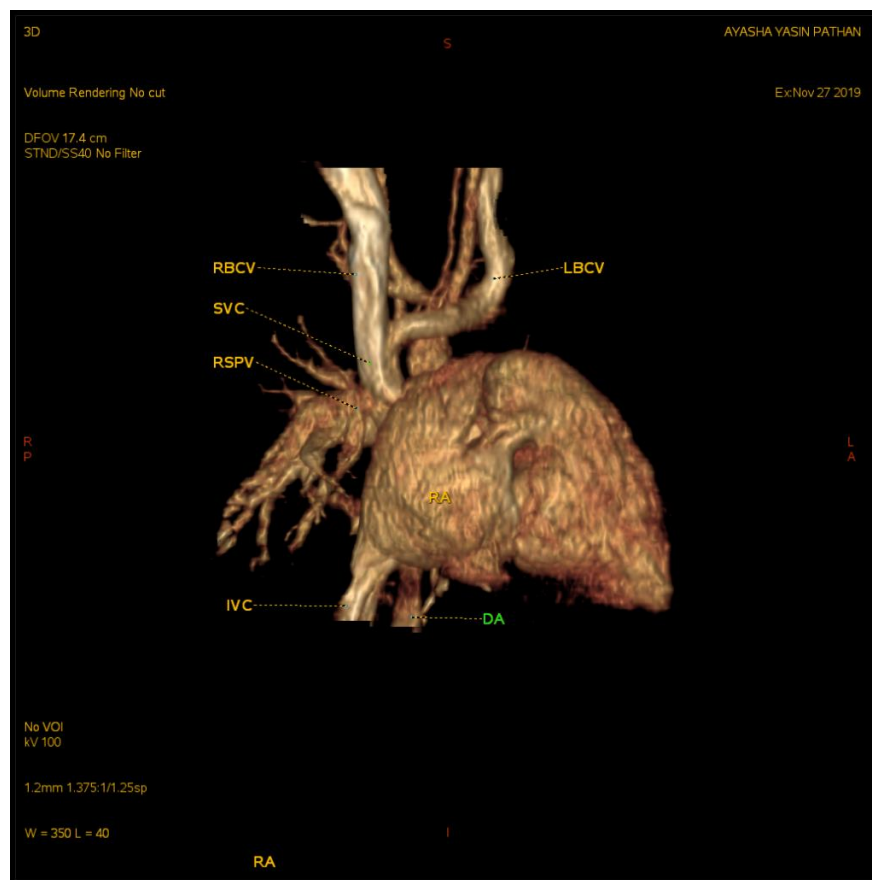




Figure 5 : MAXIMUM INTENSITY PROJECTION-CORONAL VIEW- PROJECTION-LA & LSPV & RSPV OPENING IN SVC IN P 4 PATIENT

Figure 6 : MAXIMUM INTENSITY PROJECTION-LIPV-CORONAL VIEW IN P 4 PATIENT



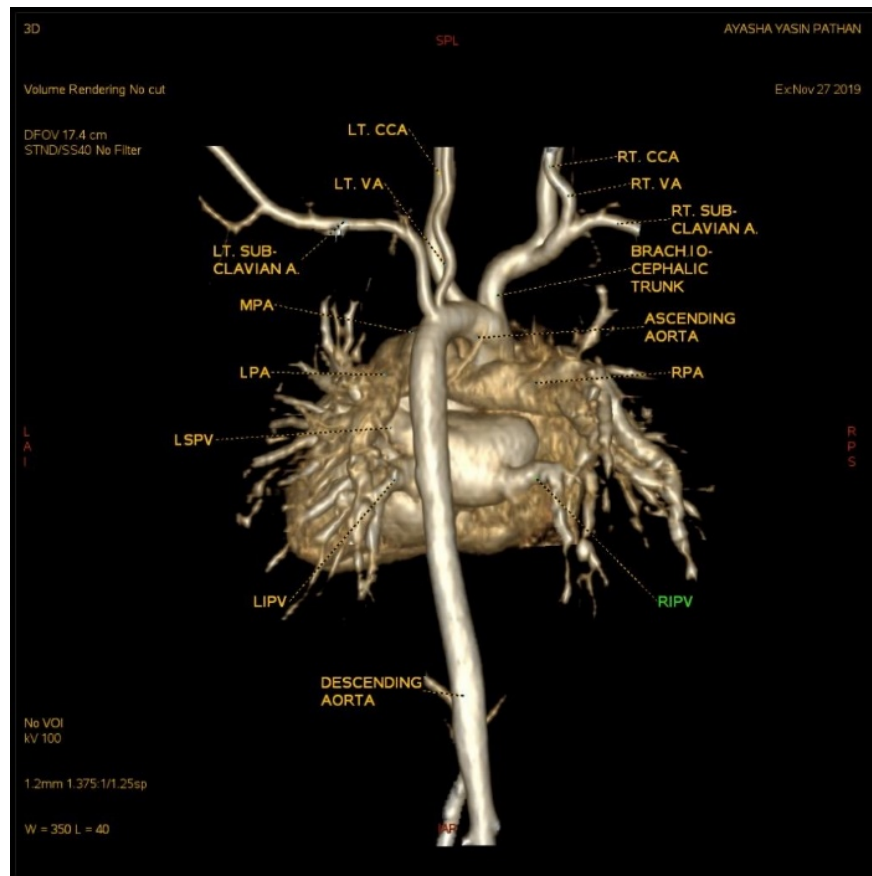


Figure 7 : VOLUME RENDERING- Figure 8 : VOLUME RENDERING-
ANTERIOR VIEW – CT CARDIAC POSTERIOR VIEW - CT CARDIAC
DYNAMIC STUDY IN P 4 PATIENT DYNAMIC STUDY IN P 4 PATIENT
(Image Credits, Figure 5 – 8 : Dr.Deepakkumar V. Mehta)

In patient P10, left-sided partial pulmonary venous connection to the innominate vein was suspected, and cardiac CT and pulmonary angiography were performed to confirm this (Figures 9 and 10). Dynamic cardiac CT of the upper lobe of the left lung revealed partial anomalous venous drainage through a vertical vein, which in turn drained into the brachiocephalic vein; this scenario was suggestive of PAPVD. The hemiazygos vein drained posteriorly into an anomalous vertical vein at the lower border of the T4 vertebral level, which was 1.7 cm below the confluence of anomalous vertical vein and the brachiocephalic vein. The distance from the anomalous vein hilum to the opening of the hemiazygos vein was 1.3 cm. The other three pulmonary veins drained into the left atrium.

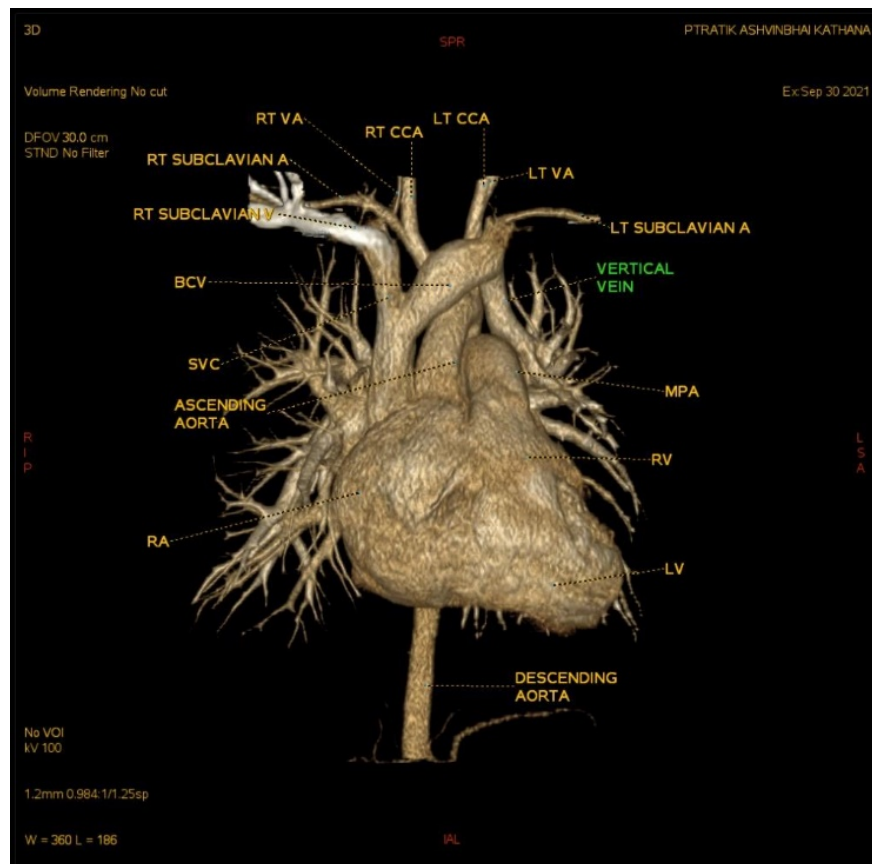


Figure 9 : VOLUME RENDERING-ANTERIOR VIEW – CT CARDIAC DYNAMIC STUDY IN P 10 PATIENT

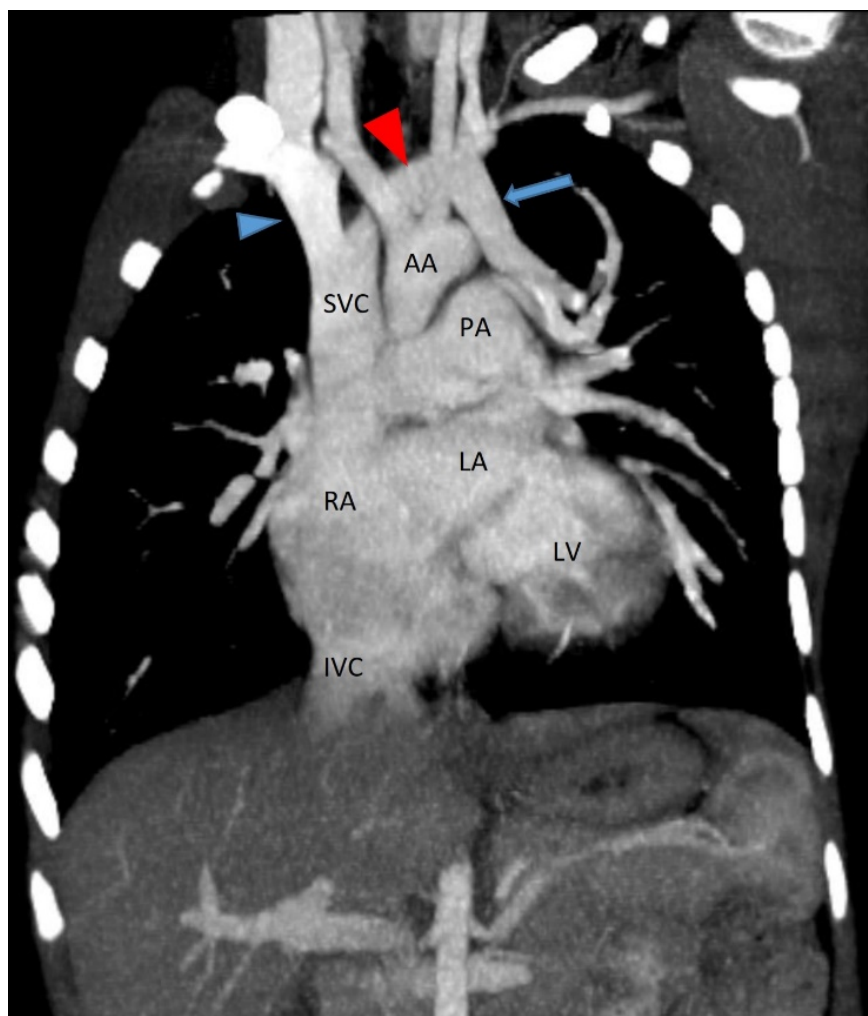


Figure 10 : MAXIMUM INTENSITY PROJECTION CORONAL VIEW – IN P 10
PATIENT

VERTICAL VEIN (BLUE ARROW) (PAPVD FROM LEFT UPPER LOBE OF LUNG) DRAINING INTO
LEFT BRACHIOCEPHALIC VEIN (RED ARROW HEAD)

RIGHT BRACHIOCEPHALIC VEIN (BLUE ARROW HEAD)

AA: ARCH OF AORTA, SVC: SUPERIOR VENA CAVA, PA PULMONARY ARTERY, RA: RIGHT
ATRIUM, LA LEFT ATRIUM, LV: LEFT VENTRICLE, IVC: INFERIOR VENA CAVA

(Image Credits, Figure 9 – 10 : Dr.Viral B. Patel)

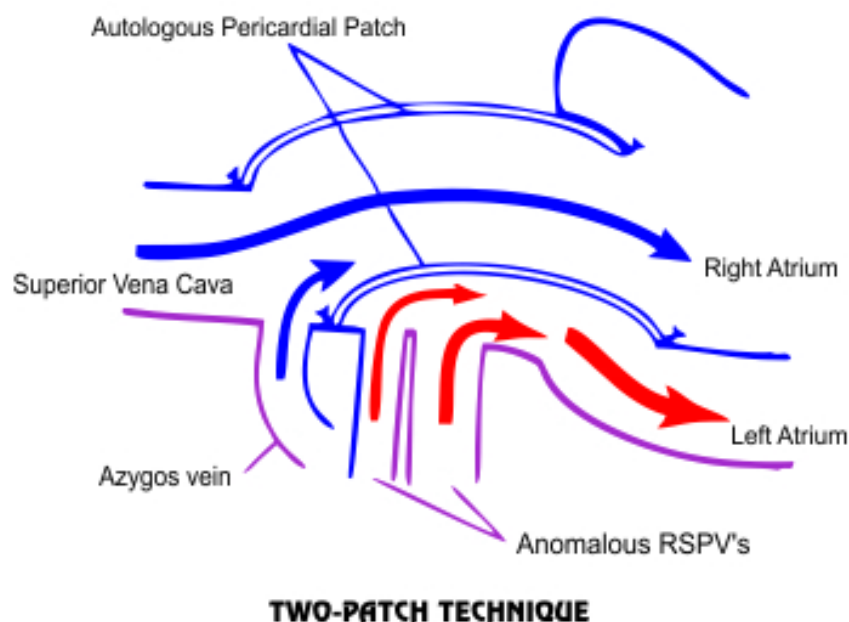
Surgical techniques

All procedures were performed through a median sternotomy. Cardiopulmonary bypass was used with bicaval cannulation in 7 patients and tricaval cannulation in 3 and with ascending aortic cannulation at moderate systemic hypothermia (25oC-32oC) in all patients.

We achieved cardioplegic arrest with Del Nido cardioplegia and topical slush saline. We did not routinely use a left ventricular vent. All patches were made from fresh autologous pericardium. In 2 patients (20%), we

performed single-patch/sandwich-patch repair of the SVASD with inclusion of the PAPVC and ASD closure; in 7 (70%), we performed repair with two pericardial patches to enlarge the SVC-RA junction (Figures 11 to 12).

Stenosis of the SVC and the right-sided pulmonary veins was graded as trivial, mild, moderate, or severe. Preoperative and postoperative electrocardiography (ECG) was performed in all 10 patients. Initial postoperative ECG was considered early, and ECG after hospital discharge was considered late.



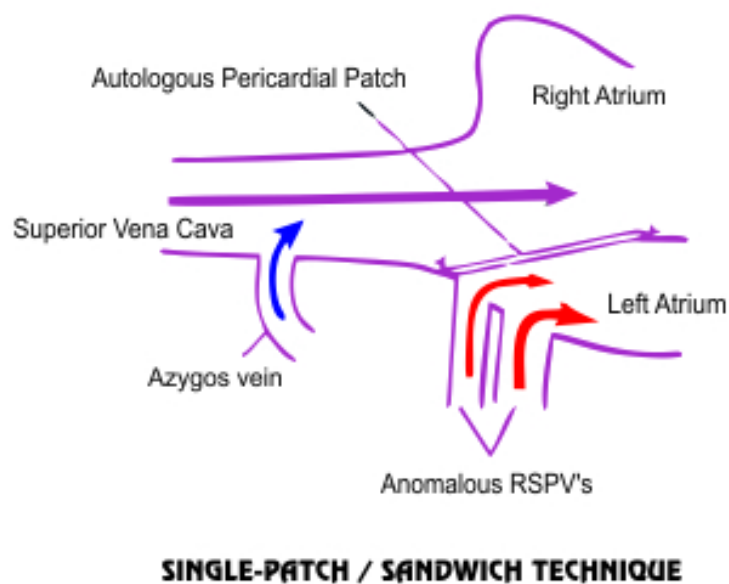
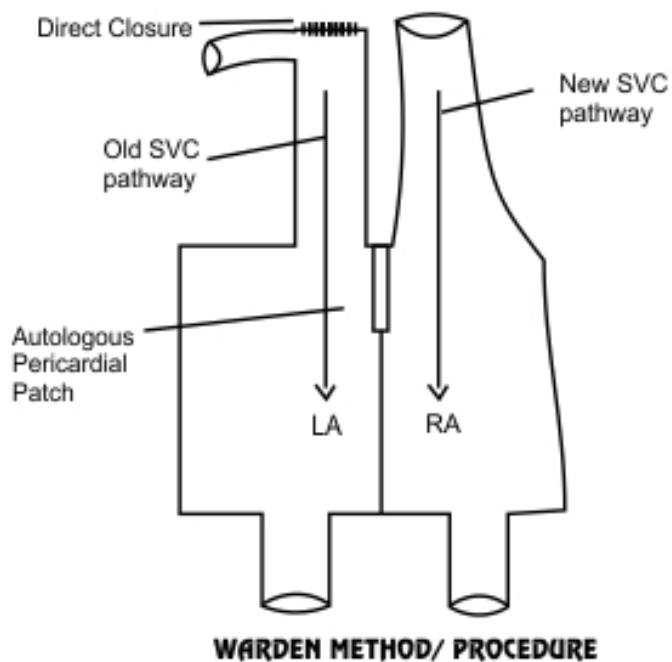


Figure 11 : SINGLE - PATCH/ Figure 12 : TWO - PATCH TECHNIQUE
SANDWICH TECHNIQUE



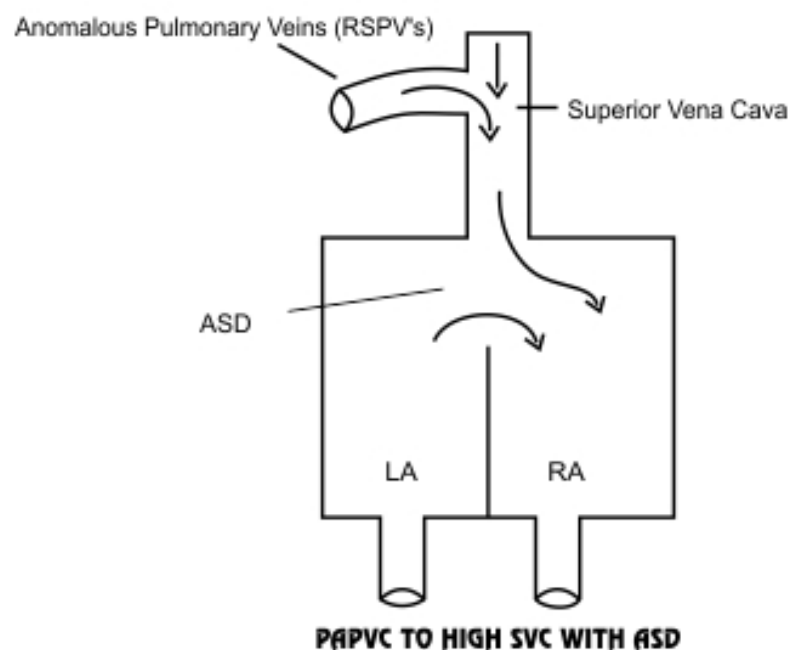


Figure 13 : PAPVC TO HIGH SVC WITH ASD Figure 14 : WARDEN PROCEDURE

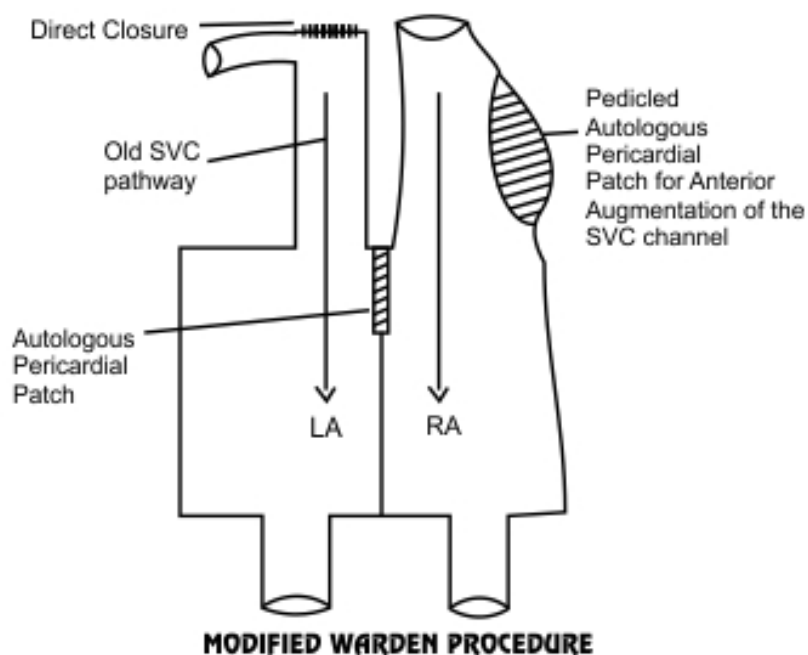
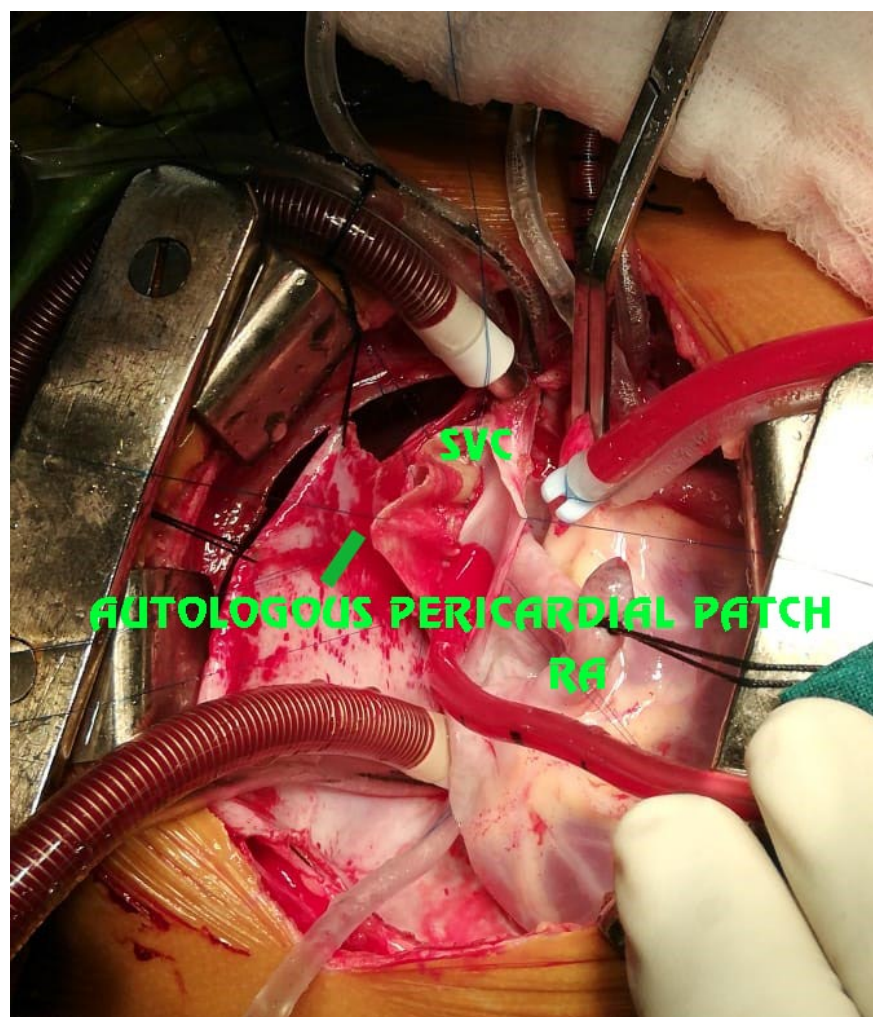


Figure 15 : MODIFIED WARDEN PROCEDURE

N.B. : RA- Right Atrium, LA- Left Atrium, SVC – Superior Vena Cava, RSPV – Right Superior Pulmonary Vein, ASD – Atrial Septal Defect

(Image Credits, Figure 11 – 15 : Dr.Vishal V. Bhende)



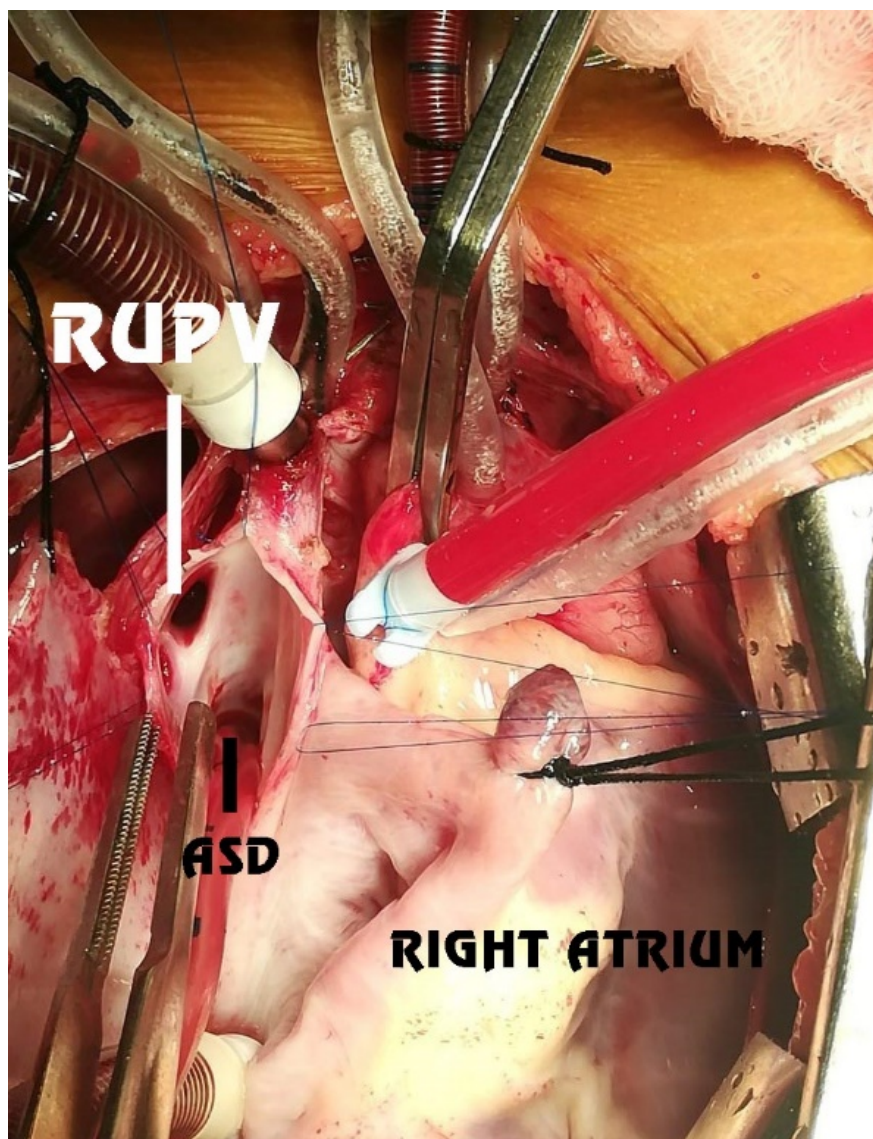
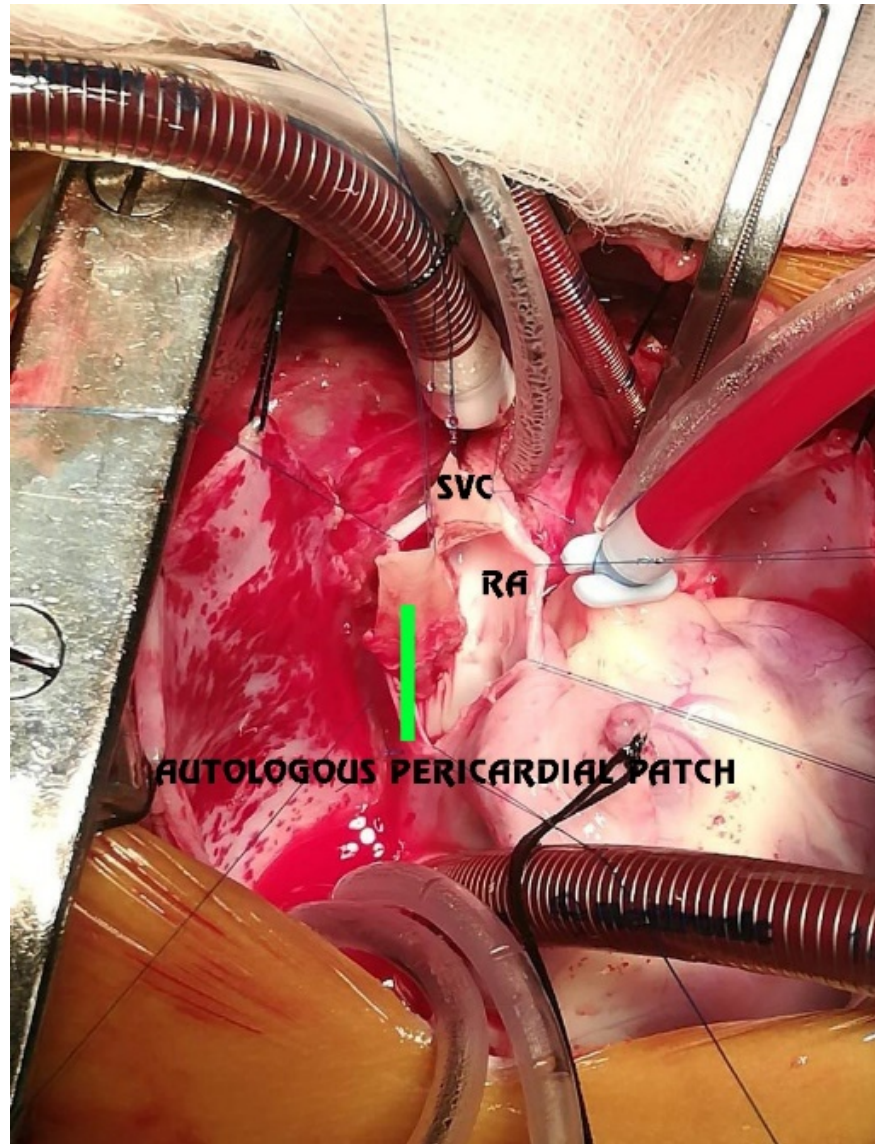


Figure 16 : P 1 SHOWING SV-ASD Figure 17 : SINGLE-PATCH FOR
DEFECT P 1 PATIENT



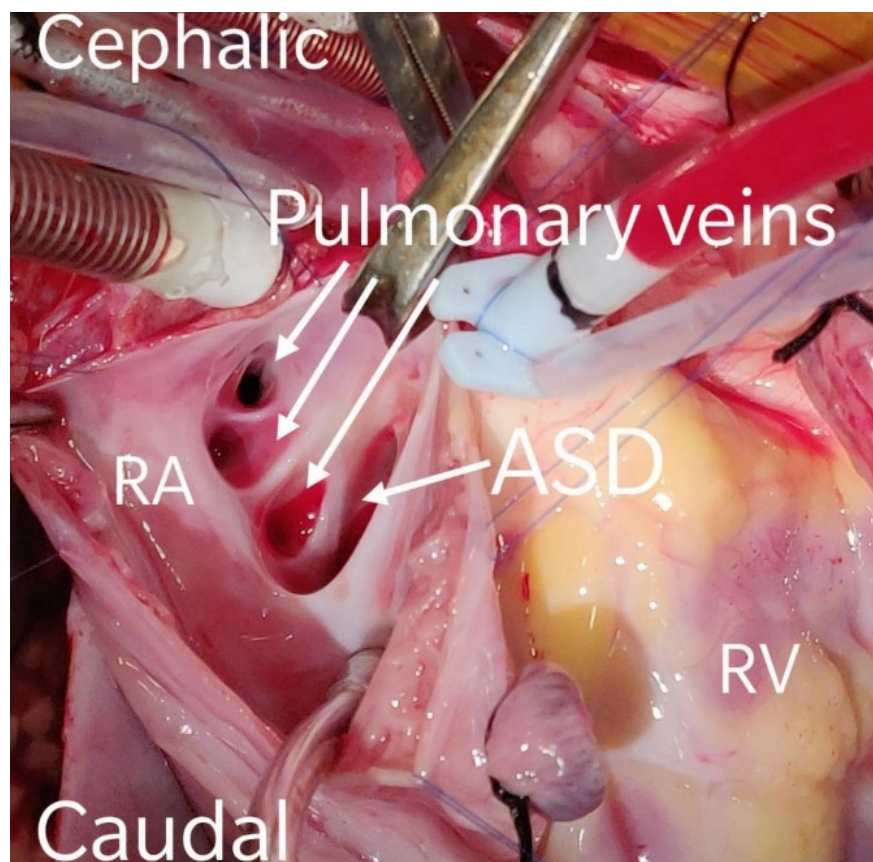


Figure 18 : SINGLE PATCH FOR Figure 19 : SV-ASD DEFECT
P 2 PATIENT SEEN IN P 7 PATIENT

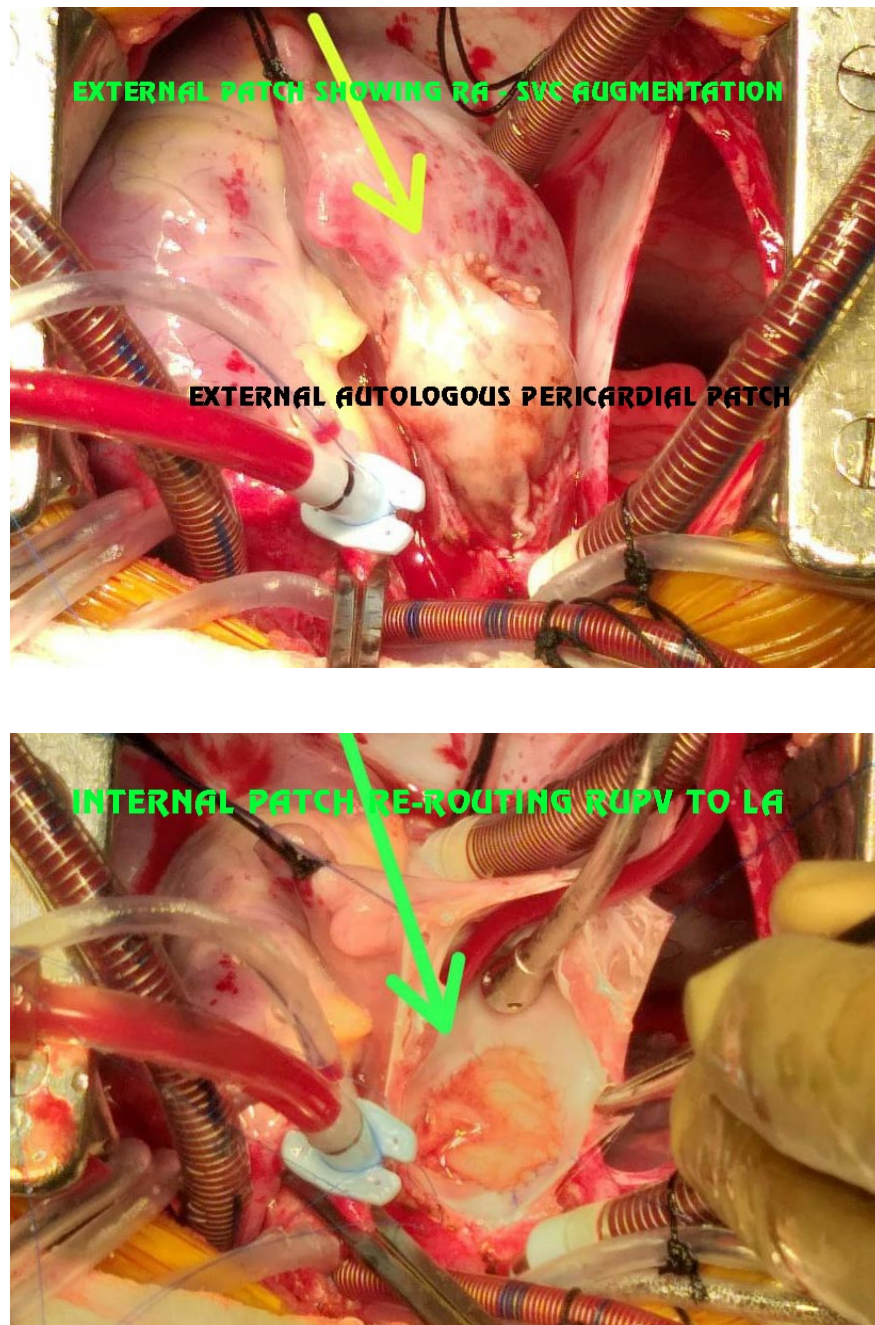


Figure 20 : TWO-PATCH TECHNIQUE Figure 21 : TWO-PATCH
(INTERNAL PATCH) FOR P 9 (EXTERNAL PATCH) TECHNIQUE
PATIENT FOR P 9 PATIENT

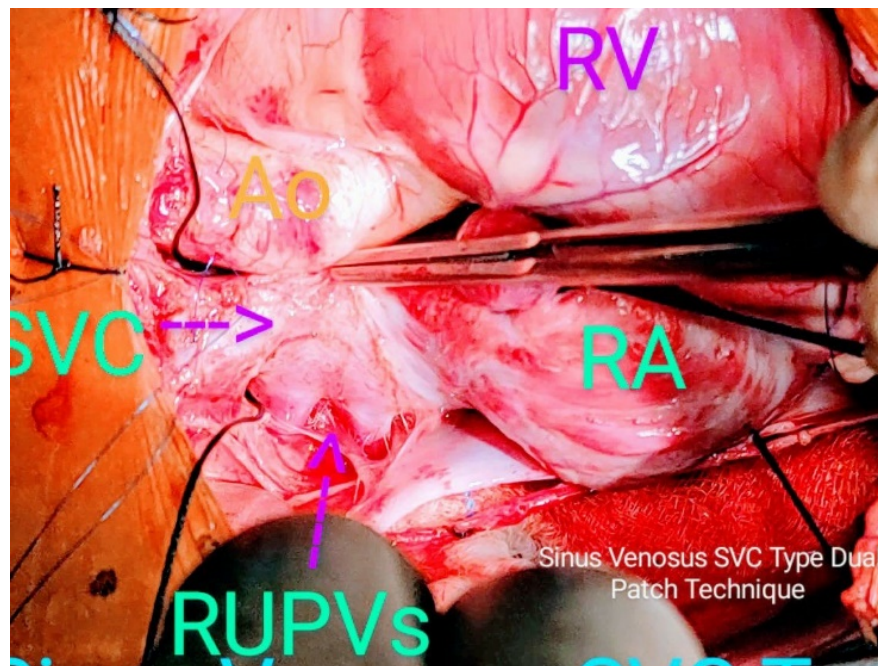


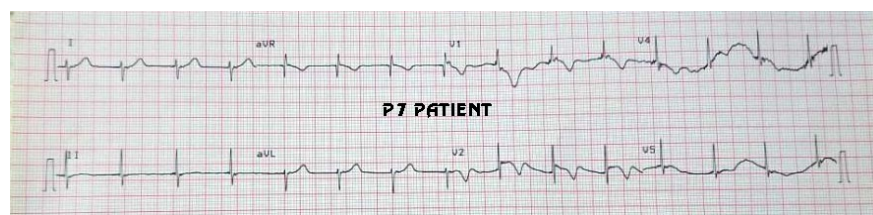
Figure 22 : SV-ASD DEFECT WITH RUPVs FOR P 6 PATIENT

(Image Credits, Figure 16 – 22 : Dr.Vishal V. Bhende)

ECG findings

Patients' electrocardiographic patterns were interpreted as normal sinus rhythm, low atrial rhythm, or junctional rhythm by two reviewers who were unaware of the patients' type of surgical repair. Criteria for interpretation as low atrial rhythm included a change in the P-wave axis or a significantly shortened PR interval.

Sinus node dysfunction was defined as persistent sinus bradycardia (<50 bpm); ectopic atrial rhythm, junctional/nodal rhythm, or a wandering atrial pacemaker (<60 bpm); or pauses of more than 3 seconds. It was also diagnosed on the basis of electrophysiological evidence of sinus node dysfunction. New sinus node dysfunction was defined as sinus node dysfunction that appeared postoperatively (present at hospital dismissal or at a late follow-up) in cases in which sinus rhythm had been present preoperatively.



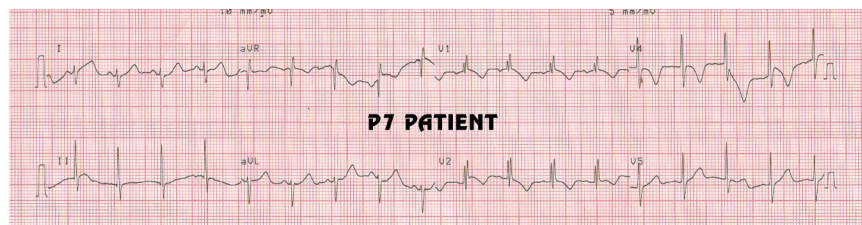


Figure 23 : ECG STRIP OF P 7 PATIENT FROM JUNCTIONAL RHYTHM (*ABOVE*) TO NORMAL SINUS RHYTHM (*BELOW*)

Statistical analysis

To perform data analysis, we used statistical software: namely, STATA, version 14.2 (StataCorp. 2015. Stata Statistical Software: Release 14. College Station, TX, USA: StataCorp. LP).

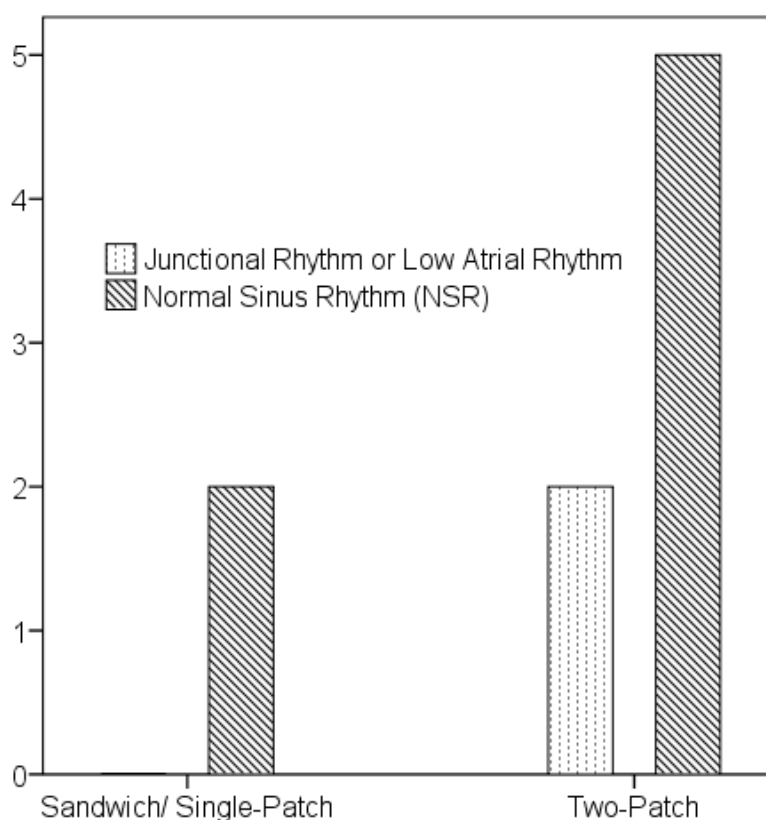


Figure 24 : COMPARISON OF POST- OPERATIVE TO LATE ELECTROCARDIOGRAMS DEMONSTRATING A CHANGE FROM NORMAL SINUS RHYTHM (BLACK BARS) TO A LOW ATRIAL RHYTHM OR JUNCTIONAL RHYTHM (WHITE BARS = SINUS NODE DYSFUNCTION)

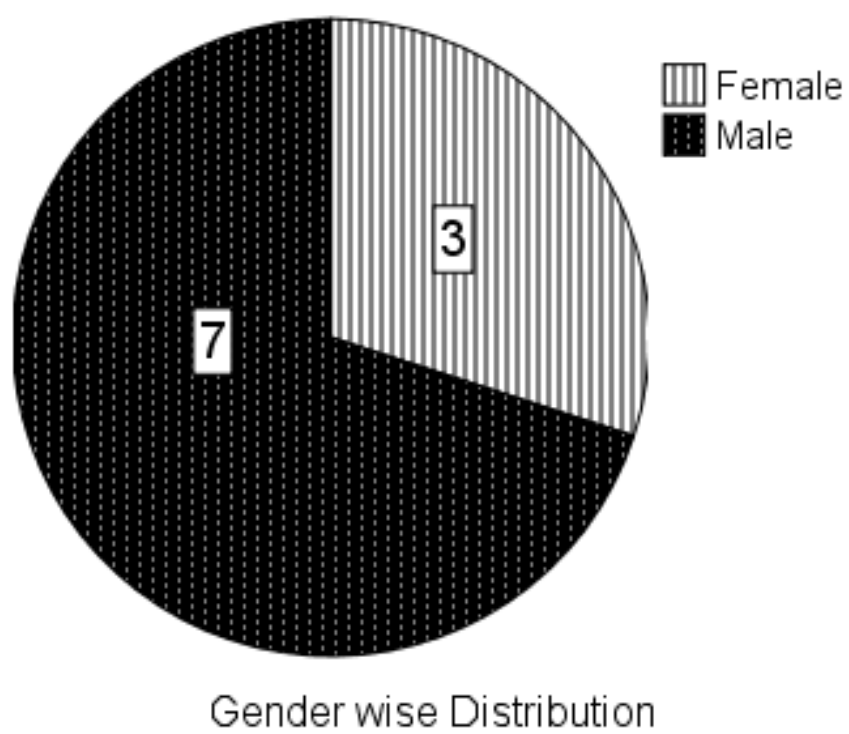


Figure 25 : GENDER WISE DISTRIBUTION

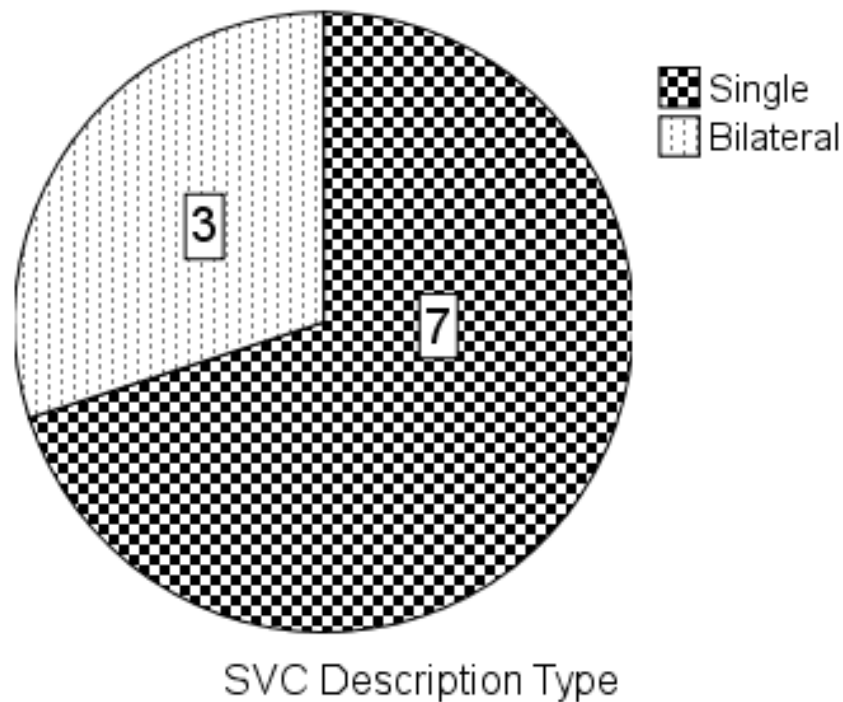


Figure 26 : SVC DESCRIPTION TYPE

Results

No early or late deaths occurred in this series; no patients required reoperation, and none had residual ASDs. Of the 9 patients with PAPVC involving the RA-SVC junction or RA, none exhibited late stenosis of either the SVC or pulmonary veins on follow-up echocardiography, and none required the Warden procedure. Two patients, P4 and P7, exhibited junctional rhythm on early ECG (Figure 23) and underwent two-patch repair. This junctional rhythm reverted to normal sinus rhythm on late ECG in the hospital. The remaining 8 patients exhibited normal sinus rhythm on early ECG. The association between technique (single- versus two-patch) and rhythm was not significant ($p > 0.999$; Figure 24). The gender distribution of patients and type of superior vena cava are illustrated in Figures 25 and 26.)

Discussion

The repair of SVASD with PAPVC involving the SVC has been a surgical challenge since the earliest reports of this anomaly [5,6]. Numerous surgical modifications have been made to repair the defect and redirect pulmonary venous return. Although the early problems of persistent PAPVC and residual ASD have largely been eliminated, problems with SVC stenosis, pulmonary vein stenosis, and sinus node dysfunction remain, as reported in many surgical series. In our study, PAPVC involving the SVC at a low level, the RA, or both was treated by septal transposition [7] or by redirection of the anomalous pulmonary venous flow to the left atrium through the ASD through the use of a patch applied from within the RA [8]. We did not encounter cases in which PAPVC involved the SVC at a high level (1 cm or more above the cavoatrial junction) with or without an associated ASD.

In a literature review, we found that use of the two-patch technique was associated with a very low incidence of stenosis of the SVC or pulmonary veins. According to the literature, the incidence of sinus node dysfunction after two-patch repair is significant; this technique entails an incision that crosses the SVC-RA junction, on

the anterior surface or laterally, which puts the sinus node at risk for damage. DeLeon and associates [8], in a review of 40 patients who underwent repair between 1979 and 1991, found that repair with an RA appendage flap that included a continuous incision through the anterior RA-SVC junction was associated with a higher incidence of sinus node dysfunction than was repair involving either no incision of the SVC or an end-to-side appendage to an SVC anastomosis without any incision near the SVC-RA junction.

Stewart and coworkers [7] studied 15 patients in whom SVASD and PAPVC involving the SVC were repaired with a single-patch technique, which included an incision from the atrial appendage superiorly along the SVC to the level of the PAPVC, thus directly across the sinus node. They noted that 6 (40%) of these patients had early sinus node dysfunction but, of interest, all these postoperative rhythm problems resolved before hospital discharge. In one of our patients (P9), early sinus node dysfunction returned to normal sinus rhythm.

All 7 patients who underwent two-patch repair continue to be monitored at our cardiac center. Two patients exhibited junctional rhythm on ECG early in the postoperative period, but this later reverted to normal sinus rhythm. The remaining 5 patients exhibited normal sinus rhythm on early ECG.

Because patients who underwent two-patch repair continued to exhibit normal sinus rhythm on late ECG with no turbulence in the SVC-RA junction pathway and with no arrhythmias, we advocate two-patch repair over single-patch repair.

According to our review of the literature, the Warden procedure involves no incisions near the sinus node or the sinus nodal artery, and no sinus node dysfunction has occurred after this procedure. Gustafson et al. and Warden et al. have reported on their growing series of patients; the initial patient underwent surgery in 1967 [9,10]. As of the most recent report, they had performed the Warden procedure in 40 patients, of whom only 1 (2.5%) exhibited continuing sinus node dysfunction [10]. Two other patients exhibited early sinus node dysfunction, but normal sinus rhythm was achieved by 5 days and 6 months after surgery.

Shahriari and colleagues [11] reported the results of SVASD repair in 54 patients, of whom 27 underwent single-patch repair, 12 underwent two-patch repair, and 13 underwent the Warden procedure. The rate of arrhythmias in the entire series was very low; 100% of the patients who underwent the Warden procedure remained in normal sinus rhythm. Similarly, Gaynor and colleagues [12] reported on a series of 11 patients who underwent the Warden procedure between 1987 and 1995, none of whom exhibited sinus node dysfunction. DiBardino and associates [13] reported a single case of transient sinus bradycardia among 16 patients who underwent the Warden procedure between 1995 and 2004 [14]. In summary, the literature indicates that the Warden procedure essentially eliminates the possibility of sinus node injury and thus sinus node dysfunction.

In the 2 patients who underwent single-patch repair, turbulence was noted in the SVC-RA junction pathway: Patient P1 exhibited a peak pressure of 4 mm Hg (mean, 2 mm Hg), and P2 exhibited a peak pressure of 18 mm Hg (mean, 18 mm Hg). No rhythm abnormalities occurred after single-patch repair [15,16].

In our series, patient P10 had left-sided isolated PAPVC with ASD and pulmonary stenosis. In this patient, we rerouted the PAPVC by creating an anastomosis between the left atrial appendage and the vertical vein with flush ligation of the vertical vein and the innominate vein, leaving the hemiazygos vein in the systemic pathway. We used a glutaraldehyde-treated pericardial patch to close the ASD and performed pulmonary valvotomy.

Patient P4 underwent preoperative evaluation with dynamic cardiac CT because intracranial arteriovenous malformations were suspected of causing dilatation of the SVC.

In the combined series reported by Shariari et al., Gaynor et al., and DiBardino et al., no patients had SVC stenosis, and only 2 had pulmonary vein stenosis. Of interest is that in both patients, who were treated at different hospitals, pulmonary vein stenosis appeared to result from untreated shrinkage of an autologous pericardial patch. The authors recommended using a polytetrafluoroethylene intra-atrial baffle. In our series, we used pericardium patches without any evidence of pulmonary vein stenosis caused by patch shrinkage.

Limitations

A limitation of this study was its retrospective design. Because the natural history of SVASD is not assessable, and because no historical control group is available for comparison, the natural history of unoperated SVASD is unknown; however, it is probably similar to that of large ASDs.

The presence of atrial arrhythmias decreases the ability to detect sinus node dysfunction; thus the frequency of sinus node dysfunction detection may have been underestimated.

Conclusions

The decision to surgically repair SVASD should be individualized. However, such intervention is rarely necessary or advisable in an infant younger than 1 year or in very elderly patients. Our findings confirm that the two-patch technique remains the procedure of choice for patients with a SVASD and PAPVC involving the RA or the SVC-RA junction. In cases of bilateral SVC without innominate vein connection, single-patch repair can be attempted without causing much turbulence in the SVC-RA junction, in comparison with cases of single SVC.

The Warden procedure should be an option in pediatric cases of SVASD with PAPVC involving high levels of the SVC because it provides unobstructed drainage of the SVC and pulmonary veins and virtually eliminates the problem of sinus node dysfunction that is common with the two-patch repair.

Despite the complexity of the lesion, repair of SVASD with associated APVC is associated with low rates of morbidity and mortality, even in patients older than 40 years. Survival rates are similar to those of a matched population, and although repair is suggested as early as possible, it should be considered whenever repair may affect survival or symptoms .

ACKNOWLEDGEMENTS –

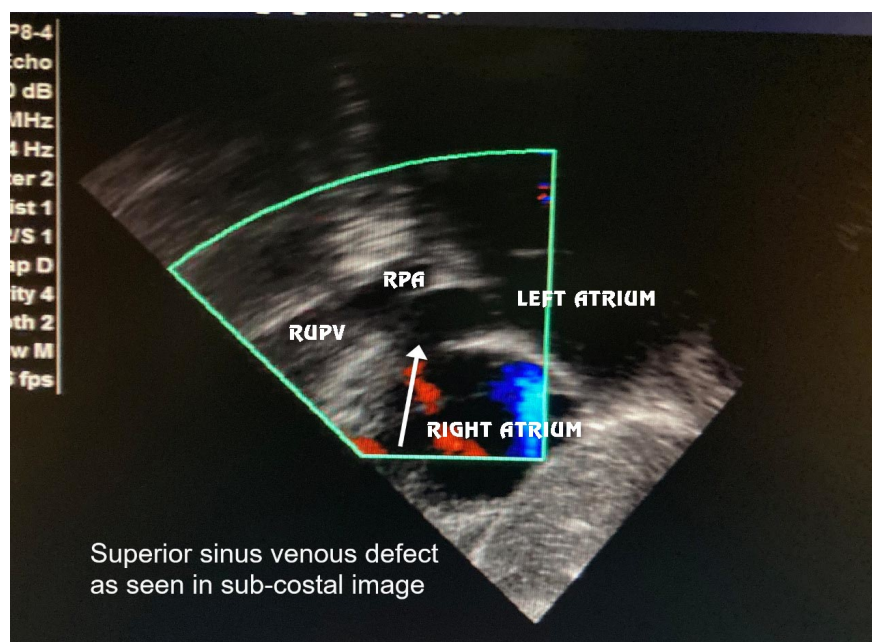
We are thankful to –

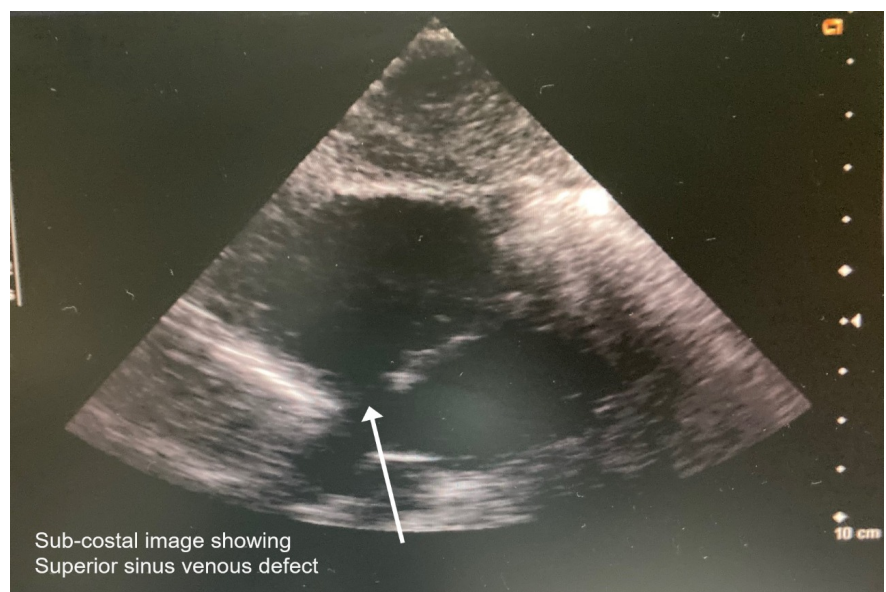
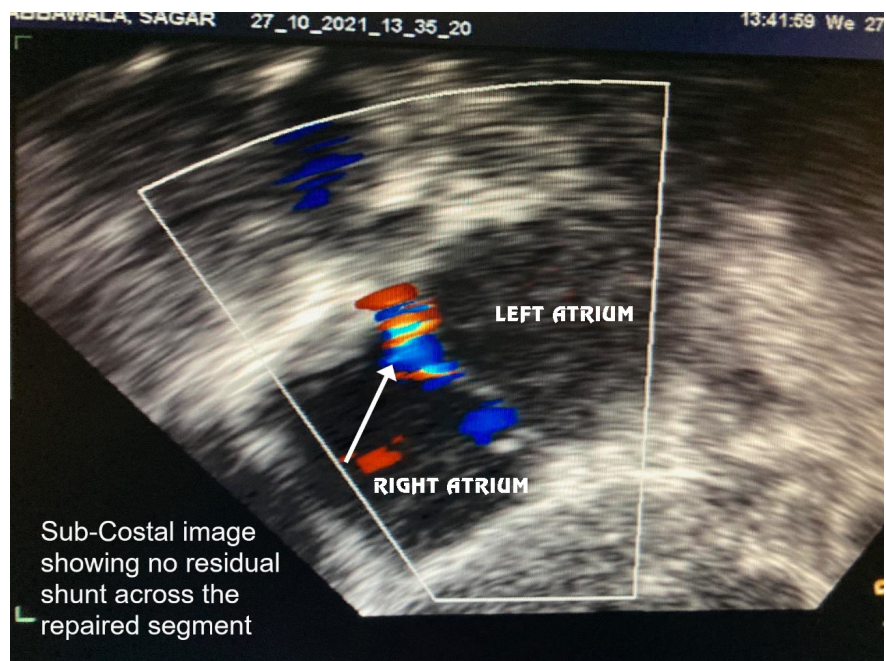
1. Mrs. Mamta Roshan Patel, Bio- Statistician, Central Research services, Bhaikaka University, Karamsad.*Email : mamtarp@charutarhealth.org*
2. Mr. Naresh Jayantibhai Fumakiya, Echo-Cardiographer, Bhanubhai and Madhuben Patel Cardiac Centre, Shree Krishna Hospital, Karamsad.
3. Mr. Khushal N. Vankar, Office Assistant, Department of Diagnostic Services, Shree Krishna Hospital, Bhaikaka University, Karamsad.*Email : khushalnv@charutarhealth.org*

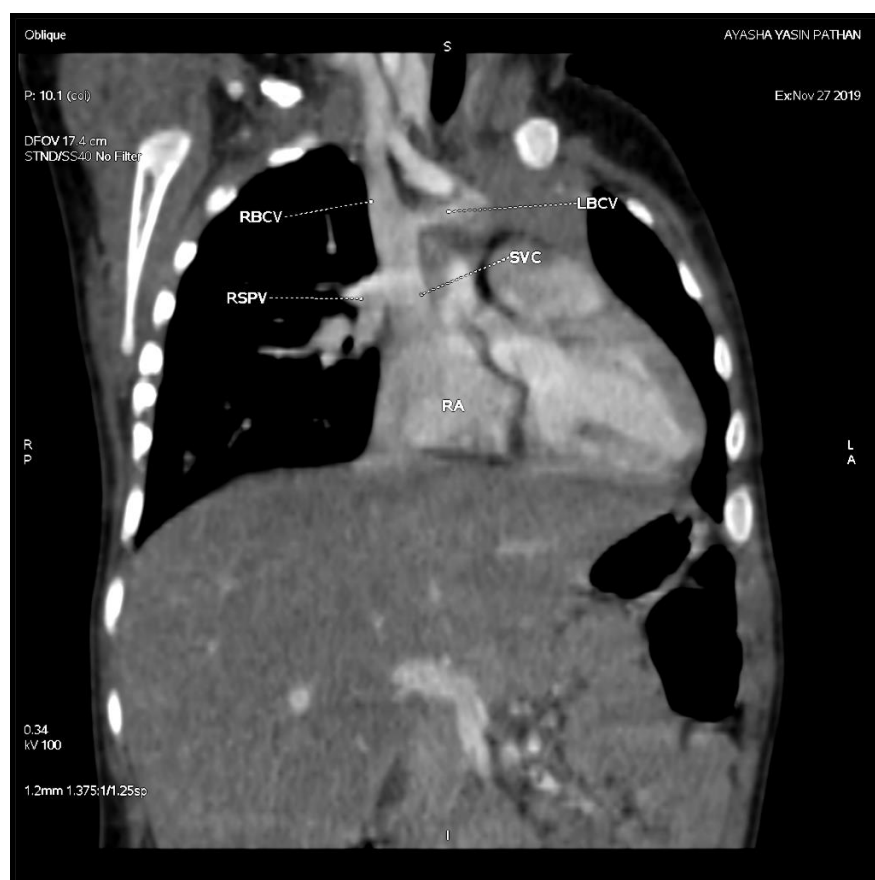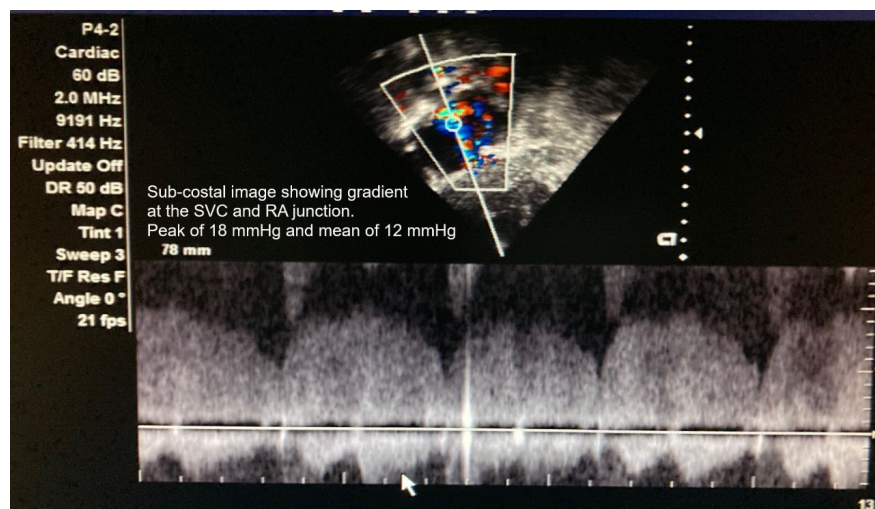
References

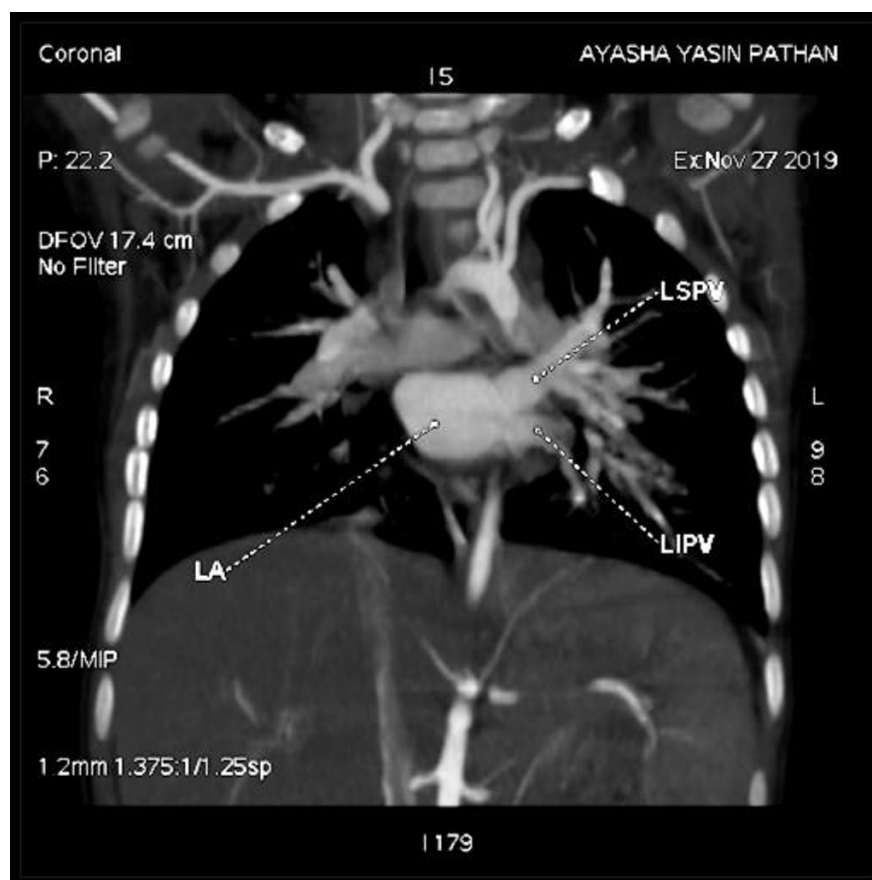
1. Peacock TB: Malformations of the heart. In: Peacock TB, ed. On Malformations, &c., of the Human Heart: With Original Cases. London, UK: John Churchill. 1858:11-102. 10.1017/S1047951100010349
2. Oliver JM, Gallego P, Gonzalez A, Dominguez FJ, Aroca A, Mesa JM: Sinus venosus syndrome: atrial septal defect or anomalous venous connection? A multiplane transoesophageal approach. *Heart*. 2002, 88:634-638. 10.1136/heart.88.6.634
3. Van Praagh S, Carrera ME, Sanders SP, Mayer JE, Van Praagh R: Sinus venosus defects: unroofing of the right pulmonary veins: anatomic and echocardiographic findings and surgical treatment. *Am Heart J*. 1994, 128:365-379. 10.1016/0002-8703(94)90491-X
4. Kirklin JW, Barratt-Boyes BG, eds: *Cardiac Surgery: Morphology, Diagnostic Criteria, Natural History, Techniques, Results, and Indications*New York. NY: Churchill Livingstone; 1993. 1:609-644.
5. Schuster SR, Gross RE, Colodny AH: Surgical management of anomalous right pulmonary venous drainage to the superior vena cava, associated with superior marginal defect of the atrial septum. *Surgery*. 1962, 51:805-8. 10.5555/uri:pii:0039606062903252
6. Kyger ER III, Frazier H, Cooley DA, et al.: Sinus venosus atrial septal defect: early and late results following closure in 109 patients. *Ann Thorac Surg*. 1978, 25:44-50. 10.1016/S0003-4975(10)63485-6

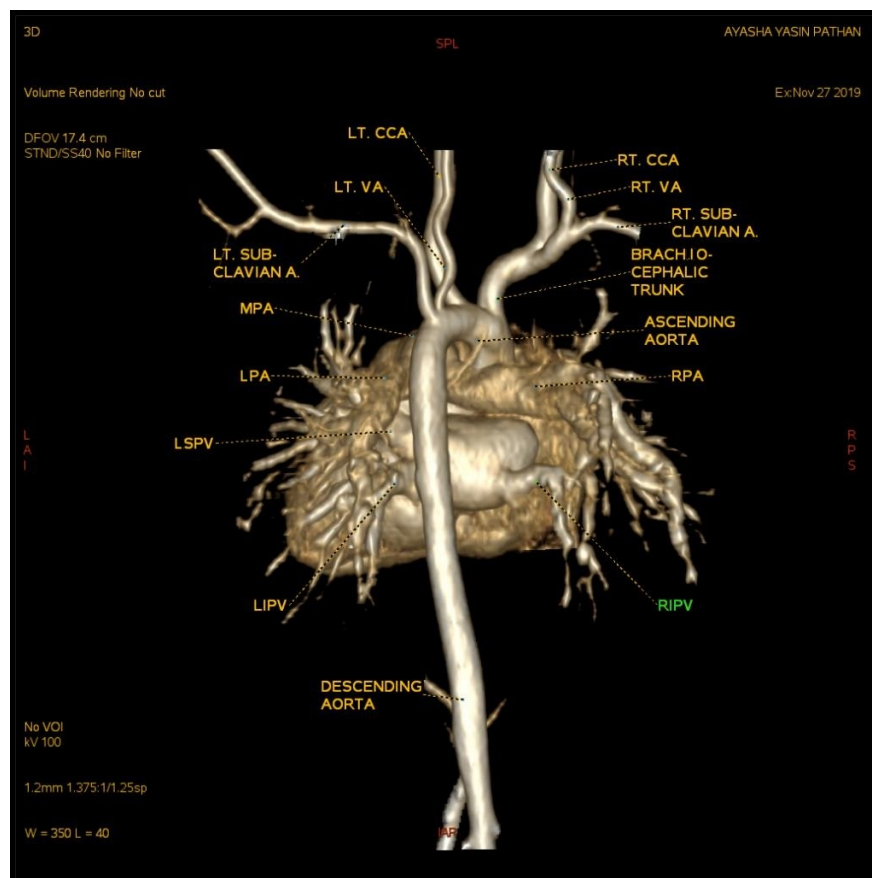
7. Stewart S, Alexson C, Manning J: Early and late results of repair of partial anomalous pulmonary venous connection to the superior vena cava with a pericardial baffle. *Ann Thorac Surg.* 1986, 41:498-501. 10.1016/S0003-4975(10)63026-3
8. DeLeon SY, Freeman JE, Ilbawi MN, et al.: Surgical techniques in partial anomalous pulmonary veins to the superior vena cava. *Ann Thorac Surg.* 1993, 55:1222-6. 10.1016/0003-4975(93)90038-J
9. Gustafson RA, Warden HE, Murray GF, Hill RC, Rozar GE: Partial anomalous pulmonary venous connection to the right side of the heart. *J Thorac Cardiovasc Surg.* 1989, 98:861-8. 10.1016/S0022-5223(19)34264-3
10. Gustafson RA, Warden HE, Murray GF: Partial anomalous pulmonary venous connection to the superior vena cava. *Ann Thorac Surg.* 1995, 60:5614-7. 10.1016/j.ejcts.2011.05.043
11. Shahriari A, Rodefeld MD, Turrentine MW, Brown JW: Caval division technique for sinus venosus atrial septal defect with partial anomalous pulmonary venous connection. *Ann Thorac Surg.* 2006, 81:224-30. 10.1016/j.athoracsur.2005.07.015
12. Gaynor JW, Burch M, Dollery C, Sullivan ID, Deanfield JE, Elliott MJ: Repair of anomalous pulmonary venous connection to the superior vena cava. *Ann Thorac Surg.* 1995, 59:1471-5. 10.1016/0003-4975(95)00150-J
13. DiBardino DJ, McKenzie ED, Heinle JS, Su JT, Fraser CD Jr: The Warden procedure for partially anomalous pulmonary venous connection to the superior caval vein. *Cardiol Young.* 2004, 14:64-7. 10.1017/S1047951104001118
14. Warden HE, Gustafson RA, Tarnay TJ, Neal WA: An alternative method for repair of partial anomalous pulmonary venous connection to the superior vena cava. *Ann Thorac Surg.* 1984, 38:601-5. 10.1016/S0003-4975(10)62317-X
15. Jost CH, Connolly HM, Danielson GK, et al.: Sinus venosus atrial septal defect. long-term post-operative outcome for 115 patients. *Circulation.* 2005, 112:1953-1958. 10.1161/CIRCULATION-AHA.104.493775
16. Stewart RD, Bailliard F, Kelle AM, Backer CL, Young L, Mavroudis C: Evolving Surgical Strategy for Sinus Venosus Atrial Septal Defect: Effect on Sinus Node Function and Late Venous Obstruction. *Ann Thorac Surg.* 2007, 84:1651-5. 10.1016/j.athoracsur.2007.04.130

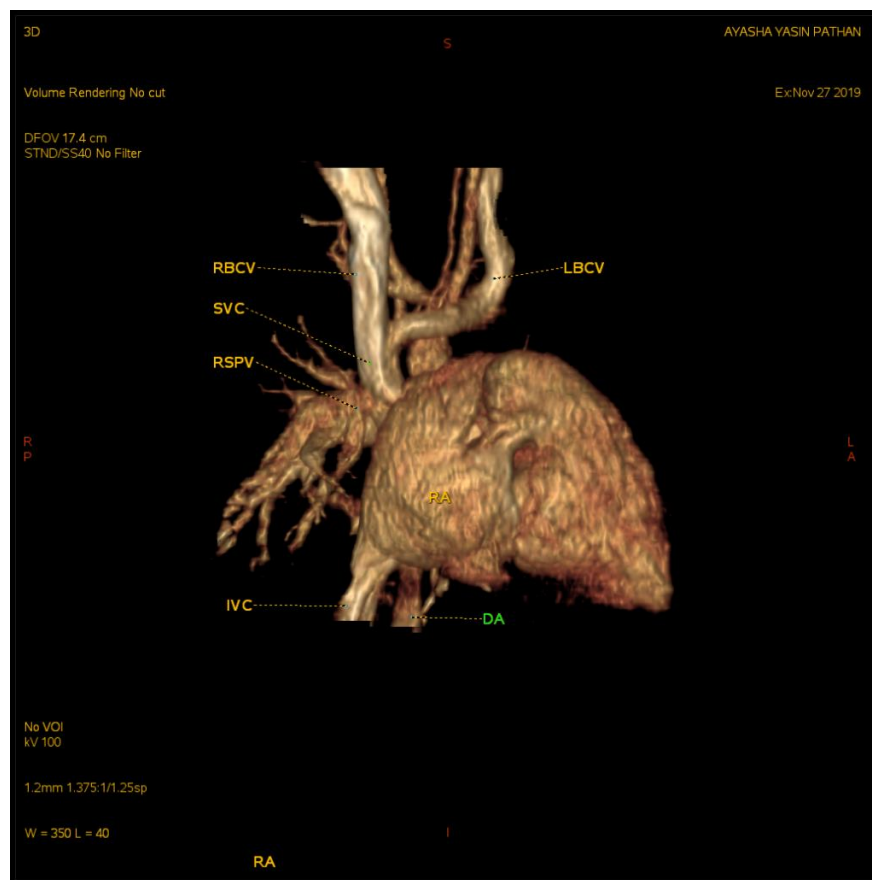


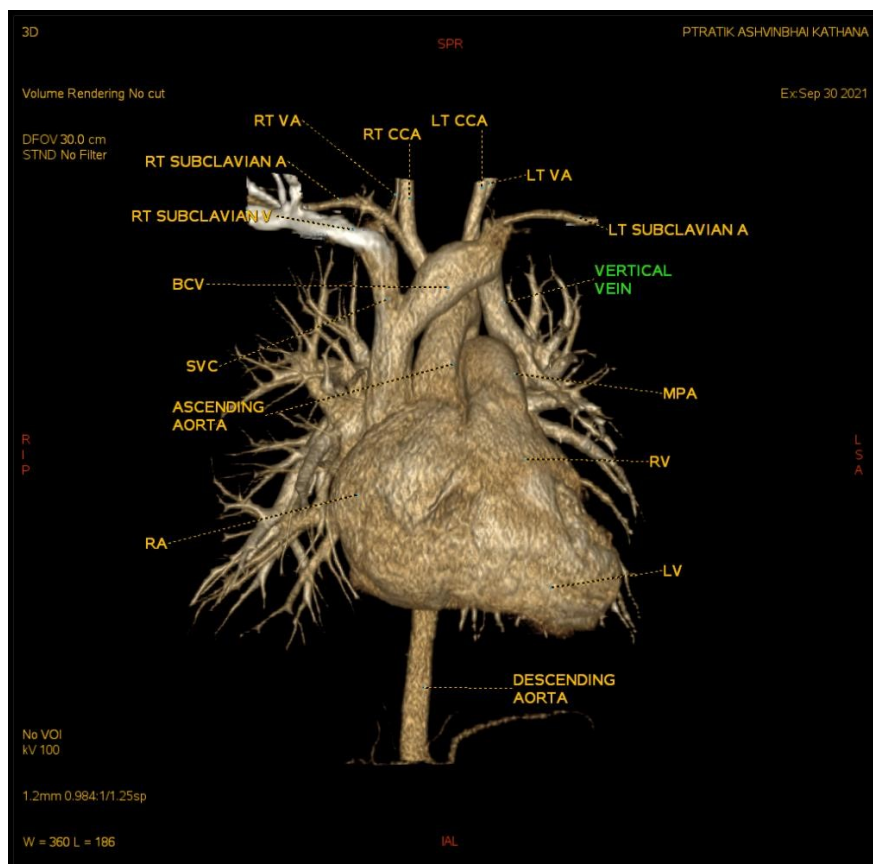


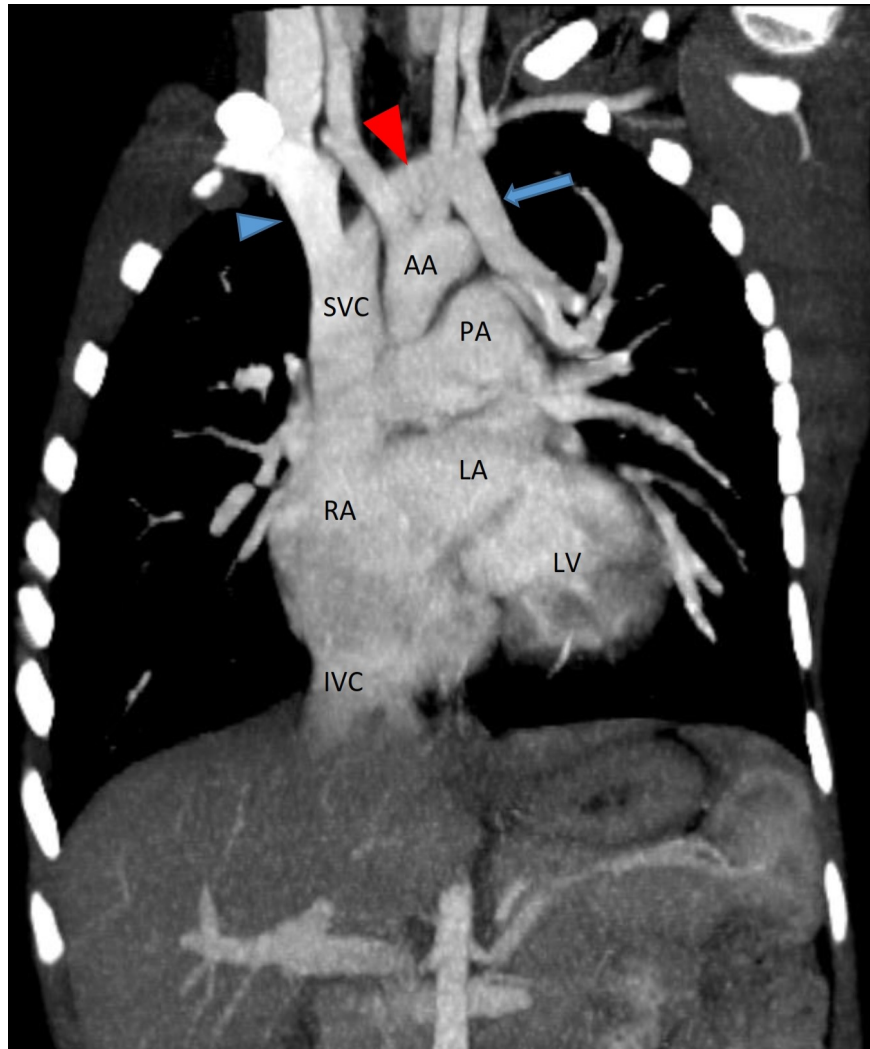


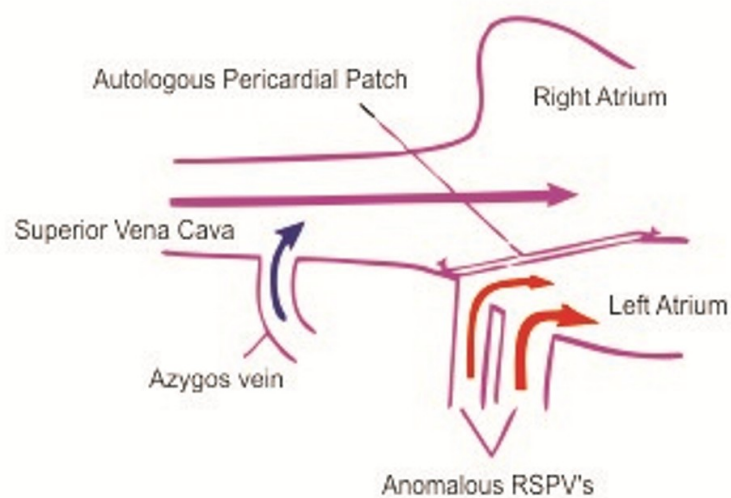




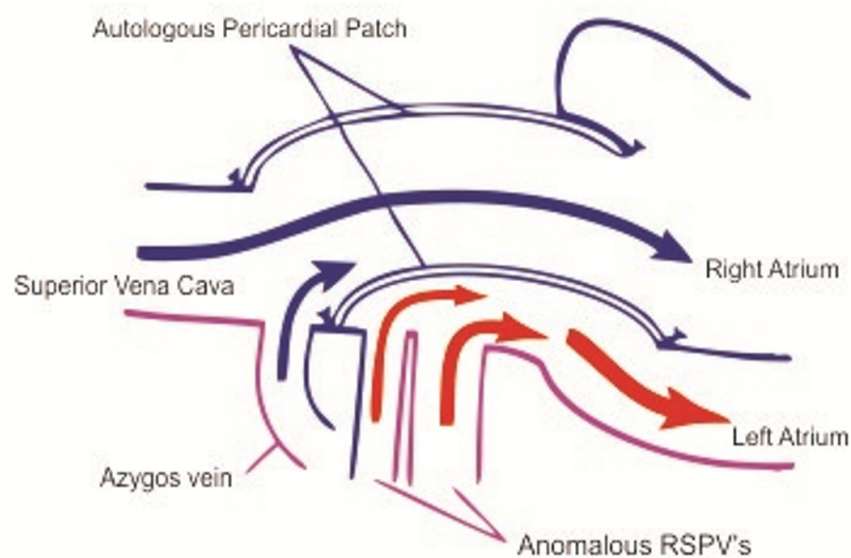




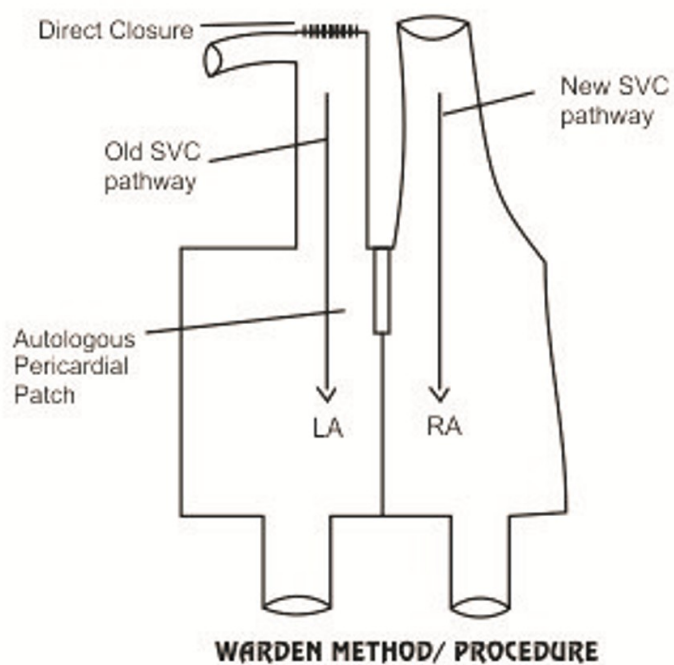
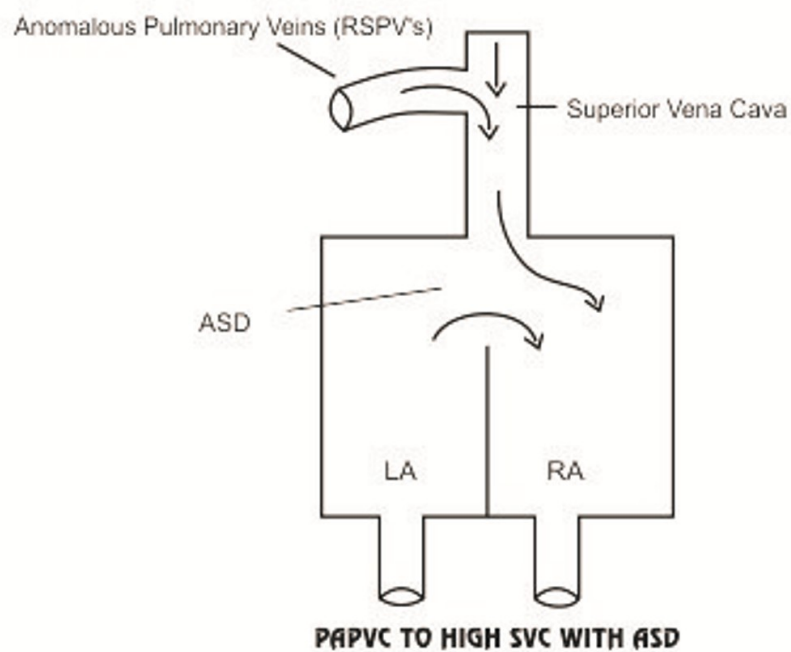


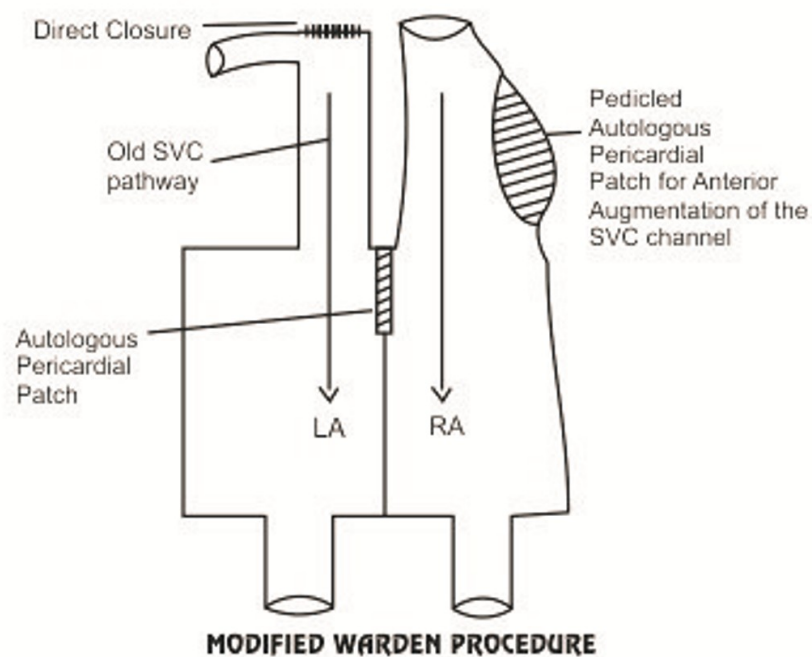


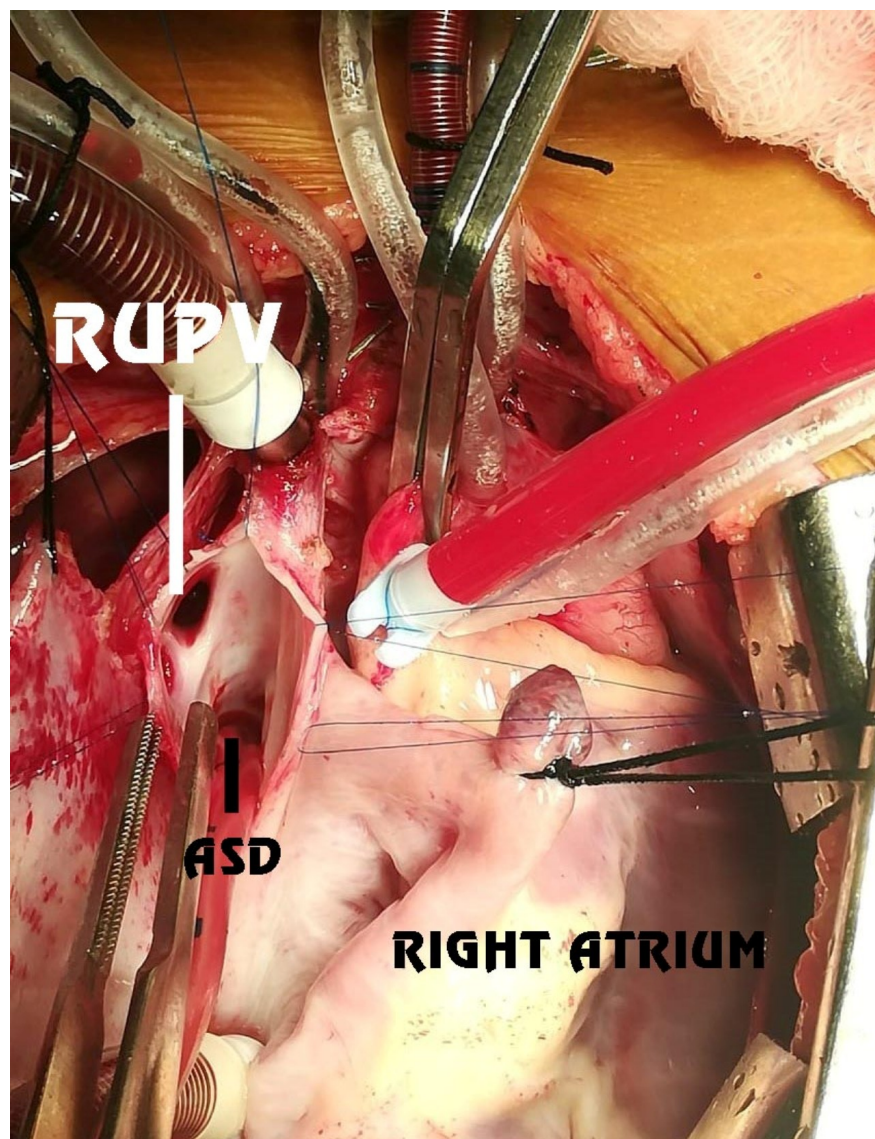
SINGLE-PATCH / SANDWICH TECHNIQUE

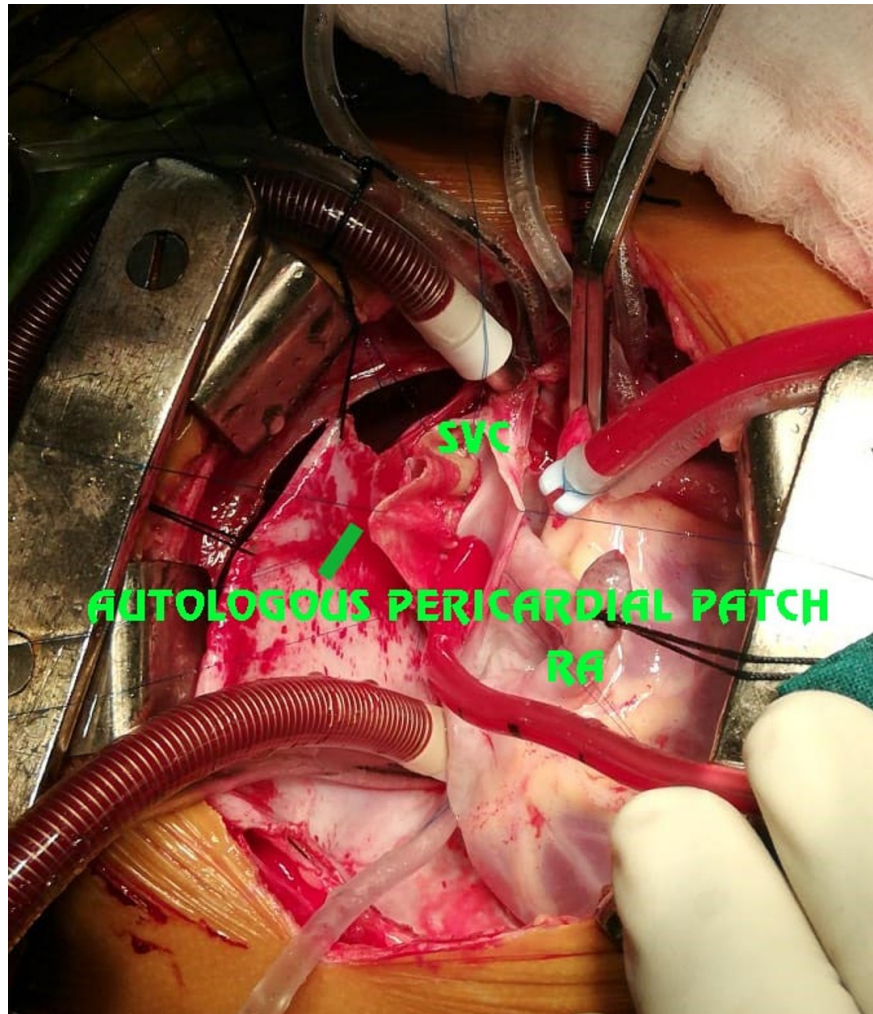


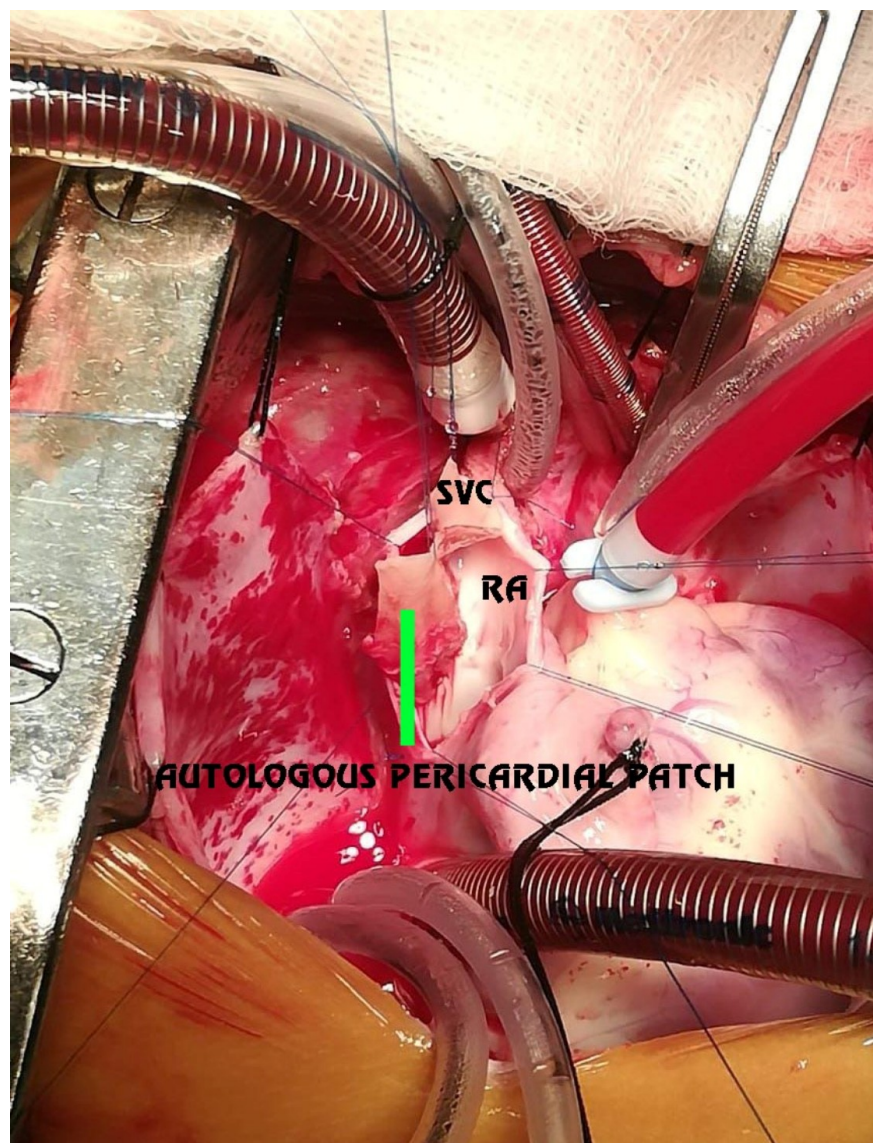
TWO-PATCH TECHNIQUE

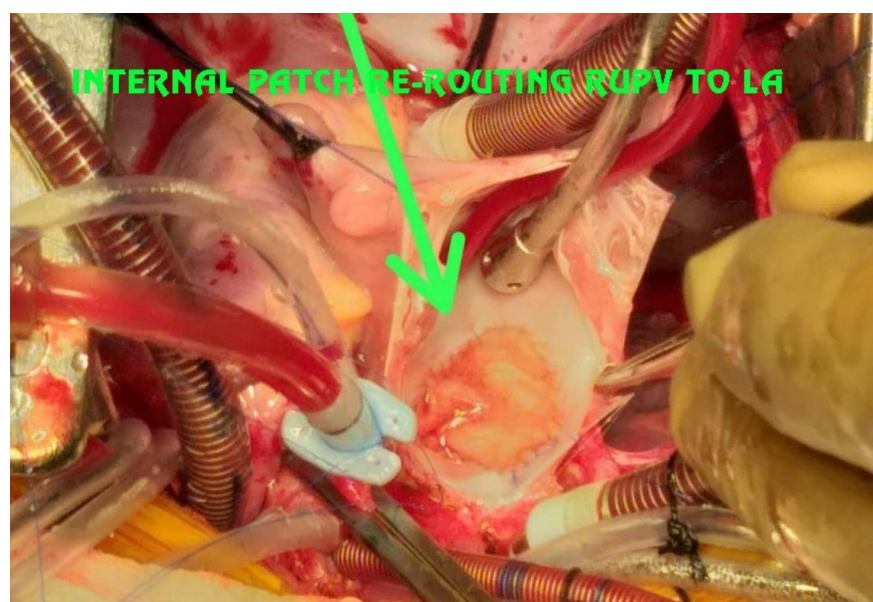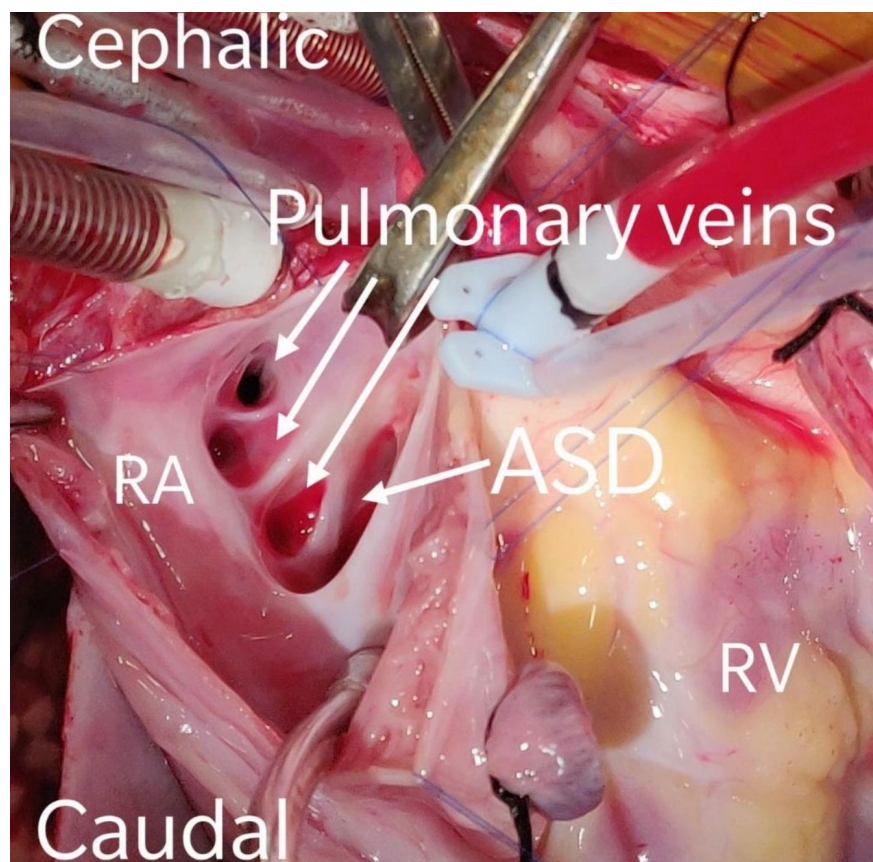


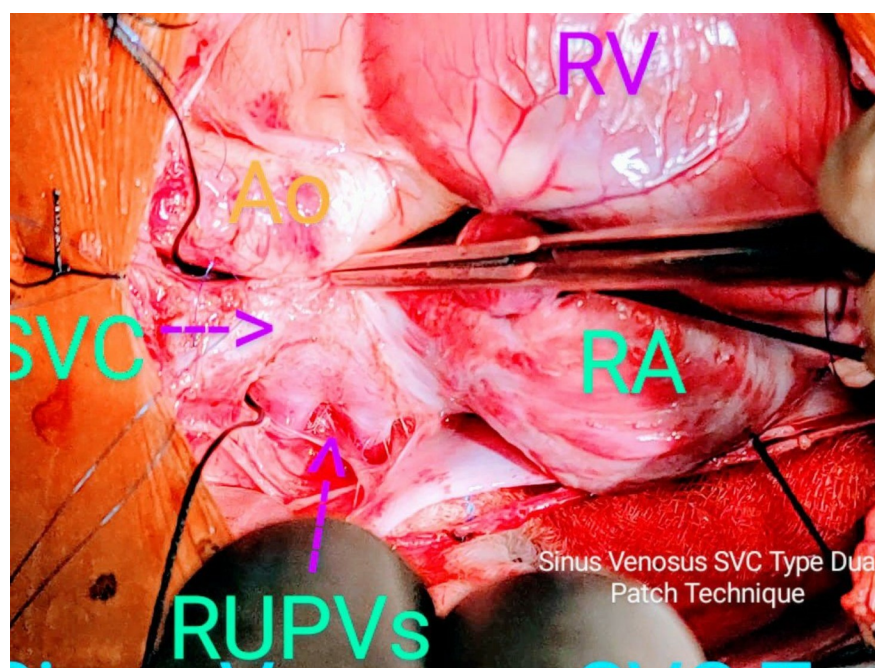
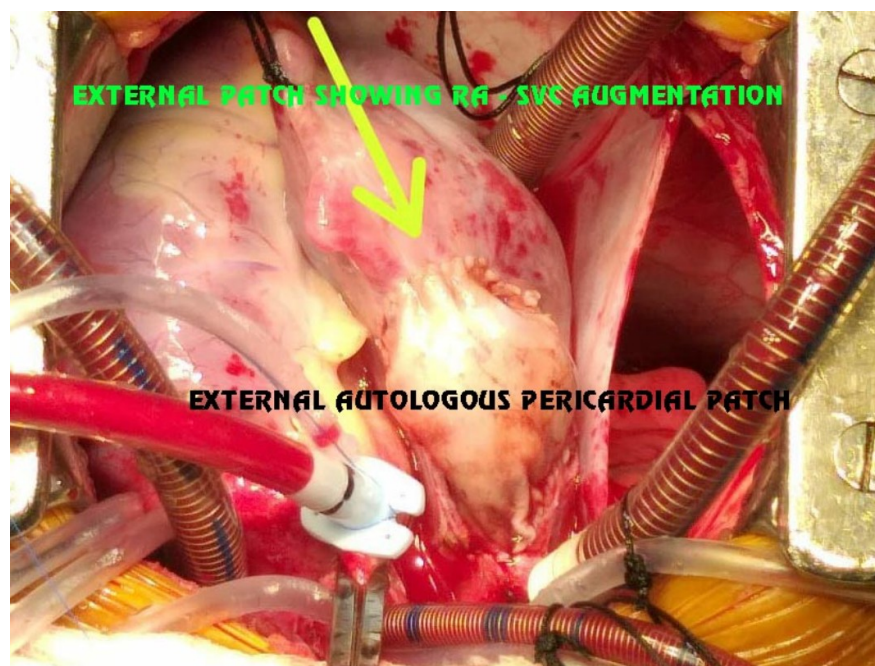


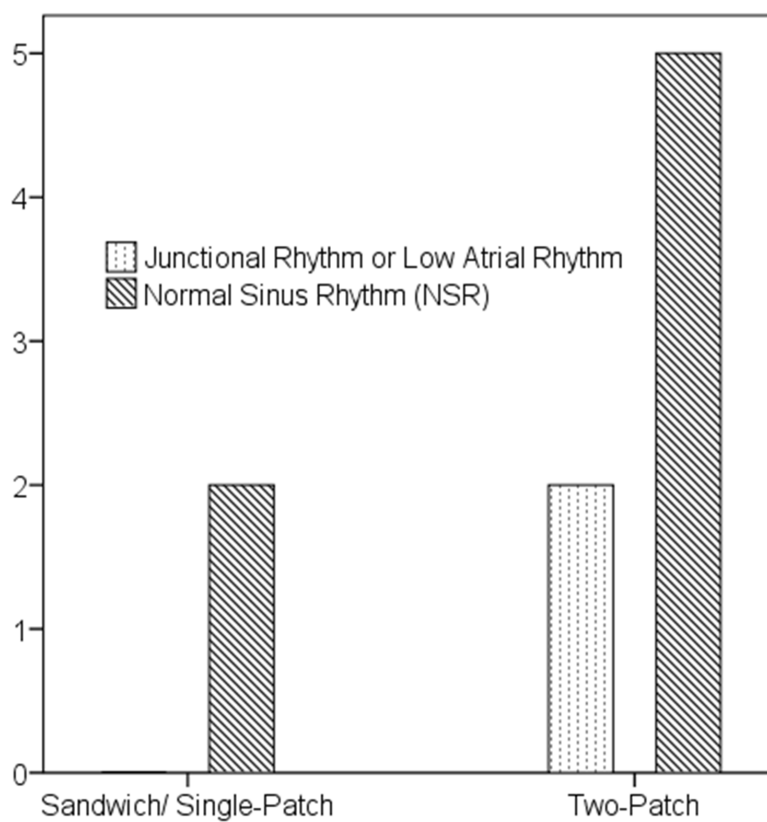


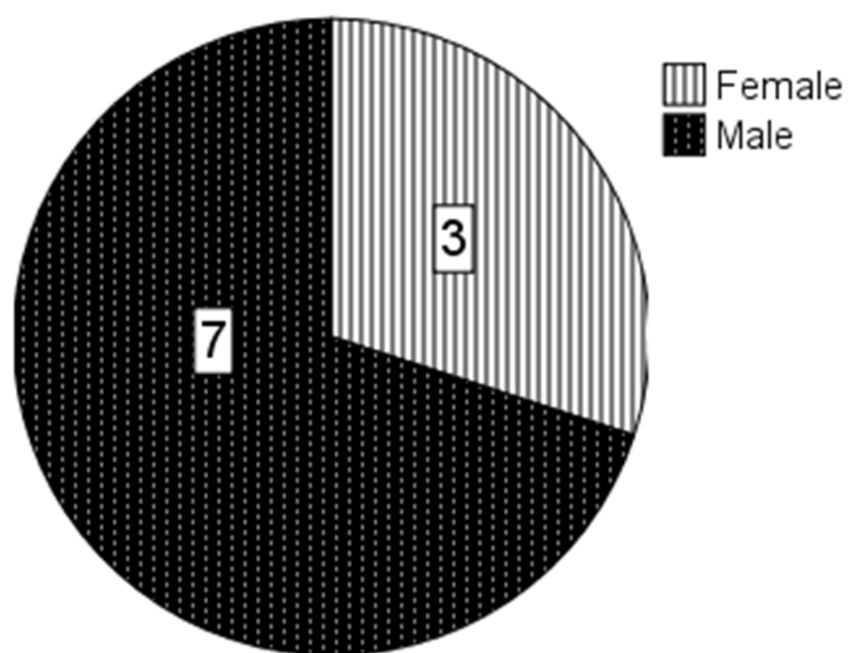




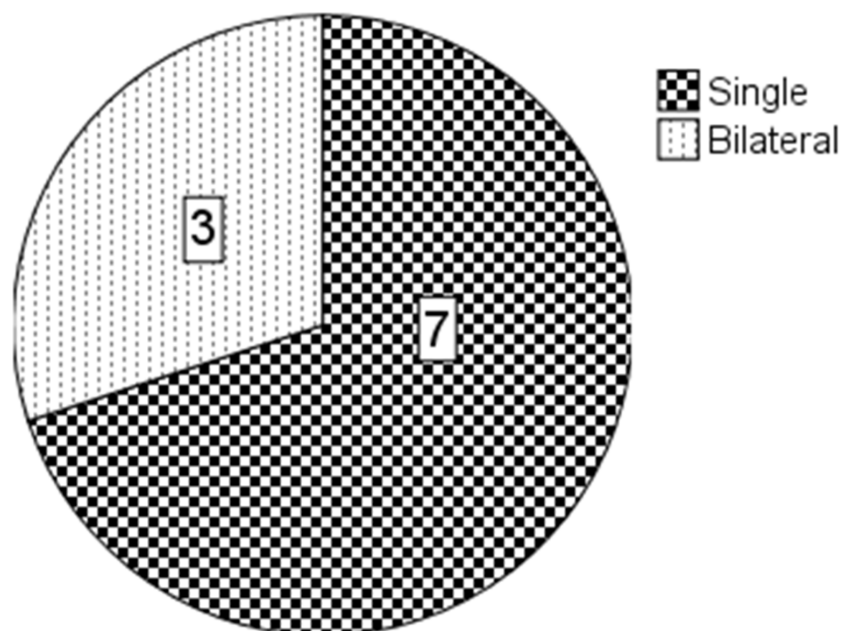




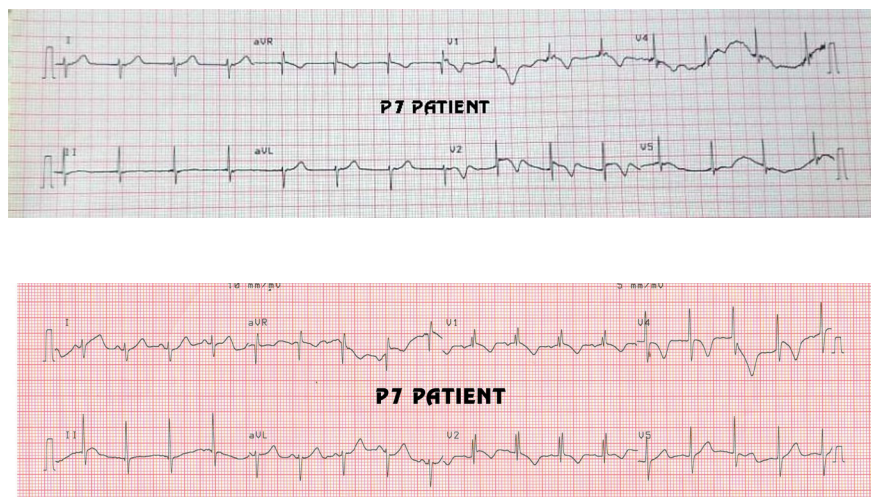




Gender wise Distribution



SVC Description Type



Hosted file

TABLE.docx available at <https://authorea.com/users/454413/articles/552035-mid-term-post-operative-outcome-of-sinus-venosus-atrial-septal-defect-with-anomalous-pulmonary-venous-connection-with-different-surgical-strategies-and-their-effect-on-sinus-node-function-and-late-venous-obstruction>