

Bronchopleural fistula causing persistent pneumothorax in COVID-19 pneumonia patient with no risk factors.

Mhd Baraa Habib¹, Ibrahim Mohammad Obeidat¹, Khaled Ali¹, Mohamed Abdelrazek¹, and Mouhand Mohamed¹

¹Hamad Medical Corporation

June 25, 2021

Abstract

Although pneumothorax is a well-known complication of COVID-19 pneumonia especially in patients requiring mechanical ventilation, bronchopleural fistula causing persistent pneumothorax in sole COVID-19 pneumonia is extremely rare. In this case, we illustrate that bronchopleural fistula can be found in COVID-19 pneumonia, even with no risk factors nor mechanical ventilation administration.

Bronchopleural fistula causing persistent pneumothorax in COVID-19 pneumonia patient with no risk factors

Mhd Baraa Habib¹, Ibrahim Mohammad Obeidat¹, Khaled Ali², Mohamed Abdelrazek³, Mouhand F H Mohamed¹

¹Department of Internal Medicine, Hamad Medical Corporation, Doha, Qatar.

²Community Medicine Department, Hamad Medical Corporation, Doha, Qatar.

³Radiology Department, Hamad Medical Corporation, Doha, Qatar.

Correspondence: Dr. Khaled Ali, MD, Hamad Medical Corporation, Doha, Qatar. Email: kali15@hamad.qa ORCID: 0000-0002-8073-4375

Funding:

This research did not receive any specific grant from funding agencies in the public, commercial, or not-for-profit sectors.

Authorship contribution:

The first author (MBH): Conceptualization, Writing - original draft; IO, KA participated in literature review and editing the manuscript; MA prepared the graphs; MM: revision and editing.

Declaration of Competing Interest:

The authors report no conflict of interest.

Consent:

Due to the COVID-19 situation and its impact on direct patient contact, only verbal consent was obtained to publish this case.

Acknowledgment:

The authors would like to thank the patient for allowing us to share his details with the medical community. Additionally, we acknowledge the Qatar National Library for funding the open access fees of this publication.

Abstract Although pneumothorax is a well-known complication of COVID-19 pneumonia especially in patients requiring mechanical ventilation, bronchopleural fistula causing persistent pneumothorax in sole COVID-19 pneumonia is extremely rare. In this case, we illustrate that bronchopleural fistula can be found in COVID-19 pneumonia, even with no risk factors nor mechanical ventilation administration.

Keywords:

COVID-19, Unusual complication, Persistent pneumothorax, Tension pneumothorax, Bronchopleural fistula.

Abbreviations COVID-19: Coronavirus disease 2019; BPF: Bronchopleural fistula; SARS-COV-2: severe acute respiratory syndrome coronavirus 2; Bronchopleural fistula: BPF; CPAP: continuous positive airway pressure therapy; CT: Computed tomography.

Key Clinical Message

Bronchopleural fistula should be considered in sole COVID-19 pneumonia patients suffering from persistent pneumothorax, even in those who have never been placed on mechanical ventilation.

Introduction:

Pneumothorax reflects the presence of air in the pleural cavity [1]. Tension pneumothorax is a serious condition in which the trapped air causes shifting of the mediastinum as a result of the high pressure in the pleural space [1]. It is seen in approximately 1 to 2 percent of pneumothorax cases with a higher rate in patients with trauma and patients receiving mechanical ventilation [2]. Although chest x-ray is usually the initial investigation for pneumothorax, chest computed tomography scan (CT) is the best modality, especially in complicated cases, in which it can determine the presence, size, and location of intrapleural gas [3].

Bronchopleural fistula (BPF) is a sinus tract between a bronchus and the pleural cavity [4]. It usually presents as a complication of pneumonectomy or surgery on the lung; however, many other causes have been described including pneumonia with necrosis, chest radiation, invasive malignancy, and tuberculosis [4]. Treatment for BPF can be medical, bronchoscopic, or surgical depending on the clinical condition and the underlying cause [4]. BPF can cause significant morbidity and mortality mainly due to aspiration pneumonia or tension pneumothorax [4].

Case report:

A 40-year-old non-smoker, previously healthy gentleman, presented with worsening shortness of breath and sore throat for a few days. A chest x-ray showed bilateral airspace patchy opacities suggestive of pneumonia (figure 1-A). Polymerase Chain Reaction (PCR) from a nasopharyngeal swab was positive for SARS-CoV-2. On admission, the patient was afebrile, but tachypneic and required continuous positive airway pressure therapy (CPAP) alternating with 50 liters of high flow nasal canula of oxygen to maintain his oxygen saturation around 92%. The patient was admitted into the intensive care unit as a case of severe COVID-19 pneumonia. He was treated according to the local COVID-19 protocol including methylprednisolone, remdesivir, azithromycin, tocilizumab and intravenous immunoglobulin. The patient did not require intubation nor central line insertion during hospitalization.

Three weeks after admission, the patient was suffering from rapid worsening of shortness of breath, using accessory respiratory muscles, and required higher levels of oxygen. Chest X-ray showed right-sided tension pneumothorax with collapsed right lung and pushed heart and mediastinum to the left side (figure 1-B). A chest tube was urgently inserted with a remarkable improvement of breathlessness and oxygen saturation (figure 1-C). Chest CT scan showed bilateral diffuse ground-glass opacities, moderate right-sided pneumothorax, minimal right-sided pleural effusion, and right chest tube seen in-situ (figure 1-D). However, it did not show any underlying emphysema or bullae. Over the next few days, the chest tube was kept in place

to give time for healing. However, it was continuously bubbling for the next three weeks. Gathering the above findings, the picture suggested that a bronchopleural fistula is the reason behind the persistent air leak. Given the unstable lungs' condition, the patient was not fit for a surgical intervention at that point. Therefore, the decision was to keep the chest tube as long as possible or to discharge him with Hemlich valve waiting for spontaneous recovery or possible surgical intervention once he is medically fit.

The chest tube was incidentally removed on day 42 post-insertion, then the pneumothorax reaccumulated while the patient clinically remained stable (figure 2-A). A right intercostal pigtail catheter was inserted in the 2nd intercostal space into the mid-clavicular line. On day 52 post chest tube insertion (10 days later), the chest tube had showed no more bubbling for 2 days, So the pigtail catheter was removed. The patient was discharged after 3 days of observation (figure 2-B). The patient had a follow-up phone call after one week which demonstrated no active complaints.

Discussion

Recent studies on COVID-19 patients showed a pneumothorax prevalence of 1–2% [2][5]. However, bronchopleural fistula is extremely rare in previously fit patients with no complicated hospital course such as mechanical ventilation requirement or superinfection. Although there are a few reported cases of tension pneumothorax among COVID-19 pneumonia patients, bronchopleural fistula in relation to COVID-19 pneumonia has been reported only in very few ones [6][7]. Also, these reported cases were of patients with accompanied issues such as necrotic fungal co-infection [8] and long-term mechanical ventilation [7][9].

We think that patients with no comorbidities nor complicated hospital course might be overlooked for as such a rare complication as bronchopleural fistula. Our patient was middle aged, had no comorbidities, non-smoker, required only continuous positive airway pressure therapy (CPAP) for a short duration, and his CT chest showed signs of pneumonitis with no evidence of lung necrosis. These findings subsequently suggest that the bronchopleural fistula is solely due to COVID-19 pneumonia. So, BPF should be kept in mind in cases of sudden persistent deterioration of COVID-19 pneumonia patients, even with absence of apparent risk factors, and even in patients who have not been placed on mechanical ventilation.

Additionally, our patient was successfully treated conservatively with prolonged chest tube drainage (53 days), which indicates that surgical or more invasive treatment is not always required. On the other hand, the related cases in the literature were treated invasively with, for instance, salvage lobectomy [6], and Endobronchial valves [10].

Conclusion

Sole COVID-19 pneumonia can cause bronchopleural fistula, which leads to persistent pneumothorax. Keep this possibility in mind even in patients who are not on mechanical ventilation. Also, less-invasive management with a long-term chest tube can be considered as an effective intervention especially for patients who are not candidate for surgery.

References:

- [1] Jalota R, Pneumothorax SET. StatPearls Publishing; 2021. n.d.
- [2] Noppen M, de Keukeleire T. Pneumothorax. *Respiration* 2008;76:121–7. n.d.
- [3] Jalli R, Sefidbakht S, SH. J. Value of ultrasound in diagnosis of pneumothorax: A prospective study. *Emerg Radiol* 2013;20:131–4.
- [4] Kiyota Y, Topulos GP, fistula HPMB. *Essential Clinical Anesthesia Review: Keywords. Quest. Answers Boards*, ; p, 2015, p. 518–9.
- [5] Salehi S, Abedi A, Balakrishnan S, Gholamrezanezhad A. Coronavirus disease 2019 (COVID-19): A systematic review of imaging findings in 919 patients. *Am J Roentgenol* 2020;215:87–93.

- [6] Peeters K, Mesotten D, Willaert X, Deraedt K, Nauwelaers S, Lauwers G. Salvage Lobectomy to Treat Necrotizing SARS-CoV-2 Pneumonia Complicated by a Bronchopleural Fistula. *Ann Thorac Surg* 2021;111:241–3.
- [7] Pathak V, Waite J, Chalise S. Use of endobronchial valve to treat COVID-19 adult respiratory distress syndrome-related alveolopleural fistula. *Lung India* 2021;38:69.
- [8] Placik DA, Taylor WL, NM. W. Bronchopleural fistula development in the setting of novel therapies for acute respiratory distress syndrome in SARS-CoV-2 pneumonia. *Radiol Case Reports* 2020;15:2378–81.
- [9] Aesif SW, Bribresco AC, Yadav R, Nugent SL, Zubkus D, Tan CD, et al. Pulmonary Pathology of COVID-19 Following 8 Weeks to 4 Months of Severe Disease: A Report of Three Cases, Including One With Bilateral Lung Transplantation. *Am J Clin Pathol* 2021;155:506–14. <https://doi.org/10.1093/ajcp/aqaa264>.
- [10] Talon A, Arif MZ, Mohamed H, Khokar A, AI. S. Bronchopleural Fistula as a Complication in a COVID-19 Patient Managed With Endobronchial Valves. *J Investig Med High Impact Case Reports* 2021;9:096211013216.

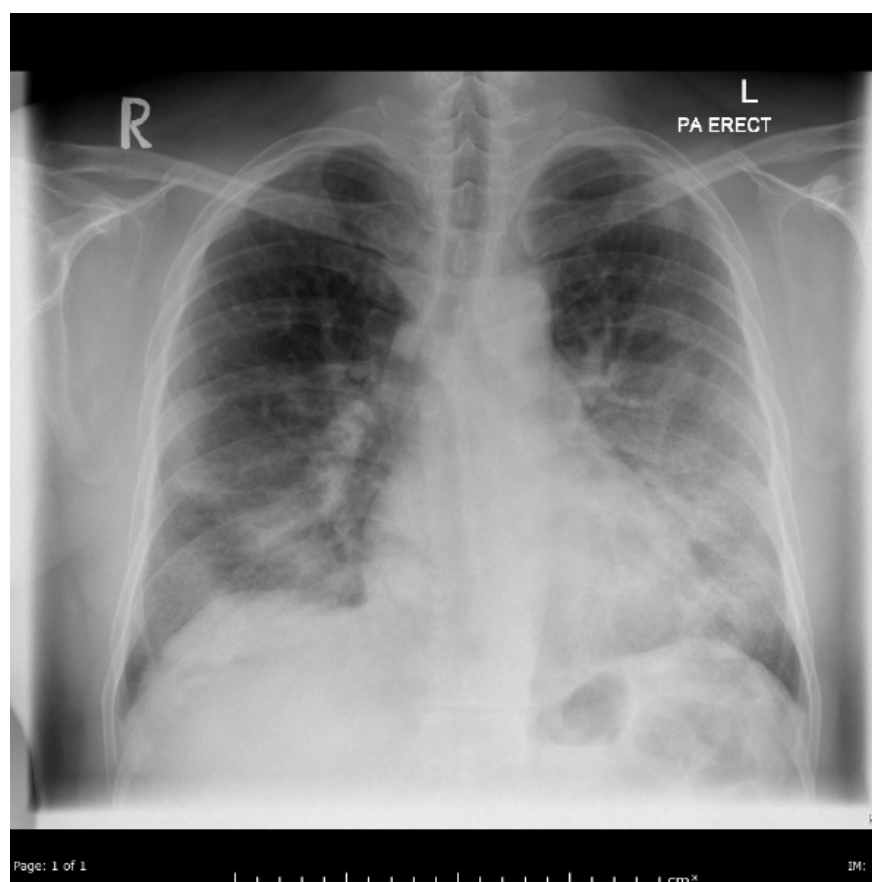

Figure 1:

1. Chest posteroanterior view at presentation showing bilateral mainly mid and lower zonal patchy airspace and ground glass opacities, highly suggestive of COVID pneumonia.
2. Portable antero-posterior view of the chest three weeks after admission showing right sided tension pneumothorax with collapsed right lung and leftward shift of trachea and mediastinum.

3. Portable antero-posterior view of the chest in the same day after insertion of right sided chest tube showing almost complete expansion of the right lung, significant reduction of right sided pneumothorax and minimal surgical emphysema in the right lateral chest wall.
4. Computed Tomography of the chest (CT chest) showing the right sided chest tube in-situ, moderate right sided pneumothorax, mild right sided pleural effusion and persistent bilateral ground glass opacities and pneumonic consolidation due to COVID 19.

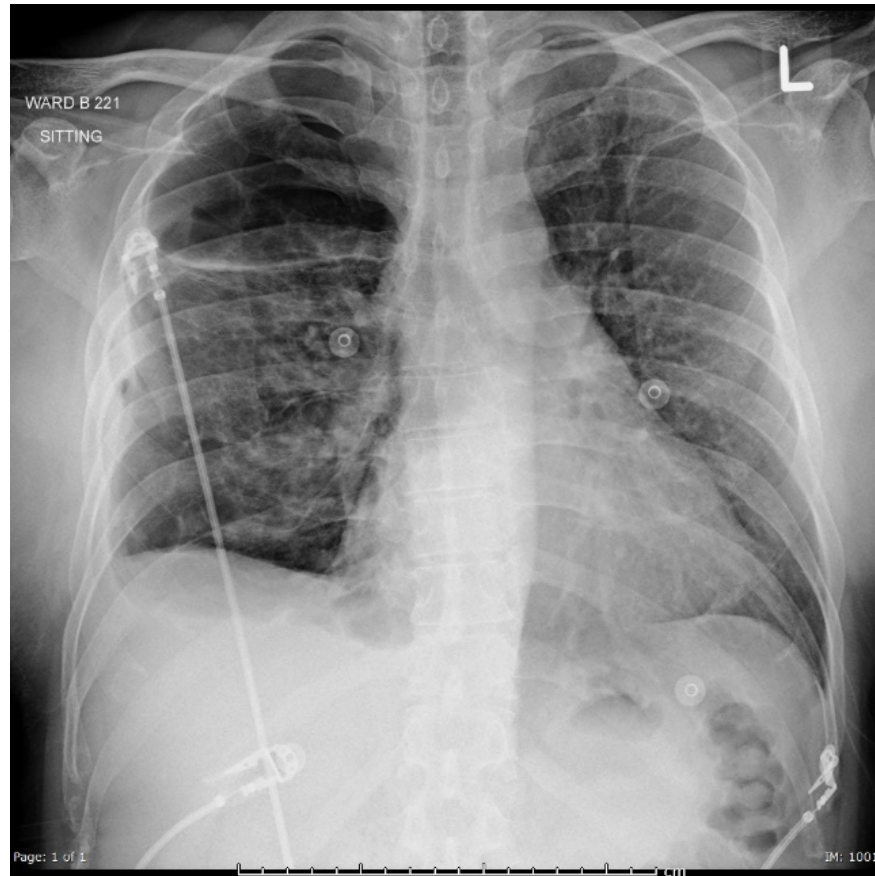


Figure 2: Chest X-ray:

(A) Chest posteroanterior view showing redemonstration of the right sided pneumothorax after incidental removal of chest tube by the patient. (B) Chest posteroanterior view just before discharge showing minimal blunting of right costophrenic angle with no definite pneumothorax.